Technical Note

Arthroscopic Fixation of a Large Osteochondral Fragment From the Glenoid After First Episode Dislocation

Marcio Cohen, M.D., Raphael Fonseca, M.D., Rickson Moraes, M.D., Marcelo Ricardo Pereira, M.D., and Geraldo Motta, M.D.

Abstract: Osteochondral lesions of the glenoid are not so uncommon after traumatic cases of shoulder dislocation and can be a challenge to the shoulder surgeon because of the technical difficulty and the potential to progression to shoulder arthritis. An all-arthroscopic technique of fixation of a large osteochondral fragment is used to allow optimal visualization and reduction, minimize the morbidity of the open approach, and provide good functional results.

A large variety of intra-articular lesions can be found in patients with anterior glenohumeral instability, ranging from isolated labral lesions to extensive humeral or glenoid osteochondral lesions. The most frequent injury after traumatic dislocation involves avulsion of the anterior labrum from the glenoid rim, which results in the classic Bankart lesion. Chondral injuries are historically underdiagnosed, but they appear to be not so uncommon, mainly in traumatic cases.[1,2] Most of them are described as anterior glenolabral articular defect (GLAD lesion), which are small fragments of cartilage disrupted from the edge of the glenoid.[3]

The main problem of chondral lesions is the potential to progress to shoulder arthritis.[4] Many treatment options are described in the literature, including chondral debridement, labral advancement into the defect, microfracture, chondral fixation, and even joint replacement. In younger patients, fixation of the fragment is the main goal to restore the articular surface of the glenohumeral joint.

In this article, we describe an all-arthroscopic technique of fixation of a large glenoid osteochondral lesion. The presented case is an extensive osteochondral fragment sheared after the first episode of a traumatic anterior dislocation of the shoulder in a young athlete (Fig 1). The osteochondral fragment was fixed arthroscopically with 3 cannulated compression screws. One unique characteristic of this lesion was the displacement of the fragment in the axillary recess, rotated on a thin pedicle, which remained attached to the inferior labrum.

Surgical Technique

Patient Positioning

After administration of interscalene nerve block and induction of general anesthesia, the patient is rolled into a lateral decubitus position. Traction is applied in the axial and lateral direction, to keep the arm in 30° of abduction and 20° of anterior flexion, creating distension of the shoulder joint and thus improved intra-articular visualization. Skin landmarks (scapular spine, acromion, clavicle, acromioclavicular joint, and coracoid) are drawn on the patient (Fig 2).

Portal Placement and Diagnostic Arthroscopy

Four portals are used for this arthroscopic procedure: a standard posterior portal, an anterosuperior portal, an anteroinferior portal, and a trans-subscapularis portal.

A standard posterior portal is established 2 cm inferior and medial to the lateral edge of the posterolateral

From the National Institute of Traumatology and Orthopedics (INTO), Rio de Janeiro, Brazil

The authors report that they have no conflicts of interest in the authorship and publication of this article. Full ICMJE author disclosure forms are available for this article online, as supplementary material.

Received November 25, 2019; accepted January 14, 2020.

Address correspondence to Marcio Cohen, National Institute of Traumatology and Orthopedics (INTO), Almirante Guilhem 127, Leblon, Rio de Janeiro, Brazil. E-mail: cohenmarcio@gmail.com

© 2020 by the Arthroscopy Association of North America. Published by Elsevier. This is an open access article under the CC BY-NC-ND license (http://creativecommons.org/licenses/by-nc-nd/4.0/).

2212-6287/191446

https://doi.org/10.1016/j.eats.2020.01.022

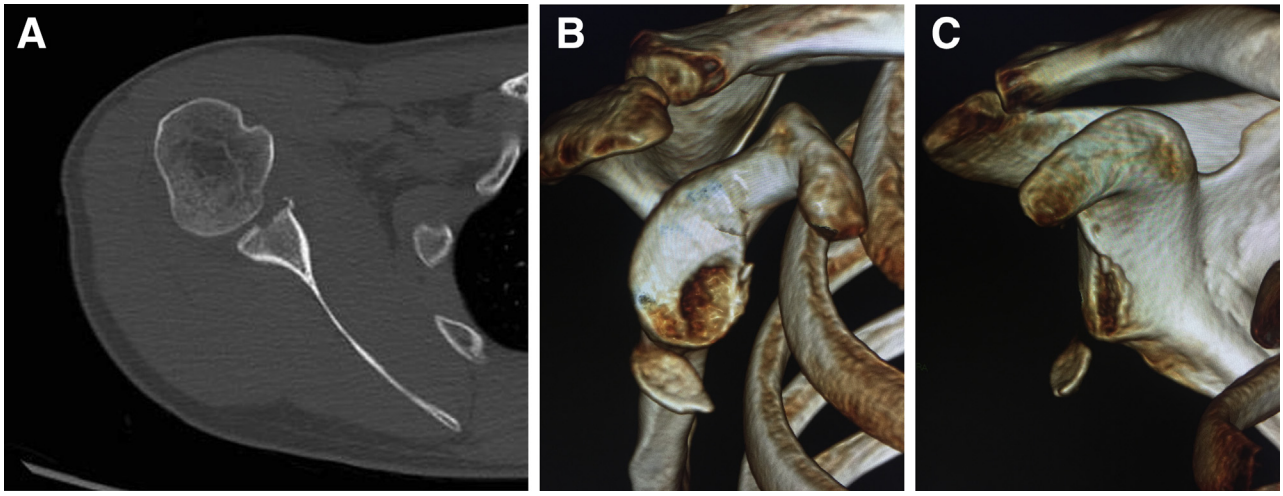

Fig 1. (A) Preoperative axial computed tomography scan of the right shoulder showing a large osteochondral defect involving approximately 50% of the anteroposterior diameter of the glenoid. (B, C) Three-dimensional reconstruction of the glenoid with humeral suppression of the right shoulder, demonstrating the displacement of the osteochondral fragment to the axillary recess.

acromion and a 30° arthroscope is inserted into the glenohumeral joint. An anterosuperior portal is established in the rotator interval immediately inferior to the biceps tendon, and a 7-mm cannula is inserted. A diagnostic arthroscopy is performed to thoroughly inspect the joint and evaluate the status of the labrum and the osteochondral lesion. In this case, an anteroinferior fragment of cartilage with subchondral bone involving approximately 50% of the anteroposterior diameter of the glenoid is completely displaced from its bone bed at the axillary recess and attached to the inferior labrum (Fig 3A and 3B). An arthroscopic shaver is used to debride the fracture bed and to remove the hematoma. The first attempt at reduction of the osteochondral lesion with an arthroscopic suture retriever shows instability of the fragment.

The anteroinferior portal is established by the outside-in technique, immediately superior to the upper border of the subscapularis tendon, to the placement of an 8.25-mm cannula. The arthroscope is switched to the anterosuperior portal to allow for a better understanding of the glenoid. At this view, we can see the intact anterior labrum and the glenoid defect. Looking from the posterior portal, a percutaneous trans-subscapularis

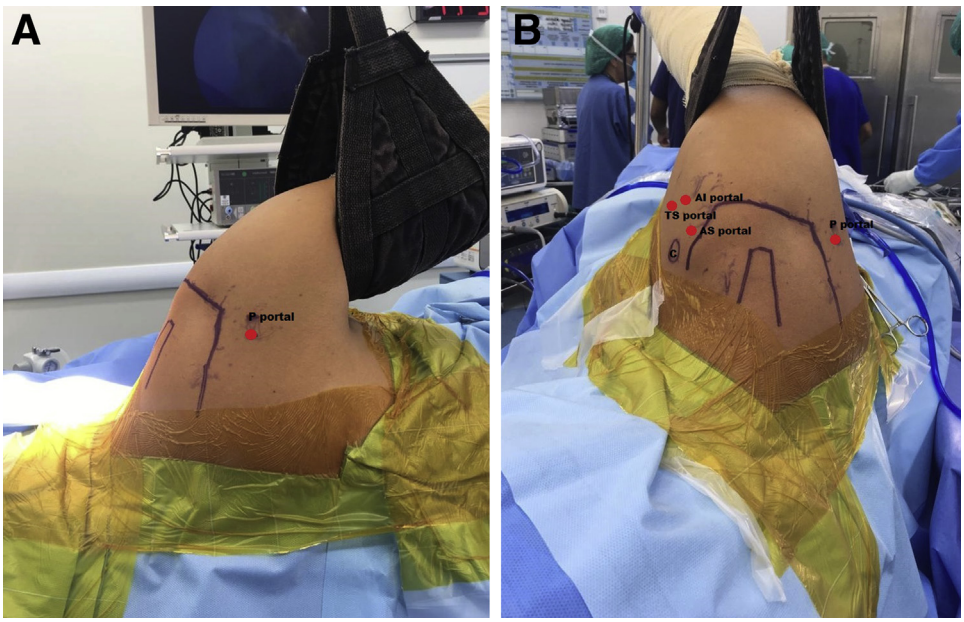

Fig 2. (A, B) Right shoulder in the lateral decubitus position. Skin landmarks (scapular spine, acromion, clavicle, and coracoid [C]) are drawn on the patient. Arthroscopic portals are then located. AI, anteroinferior portal; AS, anterosuperior portal; P, posterior portal; TS, trans-subscapularis portal. The posterior portal is made in the standard position to make it parallel to the glenoid face. Anterosuperior, anteroinferior, and trans-subscapularis portals are created using an outside-in technique with a spinal needle.

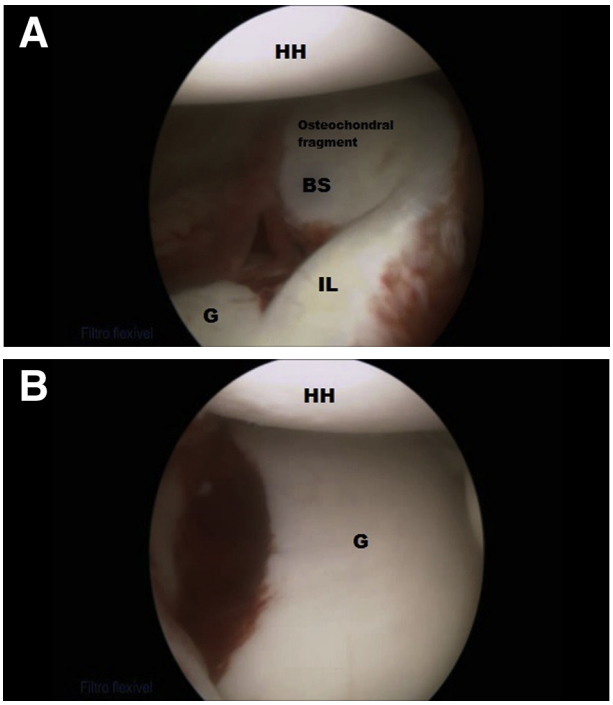

Fig 3. (A) Arthroscopic view of the glenohumeral joint space from the posterior portal with the glenoid (G) visible at de inferior aspect and the humeral head (HH) at the superior aspect. Identification of the fracture with a large osteochondral fragment from the glenoid including the bare spot (BS) area displaced to the axillary recess ant attached to the inferior labrum (IL). (B) Arthroscopic view from the anterosuperior portal for better evaluation of the glenoid fracture.

portal is done because of best angle of approach for fragment manipulation.

Reduction and Fixation of the Osteochondral Lesion

Viewing from the posterior portal, a second attempt at reduction is done with an arthroscopic grasper for temporary fixation with a 1.5-mm K-wire from the drill guide through the trans-subscapularis portal. Because of the presence of 2 mm of subchondral bone, the wire is used as a joystick for reduction and temporary fixation (Fig 4A).

Viewing from the anterosuperior portal, it is possible to see the reduction. A 2-mm displacement is accepted to avoid the risk of osteochondral fragmentation resulting from excessive manipulation. A cannulated screw guidewire is introduced from the anteroinferior portal. A cannulated compression screw (SpeedTip CCS 2.2, Medartis) is inserted without predrilling (Fig 4B). This step is repeated 2 times to have a 3-point fixation of the fragment, achieving better stability. The screws are progressed until no protrusion of their tips was observed or probed. The K-wire is then removed and a new joint inspection is made. A satisfactory reduction, almost anatomic, is obtained with a stable fixation and no prominent screws over the cartilage surface (Fig 4C).

Postoperative Rehabilitation

The shoulder is immobilized in internal rotation with a regular sling for 4 weeks. Our preference is to begin passive range-of-motion exercises at 2 weeks after surgery and allow for forward flexion to 90° and external rotation to 30°. Active range-of-motion exercises are initiated 6 weeks after surgery. Full return to activities is generally allowed by 6 months after surgery (Table 1). Radiographs and computed tomography scans show optimal screw positioning (Fig 5 and Fig 6).

Discussion

This Technical Note describes an all-arthroscopic fixation method of an osteochondral shear lesion at the anteroinferior quadrant of the glenoid. The main

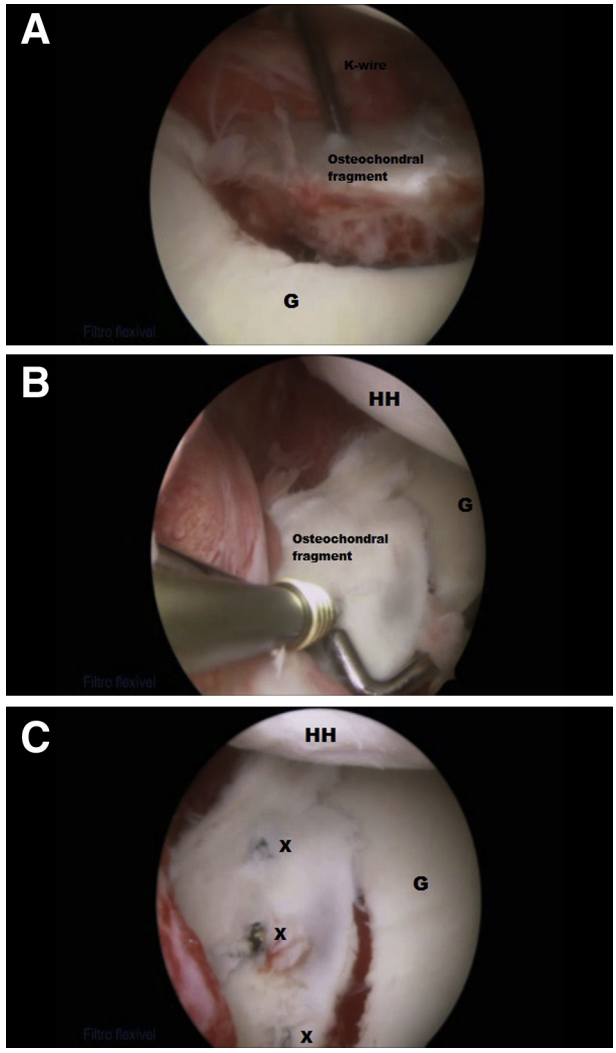

Fig 4. (A) Viewing from the posterior portal, joystick and temporary fixation of the glenoid osteochondral fragment is done with a 1.5-mm K-wire through trans-subscapularis portal. (B) Viewing from the anterosuperior portal, a cannulated compression screw is inserted through the anteroinferior portal. (C) We can see almost anatomic reduction without any prominence of the 3 screws (x).

Table 1. Keys to Success

Preoperative planning	• Plain radiography and CT scan of the shoulder • Hardware (K-wires, guidewire, and cannulated compression screws)
Setup	• Semilateral decubitus • Develop portals (standard posterior portal, anterosuperior portal, anteroinferior portal and trans-subscapularis portal)
Intraoperative	• Diagnostic arthroscopy with thorough inspection of the joint • Address concomitant lesions • Identification, debridement, and mobilization of the fragment • Anatomic reduction and temporary fixation (1.5-mm K-wire) • Guidewire and screw insertion (3×) • Check reduction and stability of fixation
Postoperative	• Patient compliance • Rehabilitation protocol dictated by fracture pattern and associated injuries • High-quality physical therapy • Annual radiographic assessment is advisable

CT, computed tomography.

advantage of our technique is that it allows for complete arthroscopic management of larger glenohumeral chondral fragments. Furthermore, arthroscopy allows us to evaluate the entire articulation and the presence of associated lesions (Table 2).

The incidence of chondral lesions at the glenoid is reported to be 36% in glenohumeral instability, and up to 46% when associated with labral lesions.[5] Some authors described common patterns of lesion, including GLAD, glenoid articular rim divot, glenoid labral tear and articular flap and, recently, glenoid labral articular teardrop.[3,4,6-9] Patzer et al. have described the association between SLAP and chondral lesion, mostly in the anterior half of the glenoid (63%).[10] The importance of identifying these lesions is because of the potential for progression to glenohumeral arthritis, although there is still controversy about the best treatment option.[4]

In this report, there was no evidence of a SLAP lesion during the procedure. The chondral lesion was restricted to the anteroinferior quadrant of the glenoid. Fragment excision and microfracture were not feasible because of the size of the lesion. Similarly, fixation of the lesion with anchors or other available devices would not allow for a stable fixation of the fragment.

Galano et al. described 2 cases of GLAD lesion variants.[6] The first was treated with excision of the chondral fragment associated with microfractures and traditional Bankart lesion repair. In the second case, the fragment was bigger and the author opted for the stabilization with a cartilage fixation device. Both were associated with SLAP lesions, which were repaired with suture anchors.

Page et al. described a full-thickness chondrolabral lesion at the anteroinferior quadrant of the glenoid, with extension up to the bare spot, measuring 15 × 18 mm.[7] The author used a meniscal repair device to improve stability at the chondral flap after the labral fixation with suture anchors.

In our limited experience, with the described technique, it is possible to repair large glenoid osteochondral lesions with an all-arthroscopic technique, avoiding the morbidity of an open procedure. However, the technique presents risks, like a screw head protrusion and early evolution to shoulder arthritis (Table 3). Postoperative computed tomography scans have allowed us to confirm the healing of the fragment. Annual physical examination and radiographic

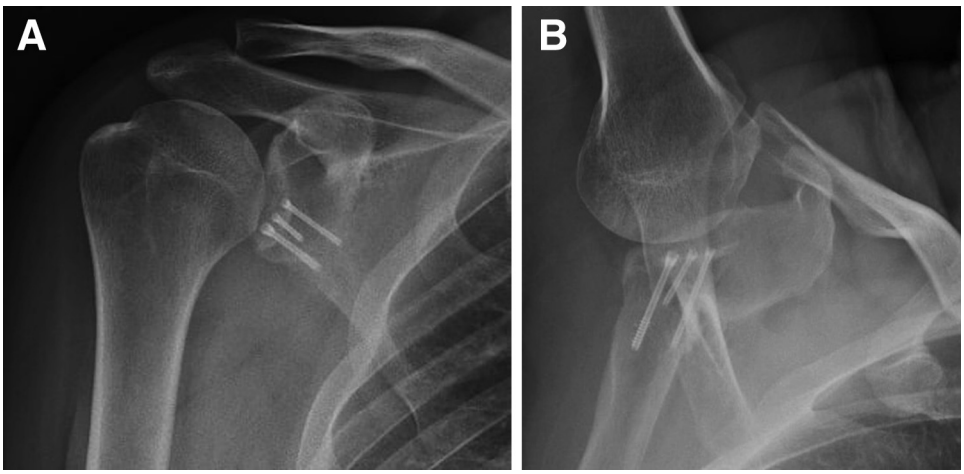

Fig 5. (A, B) Postoperative radiographic views showing optimal positioning of the 3 cannulated compression screws.

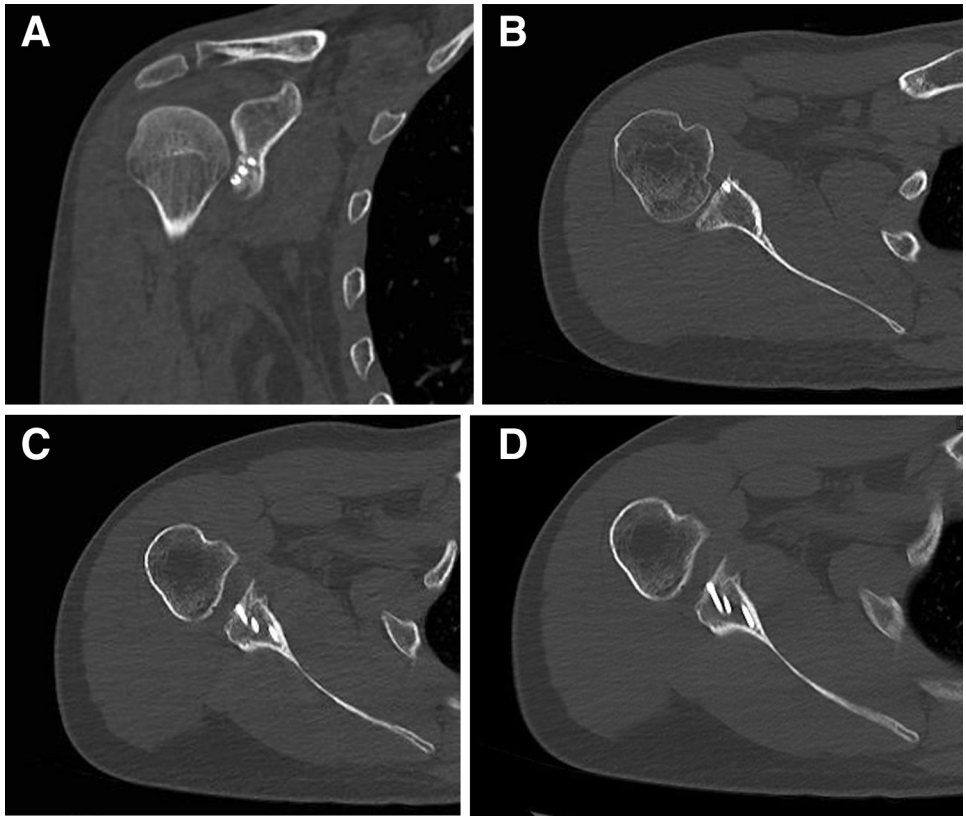

Fig 6. Postoperative (A) coronal and (B–D) axial computed tomography scan showing alignment and integration of the osteochondral fragment, with no protrusion of the screw head to the articular surface and no evidence of osteoarthritis.

Table 2. Advantages and Disadvantages of Arthroscopic Fixation of Osteochondral Fracture of the Glenoid

Advantages	• Excellent fracture and reduction visualization • Soft-tissue preservation • Minimal disturbance to vascular supply • Provides stable fixation • Decrease postoperative stiffness/weakness
Disadvantages	• Technical difficulty • No visualization of neurovascular structures • Limited screws angulation • Not well suited for small/comminuted osteochondral fragments

Table 3. Risks of Arthroscopic Fixation of Osteochondral Fracture of the Glenoid

Risks	• Fragmentation of the osteochondral lesion during mobilization • K-wire/drill breakage • Protrusion of the screw head because of insufficient insertion • Resorption of the fragment with intra-articular protrusion of the screw head

assessment are advisable because of the risk of screw head protrusion, which would require screw removal.

References

1. Paley KJ, Jobe FW, Pink MM. Arthroscopic findings in the overhand throwing athlete: evidence for posterior internal impingement of the rotator cuff. *Arthroscopy* 2000;16:35-40.
2. Zhu W, Lu W, Zhang L, et al. Arthroscopic findings in the recurrent anterior instability of the shoulder. *Eur J Orthop Surg Traumatol* 2014;24:699-705.
3. Neviaser TJ. The GLAD lesion: another cause of anterior shoulder pain. *Arthroscopy* 1993;9:22-23.
4. Lederman ES, Flores S, Stevens C, Richardson D, Lund P. The glenoid labral articular teardrop lesion: a chondrolabral injury with distinct magnetic resonance imaging findings. *Arthroscopy* 2018;34:407-411.
5. O'Brien J, Grebenyuk J, Leith J, Forster BB. Frequency of glenoid chondral lesions on MR arthrography in patients with anterior shoulder instability. *Eur J Radiol* 2012;81:3461-3465.
6. Galano GJ, Weisenthal BM, Altchek DW. Articular shear of the anterior-inferior quadrant of the glenoid: a glenolabral articular disruption lesion variant. *Am J Orthop (Belle Mead, NJ)* 2013;42:41-43.
7. Page R, Bhatia DN. Arthroscopic repair of a chondrolabral lesion associated with anterior glenohumeral dislocation. *Knee Surg Sports Traumatol Arthrosc* 2010;18:1748-1751.
8. Sanders TG, Tirman PF, Linares R, Feller JF, Richardson R. The glenolabral articular disruption lesion: MR arthrography with arthroscopic correlation. *AJR Am J Roentgenol* 1999;172:171-175.
9. Amrami KK, Sperling JW, Bartholmai BJ, Sundaram M. Radiologic case study. Glenolabral articular disruption (GLAD) lesion. *Orthopedic* 2002;25:95-96.
10. Patzer T, Lichtenberg S, Kircher J, Magosch P, Habermeyer P. Influence of SLAP lesions on chondral lesions of the glenohumeral joint. *Knee Surg Sports Traumatol Arthrosc* 2010;18:982-987.