REV BRAS ORTOP. 2014;49(4):364–369

RBO REVISTA BRASILEIRA DE ORTOPEDIA

www.rbo.org.br

Original Article

Evaluation of the fixation of the trabecular metal wedge in patients undergoing revision of total hip arthroplasty☆,☆☆

Victor Magalhães Callado, Osamu de Sandes Kimura, Diogo de Carvalho Leal, Pedro Guilme Teixeira de Sousa Filho, Marco Bernardo Cury Fernandes, Emílio Henrique Carvalho de Almendra Freitas*

Instituto Nacional de Traumatologia e Ortopedia (Into), Rio de Janeiro, RJ, Brazil

ARTICLE INFO

Article history:
Received 22 July 2013
Accepted 30 July 2013
Available online 3 May 2014

Keywords:
Hip arthroplasty
Trabecular metal augment
Prostheses and implants
Acetabular bone defects

ABSTRACT

Objective: this study aimed to evaluate the fixation of the trabecular metal wedge in patients undergoing revision of total hip arthroplasty.
Methods: twenty-three cases with minimum grading of Paprosky II-B that were operated between July 2008 and February 2013 were evaluated. These cases were evaluated based on radiographs before the operation, immediately after the operation and later on after the operation. Loss of fixation was defined as a change in the abduction angle of the component greater than 10° or any mobilization greater than 6 mm.
Results: it was found that there was 100% fixation of the acetabula after a mean of 29.5 months. One case underwent removal of the implanted components due to infection.
Conclusions: there is still no consensus regarding the best option for reconstructing hips with bone loss. However, revision using a trabecular metal wedge has presented excellent short- and medium-term results. This qualifies it as an important tool for achieving a fixed and stable acetabular component.

© 2014 Sociedade Brasileira de Ortopedia e Traumatologia. Published by Elsevier Editora Ltda. Este é um artigo Open Access sob a licença de CC BY-NC-ND

Avaliação da fixação da cunha de metal trabeculado em pacientes submetidos à revisão de artroplastia total de quadril

Palavras-chave:
Artroplastia de quadril
Cunha de metal trabeculado
Próteses e implantes
Defeitos ósseos acetabulares

RESUMO

Objetivo: avaliar a fixação das cunhas de metral trabeculado (CMT) em pacientes submetidos à revisão de artroplastia total de quadril.
Métodos: foram avaliados 23 casos graduados no mínimo como II-B de Paprosky, operados entre julho de 2008 e fevereiro de 2013. Os casos foram avaliados com base nas radiografias pré e pós-operatórias imediatas e tardias. A perda da fixação foi definida como uma variação

☆ Please cite this article as: Callado VM, de Sandes Kimura O, de Carvalho Leal D, Teixeira de Sousa Filho PG, Cury Fernandes MB, Carvalho de Almendra Freitas EH. Avaliação da fixação da cunha de metal trabeculado em pacientes submetidos à revisão de artroplastia total de quadril. Rev Bras Ortop. 2014;49:364–369.

☆☆ Work performed in the Department of Orthopedics and Traumatology, Instituto Nacional de Traumatologia e Ortopedia (INTO), Rio de Janeiro, RJ, Brazil.

* *Corresponding author.*
E-mail: victorcallado@uol.com.br (V.M. Callado).

2255-4971 © 2014 Sociedade Brasileira de Ortopedia e Traumatologia. Published by Elsevier Editora Ltda.
Este é um artigo Open Access sob a licença de CC BY-NC-ND http://dx.doi.org/10.1016/j.rboe.2014.04.015

do ângulo de abdução do componente maior do que 10° ou qualquer mobilização maior do que 6 mm.
Resultados: verificou-se 100% de fixação dos acetábulos após 29,5 meses em média. Um caso foi submetido à retirada dos componentes implantados por infecção.
Conclusões: ainda não há consenso no que diz respeito à melhor opção de reconstrução do quadril com perda óssea, porém a revisão com CMT vem apresentando excelentes resultados em curto e médio prazo. Tal fato a qualifica como uma importante ferramenta na obtenção de um componente acetabular fixo e estável.
© 2014 Sociedade Brasileira de Ortopedia e Traumatologia. Publicado por Elsevier Editora Ltda. Este é um artigo Open Access sob a licença de CC BY-NC-ND

Introduction

Year by year, the total number of hip arthroplasty procedures in Brazil and worldwide is growing. This is related to the good clinical results obtained through this procedure, which involves pain relief and a substantial improvement in joint function.[1]

With improvements in the techniques, materials and prostheses, the results obtained have become ever better, both in quality and in longevity. However, some patients will need to undergo revision surgery due to aseptic loosening, instability, infection or osteolysis.[2] Osteolysis is responsible for originating acetabular defects that make it difficult to achieve prosthesis stability during revision surgery. This is the main challenge in this surgery.

Classification of acetabular defects is an important step in preoperative and intraoperative planning. Paprosky et al.[3] proposed three main groups based on osteolysis of the ischium (posterior spine) and the teardrop (medial wall) and the degree of upward migration of the acetabulum (acetabular ceiling).

Several reconstruction strategies have been put forward for treating acetabular defects: an implant to keep the center of rotation above the anatomical position[4]; a "jumbo cup" component (prostheses larger than 65 mm for both genders or larger than 66 mm for men and 62 mm for women)[5]; an oblong prosthesis; a hemispherical prosthesis in association with a homologous structural or crushed graft; anti-protrusion rings; and a prosthesis used in association with trabecular metal wedges (Fig. 1).[4–7]

Placement of the prosthesis above the original center of rotation may cause alterations to gait biomechanics.[8] Homologous structural grafts present the potential for disease transmission, require tissue bank infrastructure and present preparation difficulty and the possibility of reabsorption. Oblong components do not always adapt to the defect. Use of a screen in association with a diced graft is an option for young patients for whom it is desirable to improve the bone stock, but this method presents the same problems as mentioned above in relation to structural grafts.[9]

The traditional porous implants made of titanium have become well established in long-term studies on acetabular revisions, but a significant increase in the failure rate after the first decade *in vivo* has been observed.[10] In this context, the search for long-lasting biological fixation has stimulated the use of trabecular metal implants. These implants, which are made of the metal tantalum in a carbon skeleton of uniform porosity, *i.e.* a structure with physical and mechanical properties similar to those of bone, are characterized by high porosity of around 75–80% by volume, in comparison with 30–50% for porous titanium implants. This architecture provides differences in the biomechanical profile of the material, and offers a larger area for growth of native bone. This therefore contributes toward increasing the resistance to shearing at the prosthesis-bone interface (high coefficient of friction). These implants have a coefficient of elasticity close to that of bone and lower than that of traditional implants. The greater stability has been attributed to the relative elasticity and the high coefficient of friction.[11] Studies on histological sections from the metal-bone interface have also found that there is a higher rate of invasive bone growth in the pores of the trabecular metal than in traditional porous implants (Fig. 2).[12] In addition to the mechanical advantage, these implants also present the possibility of adaptation of their size to the bone defects that are found, and do not present any risk of reabsorption.

Objective

The aim of this study was to assess the fixation of trabecular metal wedges in patients who underwent aseptic revision of total hip arthroplasty.

Fig. 1 – Trabecular metal wedge positioned in acetabular defect.[9]

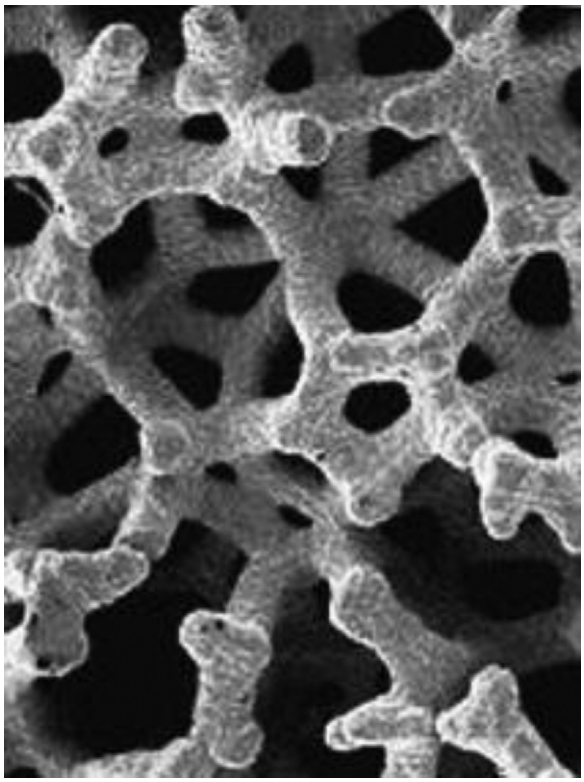

Fig. 2 – Electronic photomicrograph showing the highly porous structure made of tantalum (www.zimmer.com).

Material and methods

The sample was formed by patients who underwent hip revision arthroplasty due to aseptic failure, between July 2008 and February 2013. During this period, 425 hip revision arthroplasty procedures were performed using trabecular metal for the acetabular component. Of these, 23 patients received a trabecular metal wedge.

Trabecular metal wedges are available in different shapes and sizes. They can be divided into three major groups: conventional semicircular type; spinal or seven-shape supports; and chock-shape type.[13] In our study, we only used conventional semicircular wedges (Fig. 3A–C).

The patients' mean age was 58 years (range: 39–81 years); 12 were male (52.2%) and 11 were female (47.8%). The modified Kocher-Langenbeck posterolateral access was used in all the procedures.

We used the following parameters for indicating the use of a trabecular metal wedge, intraoperatively: lack of coverage of the acetabular component greater than 40%[14] or situations in which stable fixation of the acetabular component was not achieved without placement of a wedge.

The evaluation consisted of analyzing anteroposterior radiographs of the pelvis and lateral radiographs of the operated hip. The degree of osseointegration of the acetabular dome was ascertained using the classification of Moore et al.[15] Five radiographic parameters were used: absence of radiolucency lines; presence of superolateral support; medial stress-shielding; radial trabeculae and inferomedial support.



Fig. 3 – Types of wedge available.[15] (A) Semicircular; (B) spinal or seven-shaped support; (C) chock-shaped.

Presence of three or more signs had a positive predictive value of 96.9%, sensitivity of 89.9% and specificity of 76.9% for osseointegration. These parameters could not be extrapolated to osseointegration of the wedge, as described by Abolghasemian et al.[13]

Loss of fixation of the trabecular metal wedge was defined radiologically as a change in the abduction angle of the component that was greater than 10°, or any mobilization in a vertical or horizontal direction that was greater than 6 mm.[13]

Table 1 – Case distribution in accordance with Paprosky et al.[3]

	I	II-A	II-B	II-C	III-A	III-B
No. of cases	–	–	5	1	10	7
%	–	–	21.7	4.3	43.5	30.5

We compared the position of the center of hip rotation from before to after the operation and measured this in relation to the contralateral hip.

The postoperative rehabilitation consisted of partial weight-bearing with the aid of crutches for eight to twelve weeks. Consultations were provided after two weeks, one month, three months, six months and yearly thereafter. All the patients received drug prophylaxis for deep vein thrombosis using low molecular weight heparin for 30 days.

Statistical analysis was performed using the Microsoft Office Excel 2010 software. The data were analyzed using Student's *t* test and findings with a *p*-value <0.05 were taken to be significant. Kaplan–Meier survival analysis was performed with a 95% confidence interval in order to investigate the survival of the implant, using the cutoff point of the need for another revision and failure according to radiographic criteria.

Results

The acetabular defects were classified in accordance with Paprosky et al.,[3] as indicated in Table 1.

The mean size of the acetabular domes was 56 mm (range: 48–68 mm). The total number of trabecular metal wedges used was 23 (all of them of the conventional type), ranging in thickness from 10 to 30 mm and in diameter from 48 to 62 mm. None of the patients needed more than one wedge. The mean number of screws used in each wedge was 1.7 (range: 1–2). All the inserts used were made of polyethylene and no constricting liners were used. The number of liners used depended on the diameter of the head: thus, five liners were used for head 28 and 18 for head 32.

The radiographic analysis did not show any signs of aseptic loosening in any of the cases. There was one case of infection, but without clinical or radiographic signs of septic loosening. Culturing performed during the operation was negative and the ultrasensitive C-reactive protein (CRP) value before the operation was 0.6 (normal <5.0). Three months after the operation, this case presented clinical and laboratory signs of infection, and the implant was removed. At the time of removing the implants, the wedge was seen to be fixed. Currently, this patient still does not have a hip prosthesis, but also does not have any signs of active infection.

The mean number of surgical procedures performed before placement of the wedges was 1.5 (range: 1–4). The time that had elapsed from the last surgery until placement of the wedge was 15.5 years (range: 1–31). The mean preoperative CRP value was 3.64 (range: 0.32–5.0).

The survival rate found using Kaplan–Meier survival analysis was 90.9% after 28 months. The component fixation rate was 100% after a mean follow-up of 29.5 months, since none of the cases presented any clinical or radiographic signs of loosening. All the acetabular domes presented three or more signs of fixation, in accordance with the criteria of Moore et al.[15]

We used the score of D'Aubigné and Postel[16] to make clinical comparisons between the results. The mean preoperative score was 6.65 points (range: 4–10) and this increased after the operation to 15.96 points (range: 13–18). This difference was statistically significant, according to Student's *t* test ($p < 0.0001$).

The capacity for restoration of the normal center of rotation in the revised hip was measured. Five hips were removed from this analysis of the data because the contralateral hip had previously undergone arthroplasty. Before the operation, the center of rotation was found to be high (>35 mm) in 10 of the 18 hips (55.5%), with a mean distance of 32 mm (range: 5–56 mm) above the center of rotation of the contralateral side. After the operation, the mean decreased to 14 mm (range: 0–31 mm), which was a statistically significant difference ($p = 0.0001$), and none of the hips continued to present a high center of rotation. There was a mean improvement in the location of the center of rotation of 17 mm (range: 0–54 mm).

Discussion

Revision of the acetabular component is a complex and laborious stage in hip arthroplasty revision. Several factors contribute toward this difficulty, such as bone defects, which are often underestimated before the operation, and the modified surgical anatomy of the hip.[17]

Type I and II defects present good long-term results when treated using non-structural grafts.[18] On the other hand, type III lesions, which are characterized by significant bone loss, require reconstruction that will provide greater stability for the implant. For this, structural grafts, reinforcement rings, oblong prostheses or trabecular metal wedges can be used.[19]

Reconstruction using a structural graft together with a cemented acetabular component has shown poor clinical results.[20] Anti-protrusion rings present high complication rates because of the complexity of the reconstruction, biomechanical stability and material used.[9] Weeden and Schmidt[21] reported that they obtained satisfactory results in smaller defects, but that as the defects became more severe, the traditional implants tended to fail. For type IIIA defects, Del Gaizo et al.[22] recommended that allogeneic structural grafts should only be used for very young patients, who would require new revisions in order to improve the bone stock.

Trabecular metal wedges have been presenting encouraging results, according to the latest published data. In 23 hips with type 111A and IIIB defects, Lingaraj et al.[23] observed that 95.6% of the implants remained fixed after 41 months. In 43 patients with type 111A and IIIB defects, Weeden and Schmidt[21] found a 98% success rate over a period of 2.8 years. In 23 hips followed up for 35 months, Flecher et al.[24] did not observe any loss of fixation of the acetabular components. In 37 cases of type IIIA defects, Del Gaizo et al.[22] reported survival of 97.3% over a 60-month period. Borland et al.[25] reported a wedge incorporation rate of 100% among 24 cases over a five-year period. Among 38 patients with type IIIA and IIIB defects who were followed up for 25 months, Hasart et al.[26] reported

that two cases required revision due to loosening or migration. In 34 patients with defects ranging from type IIA to type IIIB who were followed up for 24 months, Siegmeth et al.[27] reported survival of 94.11%. Sporer and Paprosky[28] published a series of 28 patients with type IIIA defects and follow-up of 37 months, who presented survival of 96.5%.

An increase in the score of D'Aubigné and Postel[16] has also been reported by other authors. Among 24 cases in which trabecular metal wedges were used in association with cemented acetabula, which were followed up for five years, Borland et al.[25] reported that there were improvements in the WOMAC and SF-36 functional scores ($p < 0.005$). In 37 patients, Del Gaizo et al.[22] reported that there was an improvement in the Harris Hip Score from 33.0 to 81.5 points. Among 38 patients with type IIIA and IIIB defects who were followed up for 25 months, Hasart et al.[26] observed that the Merle d'Aubigné functional score increased from 6 to 13 points and the Harris Hip Score from 29 to 79 points.

We showed a vertical improvement in the center of rotation from 32 mm to 14.6 mm. Before the operation, 72.2% of the hips presented a center with a difference greater than 20 mm, while this was seen in only 33.3% after the operation. Biomechanical studies[8] have shown that an upward displacement of the center of rotation by not more than 20 mm did not affect the gait or abductor musculature. Abolghasemian et al.[13] reported that there was an improvement in the location of the center of rotation in 79.4% of the hips. Their mean correction was 9.9 mm. In our study, the mean correction was 17 mm. Hasart et al.[26] reported that there was an improvement in the center of rotation of the hip from 35 mm (range: 16–55 mm) to 14 mm (range: 5–27). Siegmeth et al.[27] reported that there was an improvement in the center of rotation from 50 mm to 28 mm. Only three of their 33 patients continued to present a high center of rotation after the operation, whereas 30 had shown this before the revision surgery. In our sample, none of our patients persisted with a high hip center.

The complication rate in our study was 4.1% (one case of infection). Del Gaizo et al.[22] reported a complication rate of 21.6%, which was in line with other long-term studies on outcomes from complex revisions of total hip arthroplasty. Among 97 revision surgery procedures, Van Kleunen et al.[17] reported an infection rate of 8.2%.

Trabecular metal wedges have the advantage of being a modular system that is technically simpler, quickly implemented and without any potential for reabsorption. It also avoids the morbidity caused by graft removal for reconstruction. The microporosity of the material favors biological fixation of the implant and feeds the expectation of achieving long-lasting stability.[29]

Among the disadvantages observed, we can cite the potential for generating debris at the wedge/cement/acetabulum interface, high cost, incapacity to restore the bone stock for future revisions and lack of long-term data.[19]

Conclusion

Trabecular metal wedges have been shown to be a promising option for managing severe acetabular defects. They present long survival over the short to medium term, but long-term follow-up is needed in order to be able to define the true role of this technology in relation to the traditional options for reconstruction.

Conflicts of interest

The authors declare no conflicts of interest.

REFERENCES

1. Visuri T, Koskenvuo M, Honkanen R. The influence of total hip replacement on hip pain and the use of analgesics. Pain. 1985;23(1):19–26.
2. Sullivan PM, MacKenzie JR, Callaghan JJ, Johnston RC. Total hip arthroplasty with cement in patients who are less than fifty years old. A sixteen to twenty-two-year follow-up study. J Bone Joint Surg Am. 1994;76(6):863–9.
3. Paprosky W, Perona P, Lawrence J. Acetabular defect classification and surgical reconstruction in revision arthroplasty. A 6-year follow-up evaluation. J Arthroplasty. 1994;9(1):33–44.
4. Harris WH. Reconstruction at a high hip center in acetabular revision surgery using a cementless acetabular component. Orthopedics. 1998;21(9):991–2.
5. Whaley AL, Berry DJ, Harmsen WS. Extra-large uncemented hemispherical acetabular components for revision total hip arthroplasty. J Bone Joint Surg Am. 2001;83(9):1352–7.
6. Patel JV, Masonis JL, Bourne RB, Rorabeck CH. The fate of cementless jumbo cups in revision hip arthroplasty. J Arthroplasty. 2003;18(2):129–33.
7. Sporer SM, O'Rourke M, Paprosky WG. Managing bone loss in acetabular revision. Instr Course Lect. 2006;55:287–97.
8. Delp SL, Wixson RL, Komattu AV, Kocmond JH. How superior placement of the joint center in hip arthroplasty affects the abductor muscles. Clin Orthop Relat Res. 1996;(328): 137–46.
9. Garbuz D, Morsi E, Gross AE. Revision of the acetabular component of a total hip arthroplasty with a massive structural allograft: study with a minimum five-year followup. J Bone Joint Surg Am. 1996;78(5):693–7.
10. Lewallen DG. Acetabular revision: technique and results. In: Morrey BF, editor. Joint replacement arthroplasty. 3rd ed Philadelphia: Churchill Livingstone; 2003. p. 824.
11. Meneghini MR. Mechanical stability of novel highly porous metal acetabular components in revision total hip arthroplasty. J Arthroplasty. 2010;25(3):337–41.
12. Bobyn JD, Stackpool GJ, Hacking SA, Tanzer M, Krygier JJ. Characteristics of bone ingrowth and interface mechanics of a new porous tantalum biomaterial. J Bone Joint Surg Br. 1999;81(5):907–14.
13. Abolghasemian M, Tangsataporn S, Sternheim A, Backstein D, Safir O, Gross AE. Combined trabecular metal acetabular shell and augment for acetabular revision with substantial bone loss: a mid-term review. Bone Joint J. 2013;95-B(2):166–72.
14. Jasty M. Jumbo cups and morsalized graft. Orthop Clin North Am. 1998;29(2):249–54.
15. Moore MS, McAuley JP, Young AM, Engh Sr CA. Radiographic signs of osseointegration in porous-coated acetabular components. Clin Orthop Relat Res. 2006;(444):176–83.
16. D'Aubigné RM, Postel M. Functional results of hip arthroplasty with acrylic prosthesis. J Bone Joint Surg Am. 1954;36(3):451–75.

17. Van Kleunen JP, Lee GC, Lementowski PW, Nelson CL, Garino JP. Acetabular revisions using trabecular metal cups and augments. J Arthroplasty. 2009;24 Suppl. 6:64–8.
18. Rondinelli PC, Cabral FP, Freitas EH, Penedo JL, da Silveira SLC, Medina BT. Cirurgia de revisão na artroplastia de revisão do quadril com enxerto de banco de ossos. Rev Bras Ortop. 1993;28(6):343–52.
19. Harkess JW. Artroplastia de quadril. In: Canale ST, editor. Cirurgia ortopédica de Campbell. 2003. p. 315–471.
20. Sporer SM, O'Rourke M, Chong P, Paprosky WG. The use of structural distal femoral allografts for acetabular reconstruction: surgical technique. J Bone Joint Surg Am. 2006;88(Suppl 1):92–9.
21. Weeden S, Schmidt R. The use of trabecular metal implants for Paprosky 3A and 3B defects. J Arthroplasty. 2007;22 6 (Suppl. 2):151–5.
22. Del Gaizo DJ, Kancherla V, Sporer SM, Paprosky WG. Tantalum augments for IIIA acetabular defects. Clin Orthop Relat Res. 2012;(470):395–401.
23. Lingaraj K, Teo YH, Bergman N. The management of severe acetabular bone defects in revision hip arthroplasty using modular porous metal components. J Bone Joint Surg Br. 2009;91(12):1555–60.
24. Flecher X, Sporer S, Paprosky W. Management of severe bone loss in acetabular revision using a trabecular metal shell. J Arthroplasty. 2008;23(7):949–55.
25. Borland WS, Bhattacharya R, Holland JP, Brewster NT. Use of porous trabecular metal augments with impaction bone grafting in management of acetabular bone loss. Acta Orthop. 2012;83(4):347–52.
26. Hasart O, Perka C, Lehnigk R, Tohtz S. Reconstruction of large acetabular defects using trabecular metal augments. Oper Orthop Traumatol. 2010;22(3):268–77.
27. Siegmeth A, Duncan CP, Masri BA, Kim WY, Garbuz DS. Modular tantalum augments for acetabular defects in revision hip arthroplasty. Clin Orthop Relat Res. 2009;467(1): 199–205.
28. Sporer SM, Paprosky WG. The use of a trabecular metal acetabular component and trabecular metal augment for severe acetabular defects. J Arthroplasty. 2006;21 6 (Suppl. 2):83–6.
29. Nehme A, Lewallen DG, Hanssen AD. Modular porous metal augments for treatment of severe acetabular bone loss during revision hip arthroplasty. Clin Orthop Relat Res. 2004;(429):201–8.