Technical Note

Continuous Meniscal Suture in Radial Meniscal Tear: The Hourglass Technique

José Leonardo Rocha de Faria, M.D., M.Sc., Douglas Mello Pavão, M.D., M.Sc., Rodrigo Sattamini Pires e Albuquerque, M.D., M.Sc., Ph.D., Eduardo Branco de Sousa, M.D., M.Sc., Ph.D., João Antônio Matheus Guimarães, M.D., M.Sc., Ph.D., Alan de Paula Mozella, M.D., M.Sc., Carlos Rodrigo de Mello Roesler, Ph.D., Rodrigo Salim, M.D., M.Sc., Ph.D., Marcelo Mandarino, M.D., M.Sc., and Robert F. LaPrade, M.D., Ph.D.

Abstract: The key to preventing early knee osteoarthritis is meniscal preservation. The main functions of the meniscus are impact absorption, mechanical load transmission, lubrication, joint stability, and proprioception. Radial lesions that extend to the joint capsule are called complete radial tears. This type of injury compromises 2 of the main meniscal functions, which are impact absorption and load distribution, which is equivalent, from a biomechanical perspective, to a total meniscectomy. In the recent past, the treatment of choice for this type of injury was partial meniscectomy. However, several studies have observed progressive joint degeneration after this type of treatment. Recently, different types of meniscal sutures involving radial lesions of the meniscus have been developed. It is believed that such repairs may bring a decrease in future osteoarthritis in this patient profile. The purpose of this article is to describe the steps of continuous meniscal suture for the treatment of radial tears of the medial and lateral menisci.

The key to preventing early knee osteoarthritis is meniscal preservation.[1] This statement is based on the main functions of the meniscus, which are impact absorption, mechanical load distribution, lubrication, joint stability, and proprioception.[2-5]

The patterns of meniscal injury are diverse. They can be longitudinal, horizontal, oblique, radial, and complex. Radial lesions that extend to the joint capsule are called complete radial lesions. This type of injury compromises 2 of the main meniscal functions, which are impact absorption and distribution, which is equivalent, from a biomechanical perspective, to a total meniscectomy. This is because the meniscus loses its tensile strength, in addition to predisposing to meniscal extrusion.[6,7] Tears of the meniscal may lead to increased magnitude and changed distribution of mechanical stress contributing to the spontaneous subchondral bone osteonecrosis.[8]

Radial tears are commonly related to trauma in young patients and are often associated with other joint injuries,

From the National Institute of Traumatology and Orthopedics of Brazil, Rio de Janeiro (J.L.R.d.F., D.M.P., R.S.P.A., E.B.d.S., J.A.M.G., A.d.P.M., M.M.); Medical Science Faculty, State University of Rio de Janeiro, Rio de Janeiro (A.d.P.M.); Biomechanical Engineering Laboratory, Federal University of Santa Catarina, Florianópolis (C.R.d.M.R.); and Clinical Hospital of Ribeirão Preto, School of Medicine, University of São Paulo — USP Riberão Preto, São Paulo (R.S.), Brazil; and Twin Cities Orthopaedics, Edina (R.F.L.) and University of Minnesota Medical School, Minneapolis (R.F.L.), Minnesota, U.S.A.

The authors report the following potential conflicts of interest or sources of funding: J.L.R.d.F. has a patent, Meniscal Suture Device, pending in the United States and Brazil. A.d.P.M. has a patent, Meniscal Suture Device, pending in the United States. R.F.L reports consultant for Arthrex, Ossur, Smith & Nephew, and Linvatec; royalties from Arthrex, Ossur, Smith & Nephew, and Elsevier; research grants from Smith & Nephew and Ossur; and editorial boards of American Journal of Sports Medicine, Journal of Experimental Orthopaedics, International Journal of Sports Physical Therapy, *and* Knee Surgery, Sports Traumatology, Arthroscopy. *Full ICMJE author disclosure forms are available for this article online, as supplementary material.*

This filming of the surgical procedure was performed at the Arthroscopy Laboratory of the National Institute of Traumatology and Orthopedics of Brazil.

Received January 22, 2021; accepted March 18, 2021.

Address correspondence to José Leonardo Rocha de Faria, Instituto Nacional de Traumatologia e Ortopedia Jamil Haddad - Av. Brasil, 500, São Cristovão, Rio de Janeiro - RJ. CEP: 20940-070. E-mail: drjoseleonardorocha@gmail.com

© 2021 THE AUTHORS. Published by Elsevier Inc. on behalf of the Arthroscopy Association of North America. This is an open access article under the CC BY-NC-ND license (http://creativecommons.org/licenses/by-nc-nd/4.0/).

2212-6287/21132
https://doi.org/10.1016/j.eats.2021.03.026

with anterior cruciate ligament tears being one of the most prevalent.[9] In the recent past, the treatment of choice for this type of injury was partial meniscectomy. However, several studies have observed progressive joint degeneration after this type of treatment.[10-12]

Recently, several types of meniscal suture techniques involving radial lesions of the meniscus have been developed.[13-19] It is believed that such repairs may bring a decrease in future osteoarthritis in this patient profile. A systematic review published in 2016 showed that in short-term studies, ranging from 2 to 5 years of follow-up, all the techniques analyzed by the authors showed significant improvement in the Lysholm and International Knee Documentation Committee clinical scores.[20]

Since 2019, we have been using a Meniscus 4 A-II repair device (Síntegra Surgical, Pompéia - SP, Brazil), which allows meniscal suture to be performed continuously.[21-24] The purpose of this article is to describe the steps of continuous meniscal suture, in a format similar to an hourglass, for the treatment of radial lesions in the medial or lateral menisci. In Fig 1A to E, we can observe how the technique is configured.

Technical Note (With Video Illustration)

The patient is anesthetized with spinal anesthesia and placed in the supine position. After asepsis and antisepsis of the lower limbs and placement of surgical drapes, the limb to be operated is exsanguinated and kept under ischemia by a pneumatic tourniquet. We make the anterolateral, the anteromedial, and the transpatellar portals and then perform joint inventory, identifying the complete radial meniscal injury.

Continuous Meniscal Suture of Radial Tear of the Medial Meniscus

Initially, we identify the adductor tubercle, the articular interline, and the posteromedial aspect of the tibial plateau and make a 6-cm long oblique incision, slightly anterior to the aforementioned anatomical points, extending 2 to 3 cm distal to the articular interline. After dissecting the subcutaneous tissue, we identify and incise the fascia from the sartorius tendon. Care must be taken with the saphenous nerve, which passes about 5 cm posterior to the adductor tubercle.

We seek to identify a triangle formed by the joint capsule, semimembranosus tendon, and medial head of the gastrocnemius muscle. We digitally dissect expanding this triangle to facilitate the passage of the meniscal suture device.

Depending on the location of the radial tear, we decide which portal to insert the camera. In injuries from the middle-third to anterior, we position the camera in the anteromedial portal. In injuries from the middle-third to posterior, we position the camera in the anterolateral portal.

The suture device must be previously loaded with a long nonabsorbable thread (preferably greater than 60 cm in length) through the lumen. We adjust the wire asymmetrically in the device, with its smaller end facing the angled device aspect, called the anterior region of the device (Fig 2A). The device is introduced into the joint through the portal opposite to the camera, and it should penetrate the meniscus in its upper surface, 5 mm posterior to the radial tear, close to the capsule, in the red—red zone (Fig 2B and C). Through digital palpation through the previously performed approach, it is possible to feel the tip of the device before it crosses the joint capsule, minimizing the risk of iatrogenic injury.

The shortest wire is pulled out of the joint about 15 cm and secured with a Kelly clamp (Fig 2D). Then, we return with the Meniscus 4 A-II (Síntegra Surgical, Pompéia - SP, Brazil) to the joint (Fig 2E), and it is now inserted crossing obliquely the radial tear and penetrating the other side of the meniscus 5 mm anterior to the tear, far from the capsule, in the white or red—white area (Fig 2F). After the device exits through the posteromedial approach, we retract it about 0.5 cm, creating a loop with the suture thread (Fig 2G). We pull the loop formed at the posterior face of the device to gain extra-articular wire length. After we obtain a loop of an appropriate size, we pull the loop on the front face of the device, keeping it in that region of the device, making sure that the end of the wire that passes through the interior of the device, is the same that is passing through the arthroscopy portal. Then we hold that formed loop with a Kelly clamp (Fig 2H). Once again, the device returns to the joint (Fig 2I) and at this time, the point of entry into the meniscus must be 5 mm posterior to the radial tear, away from the capsule, crossing the tear horizontally, inserting the device posterior and distal to the radial tear (Fig 2J). After going through the capsule, we slightly retract the device, forming a loop again (Fig 2 K and L). We repeat the steps mentioned previously, forming a new loop on the anterior face of the device. We hold the second loop and move the device back into the joint again. The next step we cross the radial tear obliquely again (Fig 2M), introducing the device on the anterior and proximal side of the radial tear, 5 mm anterior to the radial tear, close to the joint capsule. Then, we repeat the aforementioned steps, forming the third loop (Fig 2N). Holding it, we retract the device into the joint again (Fig 2O). Finally, we cross the tear horizontally, inserting the device in the posterior and proximal side of the radial tear (Fig 2P). We pull the last loop formed (Fig 2Q), bringing the wire entirely to the extra-articular region, and then remove it from the lumen of the Meniscus 4 A-II (Síntegra Surgical, Pompéia - SP, Brazil) (Fig 2 R and S). We retract the device back into the joint, removing it from the knee.

Then, we have 3 loops and 2 wire ends at the extra-articular medial incision. With the help of a scalpel or a scissors, we cut all the loops (Fig 3 A and B). We pull

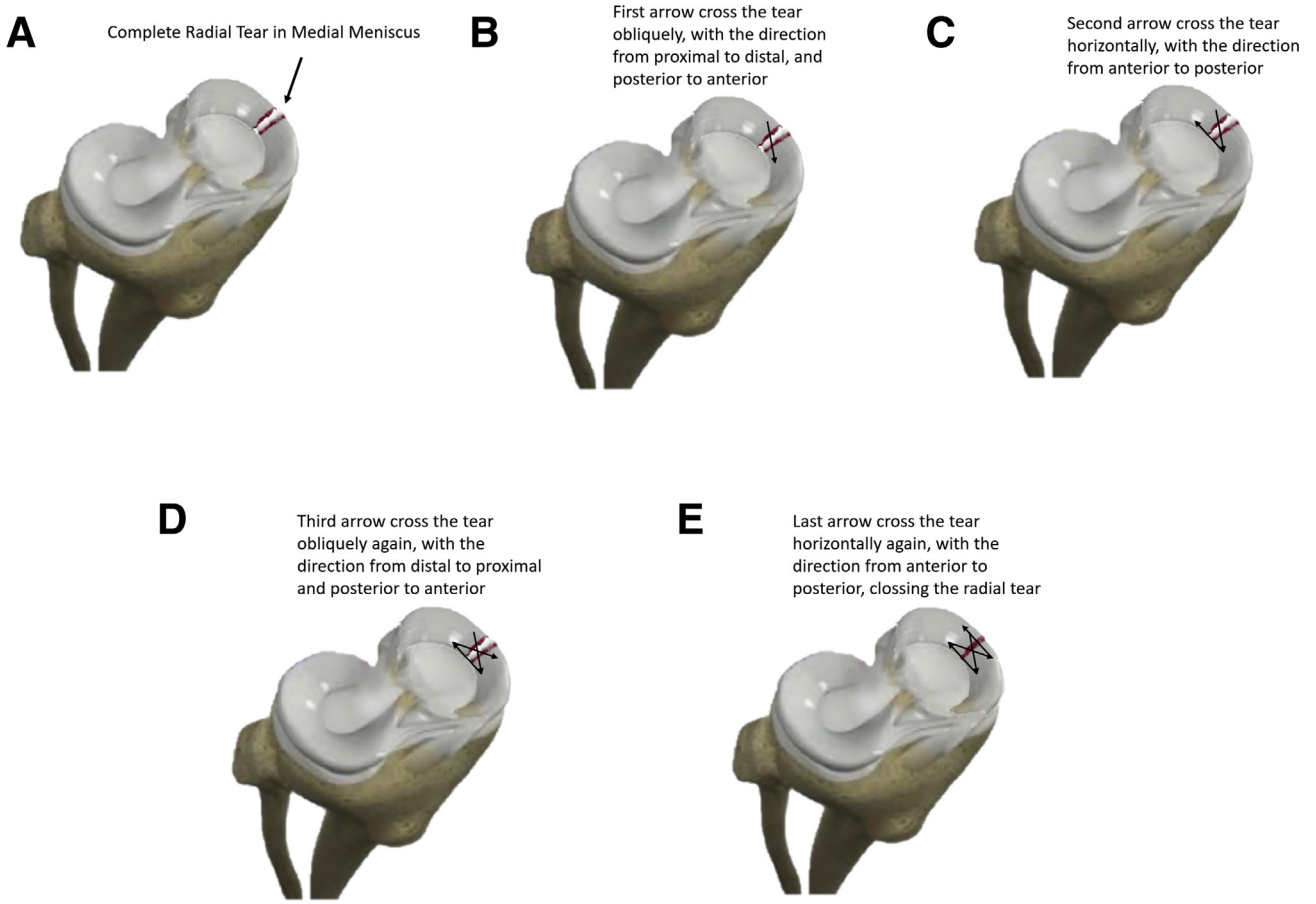

Fig 1. (A) Complete radial tear of a medial meniscus. (B) Arrow simulating the steps of the hourglass suture. First arrow: the direction from proximal to distal from posterior to anterior. (C) Second arrow: cross the tear horizontally, from anterior to posterior. (D) Third arrow: cross the tear obliquely again, from distal to proximal and posterior to anterior. (E) Last arrow; cross the tear horizontally again, from anterior to posterior, closing the radial tear.

wire by wire to find which wire connects with the other, and tie each suture with 4 knots (Fig 3 C-G). At this moment, we verify arthroscopically the reduction of the radial tear and the repair configuration similar to an hourglass or a Roman numeral 10 (Fig 4 A and B).

Rehabilitation

The rehabilitation protocol of surgeries that include repair of radial tears is very similar to the rehabilitation protocol of surgeries that involve reinsertion of the posterior meniscal root. We must keep the patient at non−weight-bearing for approximately 6 weeks. This is the period during which the healing process occurs in the meniscus, and thus we prevent the early mechanical load from causing the failure of the meniscus repair. If the tear is located in the posterior horn of the affected meniscus, the patient, in addition to non−weight-bearing, must not flex the knee more than 90° for the same period of time.[25-27] We recommend the following protocol,[25-27] to follow, for postoperative rehabilitation of patients undergoing repair of meniscal radial injuries.

Immediate Postoperative Period to the First Week

- Cryotherapy;
- Care for the surgical wound (keeping it always clean, dry, and with an occlusive dressing)
- Pain and edema control with analgesia
- Mobilization of the patella
- Tibial tarsal pump
- Use of knee immobilizer (indicated only in cases of tears on posterior horn)
- No loading on the operated limb
- Force passive and active extension gain
- Passive flexion up to 90° is allowed and should be stimulated to avoid joint stiffness
- Quadriceps activation (with isometric exercise).

First to Third Week

- Cryotherapy
- Care for the surgical wound (keeping it always clean, dry, and with an occlusive dressing, removing the stitches around the third week)

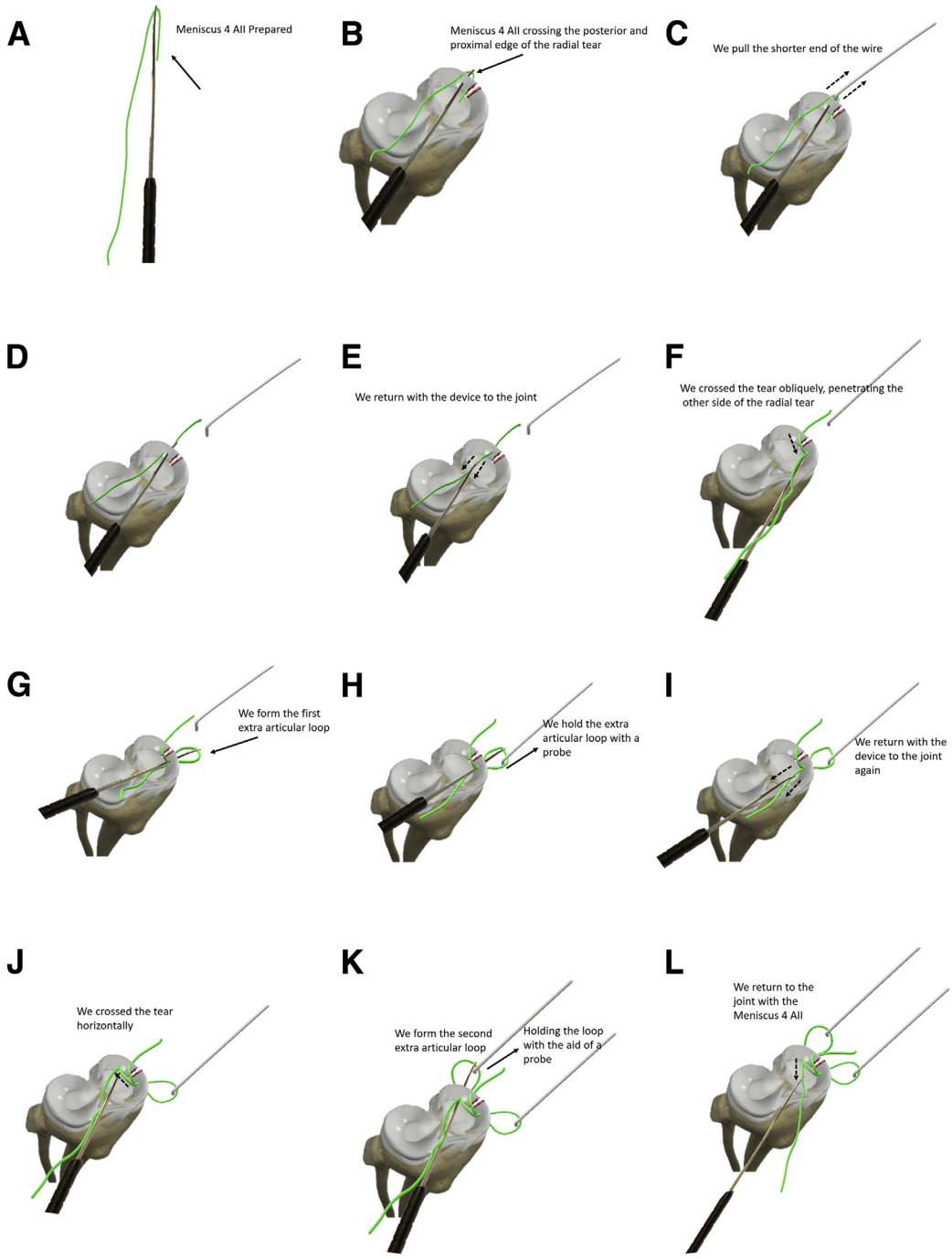

Fig 2. (A) The Meniscus 4 AII (Síntegra Surgical, Pompéia - SP, Brazil) is prepared, leaving the suture thread asymmetrical with the smallest end of the thread remaining in the anterior region of the device. (B) We perform a posteromedial approach, then introduce the device at the most posterior and upper edge of the radial tear. (C and D) With the aid of a probe, we pull the anterior (shorter) portion of the wire. (E) We return with the device into the joint. (F) We cross the lesion with the wire, introducing the device on the anterior and distal side of the radial tear. (G) We form the first extra-articular loop. (H) We hold the extra-articular loop with a probe. (I) We return with the device to the joint again. (J) We cross the tear horizontally, inserting the device in the posterior and distal side of the radial tear. (K) We form the second extra-articular loop, holding it with the aid of a probe, always holding the loop on the front side of it. (L) We return to the joint with the Meniscus 4 AII (Síntegra Surgical, Pompéia - SP, Brazil). (M) We cross the tear obliquely again, introducing the device on the anterior and proximal side of the radial tear. (N) We hold the third loop, with the aid of a probe, always holding the loop on the front side of it. (O) We return with the device, to the joint again. (P) We cross the tear horizontally, inserting the device in the posterior and proximal side of the radial tear. (Q) We pull the last loop formed, bringing the wire entirely to the extra-articular region. (R and S) We remove the wire from the inside of the lumen located at the device end and move the Meniscus 4 AII (Síntegra Surgical, Pompéia - SP, Brazil) back into the joint, removing it from the knee.

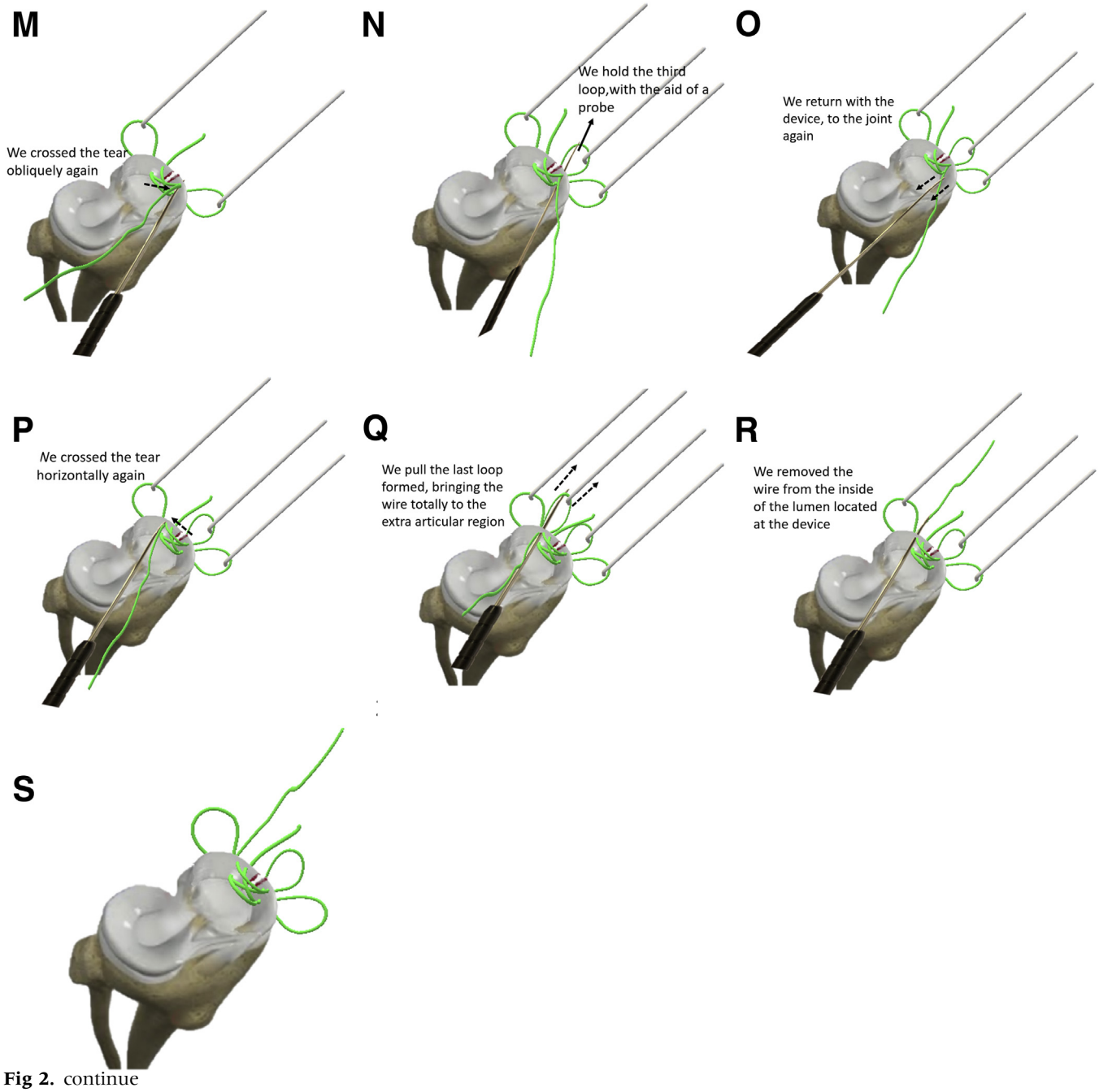

Fig 2. continue

- Analgesia to control pain and edema
- Tibial tarsal pump
- Use of knee immobilizer (indicated only in cases of tears on posterior horn)
- No loading with the operated limb
- Force passive and active extension gain
- Passive flexing allowed (flexion up to 90° if the tear location is on the posterior horn);
- Quadriceps isometric exercises
- Abductor and adductor isometric exercises.

Third to Sixth Week

- Immobilizer is no longer needed
- No loading with the operated limb
- Force passive and active extension gain
- Passive flexion beyond 90° allowed as tolerated by the patient (even if the radial tear is on the posterior horn);
- Quadriceps isometric exercises
- Abductor and adductor isometric exercises.

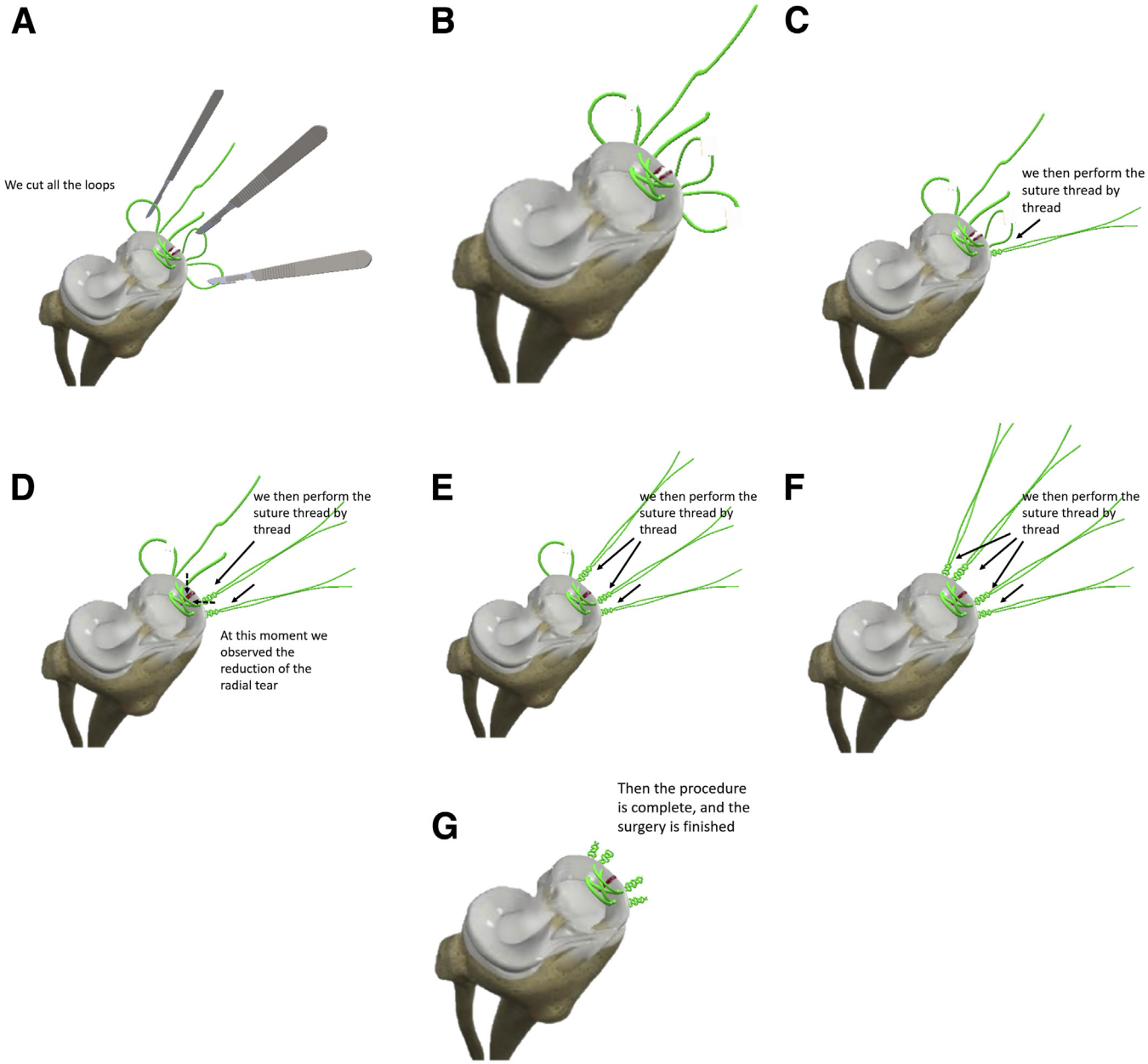

Fig 3. (A) With the help of a scalpel or a scissors, we cut all the loops. (B) With the help of a scalpel or a scissors, we cut all the loops. (C) We then perform the suture thread by thread. (D) We then perform the suturing thread by thread; at this moment, we observed the reduction of the radial tear. (E and F) We continue to perform the suture thread by thread. (G) Then the procedure is complete, and the surgery is finished.

Sixth Week to Eighth Week

- Start partial loading with 2 crutches
- Start active flexion gain
- Full passive joint gain
- Start on stationary bike with an elevated seat and without resistance.

Eighth to 12th Week

- Use of 1 crutch for 2 more weeks
- Focus on full active joint amplitude gain
- Start proprioception training
- Start resistance on the stationary bike
- Start closed kinetic chain exercises with knee flexion restriction angle between 0° and 30°, always with double legs (leg press, squat).

12th to 16th Week

- Closed kinetic chain exercises are maintained by increasing the knee joint range to 0 ° × 70 °
- Progression of exercises from double-leg to single-leg can be started if the patient shows an

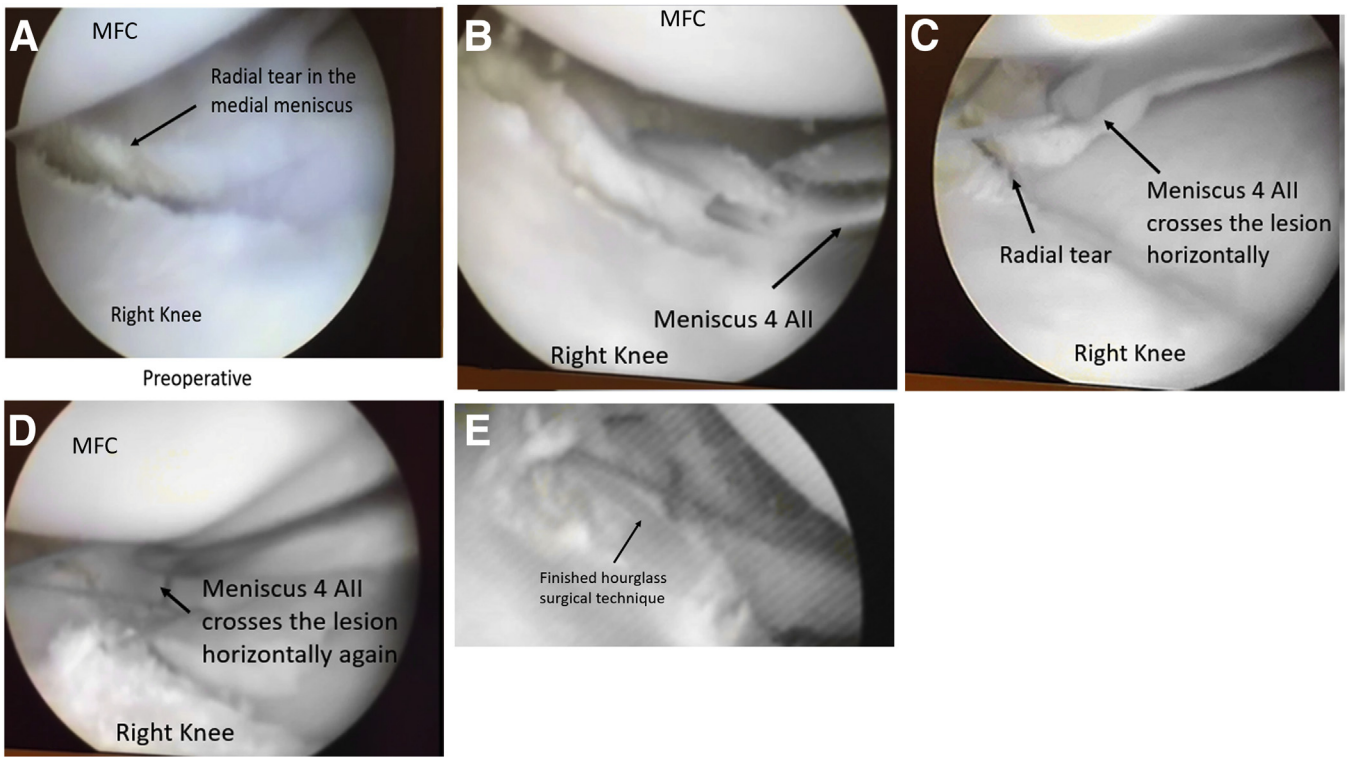

Fig 4. (A) Preoperative aspect of the radial tear on bovine model. (B) Meniscus 4 AII (Síntegra Surgical, Pompéia - SP, Brazil) crossing the posterior and proximal edge of the radial tear. (C) The device crosses the tear horizontally. (D) Meniscus 4 AII crosses the radial tear for the last time. (E) Postoperative aspect of the hourglass technique. (MFC, Medial Femoral Condyle.)

evolutionary improvement in exercises performed with double leg
- Freestyle swimming, elliptical, and treadmill walking are allowed to increase cardiovascular conditioning
- Knee proprioception exercises are started.

16th Week to Six Months

- Closed and open kinetic chain exercises are maintained by increasing the knee joint range to $0° \times 90°$;
- Single-leg exercises allowed
- Focus on muscle strengthening of the quadriceps, abductors, and external hip rotators
- Freestyle swimming, elliptical, and treadmill walking are allowed to increase cardiovascular conditioning
- Quadriceps index must be assessed with a manual dynamometer and at this stage the strength of the quadriceps on the operated limb must be greater than 80% of the unaffected limb.

After Six Months

- Maintain muscle strengthening
- Quadriceps index must be assessed with a manual dynamometer, and at this stage the strength of the quadriceps on the operated limb must be greater than 90% of the unaffected limb
- Evaluate return for sports activity.

Discussion

Complete radial tears present a therapeutic challenge for the surgeon, regardless of the region or zone in which the lesion is located.[28,29] Symptomatic partial radial lesions in the white—white area should be treated with partial meniscectomy to prevent the progression of the tear into the red—red area, as this progression can transform a partial into a complete lesion.[30] However, it is noteworthy that even small meniscectomy, less than 20% of sectioned area, also lead to increased tibiofemoral loading, which can cause joint degeneration.[31,32]

Meniscal repair of complete radial lesions should always be attempted to avoid joint degeneration.[20] The objective is to restore the meniscal circumferential fibers that work resisting axial stress, acting mainly on impact absorption and load distribution.[33]

In 2018 Stender et al.[34] published a biomechanical study with cadaver knees, comparing 3 surgical techniques for radial injuries: cross-suture, hashtag, and cross-tag. Complete radial lesions were created in the

Table 1. Advantages, Disadvantages, and Risks Associated With the Hourglass Technique for Radial Meniscus Tear

Advantages	Disadvantages	Risks	Limitations
Greater control over device exit point at the extra-articular region compared with other inside-out techniques	A posteromedial or lateral approach is necessary for neurovascular protection	Chondral injury with the tip of the device	A long nonabsorbable thread or tape is necessary
Lower risk of neurovascular injury	Need to repair each handle of suture stitch	Neurovascular injury if the posteromedial protector is not properly positioned	The device can be deformed at its extremity if it is pressed in an erroneous way, for example, if it is pressed against the tibial plateau or femoral condyle
Low cost - One single device and one long resistant suture wire or tape is capable to perform the entire repair	A learning curve is needed to perform the continuous meniscal suture	A 5-mm distance between the entry point of the device and the radial tear is necessary, avoid a rupture of the meniscal tissue	Technique performed with the meniscus 4 AII device (Síntegra Surgical, Pompéia - SP, Brazil)
Greater agility to perform the meniscal repair process, with no osseus tunnel necessary			

center of the meniscal body of the lateral meniscus and the 3 techniques were tested on an axial loading machine, with cyclic tests followed by load to failure tests. The authors found that the hashtag and cross-tag techniques showed less detachment from the meniscal edges compared to the cross-suture technique. However, no significant differences were found in the system stiffness and ultimate failure load between the three techniques.[34]

Another biomechanical study was carried out by Buckley et al.[35] evaluated 3 different types of radial injury repair associated with bone tunnels. The authors carried out the evaluations on 30 cadaver knees, 10 matched pairs, and 10 unpaired. First group was performed with 2 transtibial tunnels, the second group performed the horizontal and vertical "hybrid" mattress suture repair, and the third group with hybrid tunnel. A complete radial tear in the center of the medial meniscus body was performed in all cadavers. Gap distances at the tear site, ultimate failure load, and failure location were measured and recorded. The authors found similar results in the 3 groups; however, they also observed that when adding the vertical mattress suture functioning as a “rip stop” there was significantly reduced the likelihood of the sutures pulling through the meniscus during pull-to-failure testing for the hybrid and hybrid tunnel repairs as compared with the 2-tunnel repair. Therefore, the authors concluded that the vertical suture acting as a rip stop, prevents the occurrence of a cut-out at the edge of the meniscal tissue.[35] For this reason, in hourglass technique we recommend that the entrance of the device at the edge of the injury has a margin of at least 5 mm between the radial tear and the entry point of the meniscal suture device.

Wu et al.[36] conducted research comparing the clinical results of repairing complete radial injuries (n = 24) and longitudinal bucket handles injuries (n = 18). Both groups had significantly similar preoperative visual analog scale, Tegner, and International Knee Documentation Committees scores. The authors observed that the 2 groups showed significant improvement in the assessed scores, with no significant difference between them. The survival rate of meniscal repair was 88.9% in the radial tear group and 94.4% in the bucket handle tear group at 2 years of follow-up. With 5 years of follow-up, the same rate dropped slightly to 77.8% in the radial tear group and to 87.7% in the other group.[36]

A recent study published in 2019 by Venjakob et al.[37] evaluated, in a biomechanical test with porcine knees, whether the type of suture used in meniscal repair surgeries generates chondral injury over repeated cycling. The authors divided the sample of porcine knees into 5 groups with the following tribological pairs: group I, cartilage versus cartilage (control); group II, cartilage versus meniscus (control number 2); group III, cartilage versus meniscus sutured with 2.0 FiberWire (Arthrex, Naples, FL); group IV, cartilage versus sutured meniscus with 2.0 ULTRABRAID (Smith & Nephew, Andover, MA); and group V, cartilage versus sutured meniscus with 2.0 PDS (Ethicon, Somerville, NJ). The authors performed 2 points on each meniscus, a horizontal point and a vertical point. After performing friction biomechanical tests, the authors found that no lesions were observed in the control groups, both in macroscopic and histologic assessments. However, in groups III to V, different degrees of chondral lesion were found. These injuries were more severe in groups III and IV and also when the suture was performed vertically, as the direction of the suture is configured

perpendicularly to the evaluated movement surface.[37] When evaluating the result of this study, we believe that the thickness and configuration of the suture thread used for meniscal repair can influence the degree of chondral injury in the postoperative period of surgeries involving meniscal repair. Therefore, we must consider the possibility of replacing the suture threads with tapes such as FiberTape (Arthrex) or the Ultra High Molecular Weight Polyethylene Suture Tape (Síntegra Surgical, Pompéia - SP, Brazil), which can be an alternative that generates less chondral lesion postoperatively, since such tapes have a thinner configuration and have a resistance similar to ultraresistant wires, which may reduce these chondral lesions observed by the research by Venjakob et al. Biomechanical and clinical studies using tapes for meniscal suture are necessary to elucidate this issue.

Our technique allows the repair to be carried out continuously and quickly, with one suture wire or tape, in the hourglass format. We were able to reduce the radial tear margins, using associated oblique and horizontal repair configurations leaving the edges of the lesion aligned, increasing the chance of healing (Video 1).

One of the disadvantages of our technique is the need to perform a posteromedial or posterolateral surgical approach, which varies according to the location of the lesion. Another disadvantage is the absence of transosseous fixation of the repair (Table 1). One study conducted by the LaPrade research group, cited previously, reported improved results with this type of fixation.[35] The continuous radial suture is a fast and safe option for the treatment of complete radial lesions located in the body or in the transition from the body to the posterior meniscal horn.

References

1. Zdanowicz U, Smigielski R. Meniscus anatomy. In: LaPrade RF, Arendt EA, Getgood A, Faucett SC, eds. *The menisci: A comprehensive review of their anatomy, biomechanical function and surgical treatment*. Berlin: Springer-Verlag, 2017;1-8.
2. McDermott ID, Amis AA. The consequences of meniscectomy. *J Bone Joint Surg Br* 2006;88. 1549e1556.
3. Meakin JR, Shrive NG, Frank CB, Hart DA. Finite element analysis of the meniscus: The influence of geometry and material properties on its behaviour. *Knee* 2003;10:33e41.
4. Amendola A, Bonasia DE. The menisci: Anatomy, healing response, and biomechanics. *Knee Joint* 2012:5e9.
5. Seedhom BB, Dowson D, Wright V. Proceedings: Functions of the menisci. A preliminary study. *Ann Rheum Dis* 1974;33:111.
6. Messner K, Gao J. The menisci of the knee joint. Anatomical and functional characteristics, and a rationale for clinical treatment. *J Anat* 1998;193:161e178.
7. Lerer DB, Umans HR, Hu MX, Jones MH. The role of meniscal root pathology and radial meniscal tear in medial meniscal extrusion. *Skeletal Radiol* 2004;33:569-574.
8. Zhang K, Li L, Yang L, et al. The biomechanical changes of load distribution with longitudinal tears of meniscal horns on knee joint: A finite element analysis. *J Orthop Surg Res* 2019;14:237.
9. Bin SI, Kim JM, Shin SJ. Radial tears of the posterior horn of the medial meniscus. *Arthroscopy* 2004;20. 373e378.
10. Fairbank TJ. Knee joint changes after meniscectomy. *J Bone Joint Surg Br* 1948;30:664-670.
11. Hede A, Larsen E, Sandberg H. Partial versus total meniscectomy. A prospective, randomised study with long-term follow-up. *J Bone Joint Surg Br* 1992;74:118-121.
12. Papalia R, Del Buono A, Osti L, Denaro V, Maffulli N. Meniscectomy as a risk factor for knee osteoarthritis: A systematic review. *Br Med Bull* 2011;99:89-106.
13. James EW, LaPrade CM, Feagin JA, LaPrade RF. Repair of a complete radial tear in the midbody of the medial meniscus using a novel crisscross suture transtibial tunnel surgical technique: A case report. *Knee Surg Sports Traumatol Arthrosc* 2015;23:2750-2755.
14. Nakata K, Shino K, Kanamoto T, et al. New technique of arthroscopic meniscus repair in radial tears In: Doral MN. In: *Sports injuries*. Berlin: Springer, 2012;305-311.
15. Ra HJ, Ha JK, Jang SH, Lee DW, Kim JG. Arthroscopic inside-out repair of complete radial tears of the meniscus with a fibrin clot. *Knee Surg Sports Traumatol Arthrosc* 2013;21:2126-2130.
16. Saliman JD. The circumferential compression stitch for meniscus repair. *Arthrosc Tech* 2013;2:e257-e264.
17. Song HS, Bae TY, Park BY, Shim J, In Y. Repair of a radial tear in the posterior horn of the lateral meniscus. *Knee* 2014;21:1185-1190.
18. Steiner SRH, Feeley SM, Ruland JR, Diduch DR. Outside-in repair technique for a complete radial tear of the lateral meniscus. *Arthrosc Tech* 2018;7:e285-e288.
19. Yin SSS, Remigio van Gogh AM, Youn GM, et al. Transtibial pull-out repair of converted radial tear adjacent to medial meniscus root. *Arthrosc Tech* 2019;9:e171-e176.
20. Moulton SG, Bhatia S, Civitarese DM, Frank RM, Dean CS, LaPrade RF. Surgical techniques and outcomes of repairing meniscal radial tears: A systematic review. *Arthroscopy* 2016;32:1919-1925.
21. Rocha de Faria JL, Pavão DM, Villardi AM, de Sousa EB, Guimaraes JM, Carmo JMM, Mozella AP. Continuous meniscal suture technique of the knee. *Arthrosc Tech* 2020;9:e791-e796.
22. Rocha de Faria JL, Pavão DM, Pedrinha ISM, Sousa EB, Guimaraes JM, Gomes BA, Mozella AP. Posterior meniscal root repair using a meniscal suture device. *Arthrosc Tech* 2020;9:e905-e912.
23. Rocha de Faria JL, Pavão DM, Cruz RS, Sousa EB, Guimarães JM, Campos MCO, Mozella AP. Vertical continuous meniscal suture technique. *Arthrosc Tech* 2020;9:e1335-e1340.
24. Rocha de Faria JL, Pavão DM, Padua VBC, Sousa EB, Guimarães JM, Gomes BA, Mozella AP. Outside-in continuous meniscal suture technique of the knee. *Arthrosc Tech* 2020;9:e1547-e1552.

25. Mueller BT, Moulton SG, O'Brien L, LaPrade RF. Rehabilitation following meniscal root repair: A clinical commentary. *J Orthop Sports Phys Ther* 2016;46:104-113.
26. Dean RS, DePhillipo NN, Monson JK, LaPrade RF. Peripheral stabilization suture to address meniscal extrusion in a revision meniscal root repair: Surgical technique and rehabilitation protocol. *Arthrosc Tech* 2020;9:e1211-e1218.
27. Rocha de Faria JL, Pavão DM, Moreirão MC, et al. Posterior root repair of medial meniscus combined with valgus opening wedge tibial osteotomy [published online April 26, 2021]. *Arthrosc Tech*. https://doi.org/10.1016/j.eats.2021.01.042.
28. Tenuta JJ, Arciero RA. Arthroscopic evaluation of meniscal repairs. Factors that affect healing. *Am J Sports Med* 1994;22:797-802.
29. Uchida R, Horibe S, Shiozaki Y, Shino K. All-inside suture repair for isolated radial tears at the midbody of the lateral meniscus. *Arthrosc Tech* 2019;8:e1451-e1456.
30. McDermott I. Meniscal tears, repairs and replacement: Their relevance to osteoarthritis of the knee. *Br J Sports Med* 2011;45:292-297.
31. Seitz AM, Lubomierski A, Friemert B, Ignatius A, Dürselen L. Effect of partial meniscectomy at the medial posterior horn on tibiofemoral contact mechanics and meniscal hoop strains in human knees. *J Orthop Res* 2012;30:934-942.
32. Baratz ME, Fu FH, Mengato R. Meniscal tears: The effect of meniscectomy and of repair on intraarticular contact areas and stress in the human knee. A preliminary report. *Am J Sports Med* 1986;14:270-275.
33. Ridley TJ, Arendt EA, Macalena JA. Radial meniscal tears: Updates on repair techniques and outcomes. In: LaPrade RF, Arendt EA, Getgood A, Faucett SC, eds. *The menisci: A comprehensive review of their anatomy, biomechanical function and surgical treatment*. Berlin: Springer-Verlag, 2017;93-102.
34. Stender ZC, Cracchiolo AM, Walsh MP, Patterson DP, Wilusz MJ, Lemos SE. Radial tears of the lateral meniscus-two novel repair techniques: A biomechanical study. *Orthop J Sports Med* 2018;6(4).
35. Buckley PS, Kemler BR, Robbins CM, et al. Biomechanical comparison of 3 novel repair techniques for radial tears of the medial meniscus: The 2-tunnel transtibial technique, a "hybrid" horizontal and vertical mattress suture configuration, and a combined "hybrid tunnel" technique. *Am J Sports Med* 2019;47:651-658.
36. Wu IT, Hevesi M, Desai VS, et al. Comparative outcomes of radial and bucket-handle meniscal tear repair: A propensity-matched analysis. *Am J Sports Med* 2018;46:2653-2660.
37. Venjakob AJ, Föhr P, Henke F, et al. Influence of sutures on cartilage integrity: Do meniscus sutures harm cartilage? An experimental animal study. *Arthroscopy* 2019;35:1509-1516.