International Orthopaedics (2019) 43:2065–2070
https://doi.org/10.1007/s00264-018-4147-9

ORIGINAL PAPER

Outcomes after knee arthroplasty in extra-articular deformity

Fabricio Bolpato Loures [1,2] · Wesley Correia [1] · João Henrique Reis [1] · Rodrigo Sattamini Pires e Albuquerque [1] · Alan de Paula Mozela [1] · Eduardo Branco de Souza [1] · Phelippe Valente Maia [1] · João Maurício Barretto [1]

Received: 15 February 2018 / Accepted: 6 September 2018 / Published online: 14 September 2018
© SICOT aisbl 2018

Abstract

Purpose To assess functional outcomes in patients undergoing total knee arthroplasty (TKA) without previous corrective osteotomy for treatment of knee osteoarthritis associated with extra-articular deformity.

Methods From January to December 2016, patients with knee osteoarthritis with extra-articular deformities who presented for preoperative assessment before TKA were evaluated prospectively. Physical and radiological characteristics were documented pre- and postoperatively.

Results TKA was performed in 33 knees; 25 were considered for analysis. The mean age was 65.2 years (range, 48–79 years). Sixteen deformities were secondary to fractures and nine to failed osteotomies. The mean Knee Society Score (KSS) improved from 27.1 pre-operatively to 68.7 post-operatively ($p = 0.000$). Pre-operative mechanical axis ranged from 32° varus (negative) to 26° valgus. After correction, 20 knees were within 3° (varus or valgus) of mechanical alignment.

Conclusion In patients with extra-articular deformities, TKA with asymmetric intra-articular resection and ligament balancing can relieve pain and realign the mechanical axis of the lower limb.

Keywords Arthroplasty · Extra-articular deformity · Knee · Mechanical axis

Introduction

Extra-articular deformities of the knee may occur as sequelae of lower extremity fractures with malunion, secondary to failure of corrective osteotomies, or due to disorders of bone metabolism [1]. These deformities change the distribution of mechanical loads at the knee, leading to early secondary osteoarthritis [2, 3]. In the final stages of this disease process, once conservative treatment has failed, total knee arthroplasty (TKA) is an option [4]. Surgery aims to restore function, relieve pain, and restore the mechanical axis of the lower limb.

Current options for TKA in patients with extra-articular deformities include a two-stage procedure, with corrective osteotomy followed by a second-stage TKA; single-stage osteotomy and TKA; or TKA with asymmetric intra-articular resection for compensation of the deformity, followed by ligament balancing [5].

Corrective osteotomy with simultaneous TKA has been advocated due to the possibility of restoring anatomy while streamlining the ligament balancing step. However, this technique may be associated with a high rate of complications [6, 7].

✉ Fabricio Bolpato Loures

Wesley Correia
wesleysot86@gmail.com

João Henrique Reis
joaohenriquecostareis@gmail.com

Rodrigo Sattamini Pires e Albuquerque
rodalbuquerque19@gmail.com

Alan de Paula Mozela
apmozella@terra.com.br

Eduardo Branco de Souza
eduardobsousa@globo.com

Phelippe Valente Maia
phemaia@yahoo.com.br

João Maurício Barretto
joao.barretto1@gmail.com

[1] Knee Surgery Center, Instituto Nacional de Traumatologia e Ortopedia (INTO), Av. Brasil, 500, São Cristóvão, Rio de Janeiro, RJ 20940-070, Brazil

[2] Rio de Janeiro, Brazil

Asymmetrical intra-articular resection and ligament balancing allows implantation of the prosthesis while obviating the need to intervene on the focus of the deformity. However, this approach has limitations, and is influenced by the severity of the deformity and its distance from the joint. Restoration of the mechanical axis of the lower limb, adequate ligament balance, and degree of implant constraint are associated with the durability of TKA. At the end of surgery, these goals must have been achieved, regardless of the technique chosen.

Within this context, the primary objective of the present study is to assess functional outcomes in patients who underwent total knee arthroplasty (TKA) without previous corrective osteotomy for treatment of knee osteoarthritis associated with extra-articular deformity. The secondary objective was to conduct a radiographic evaluation of correction of the mechanical axis of the lower limb.

Material and methods

Patients with knee osteoarthritis associated with limb deformity secondary to fractures of the lower extremity who presented to the pre-operative assessment clinic of the study facility between January 2012 and December 2016 and were scheduled to undergo TKA were enrolled for prospective evaluation. All patients with extra-articular deformities who agreed to participate by signing an informed consent form and underwent surgical treatment during the year 2016 were included in the sample. Patients with severe deformities who required previous or simultaneous corrective osteotomy were excluded, as were those who missed their scheduled post-operative outpatient follow-up visits. Approval for the study was obtained from the institutional Research Ethics Committee (opinion no. 2,046,597).

A protocol was designed to collect data on patient characteristics (age, gender, weight, height, skin colour), location of the deformity (intra-articular, metaphyseal, or diaphyseal; distance from the joint), which and how many planes were involved (one, two, or three), etiology of the deformity (sequelae of malunited fracture, failed osteotomy, or metabolic disease), number of previous surgical procedures, and number of scars. Range of motion and the Knee Society Score (KSS), in its validated Portuguese-language version [8], were assessed pre- and post-operatively.

Pre-operative planning was performed using standard weight-bearing panoramic radiographs of the lower limbs. When the deformity was located on the femur, a line perpendicular to the mechanical axis of the femur was drawn to ascertain whether the asymmetry of the cut would preserve the epicondyles, as described by Wang et al. [6] (Fig. 1a, b). In the case of tibial deformities, a line drawn on the distal diaphysis should touch the tibial plateau to allow correction to be made via an asymmetric cut.

The asymmetry of resection, calculated pre-operatively, and its relation to the mechanical axis of the bone was checked intra-operatively with the aid of a C-arm image intensifier and extramedullary alignment guide.

The pre- and post-operative degree of deformity and mechanical axes (Fig. 2a) and the mechanical alignment of the implant (Fig. 2b) were documented on routine radiographs. Post-operative outpatient follow-up visits for clinical evaluation were scheduled at three weeks, three months, and six months.

Ligament instability was assessed manually and considered acceptable if between 2 and 4 mm for extension and 2 and 6 mm for flexion. In all cases, TKA was performed without navigation. All patients were assigned to receive a posterior-stabilized prosthesis, although a semi-constrained prosthesis was available in the operating room if needed.

Data were collected and entered into a Microsoft Excel 2007 spreadsheet database for later analysis in IBM SPSS Version 22.0. Sample characteristics were analyzed through descriptive statistics (mean, median, minimum, maximum, standard deviation, coefficient of variation [CV]) and simple frequency distributions.

For inferential analysis, the Kolmogorov–Smirnov and Shapiro–Wilk tests were used to verify the assumption of normality. Normally distributed variables were evaluated with Student's t test, while those with a non-normal distribution were evaluated by the Wilcoxon test. The binomial test was used to compare two proportions.

Correlation analysis was used to test for association between two quantitative variables. Correlations between the variables of interest were determined by Pearson coefficients if normally distributed or by Spearman coefficients otherwise. p values less than 0.05 were below the set significance level, thus rejecting the null hypothesis. Correlation between two variables was considered sufficiently strong when greater than 0.7.

Results

Between January and December 2016, 33 knees of patients with osteoarthritis associated with limb deformity secondary to fracture were prospectively operated. Eight patients were excluded from analysis (seven who had only intra-articular involvement and one who did not regularly attend the scheduled outpatient visits for postoperative follow-up). Thus, the final sample consisted of 25 patients. The mean length of follow-up was eight months (range, 3–18 months).

Regarding gender, 14 patients were female and 11 were male. The mean age of the sample was 65.2 years (standard deviation, 7.7 years; range, 48 to 79 years). Only four patients were within normal body mass index (BMI) range; all 21 others were overweight or obese.

Regarding the aetiology of deformity, nine were due to failed osteotomies (3 tibial, 7 femoral) and 16 were secondary to

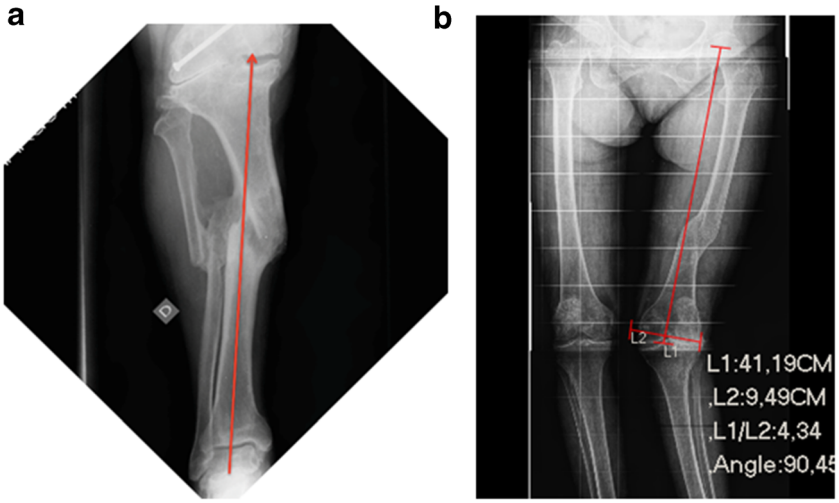

Fig. 1 Method described by Wang to evaluate whether correction by asymmetric intra-articular resection and ligament balancing is possible. **a** Tibia. **b** Femur

fractures (9 tibial, 7 femoral). The mean distance from the deformity to the joint was 9.9 cm (range, 2.7 to 25.2 cm). The mean time elapsed between the original trauma and referral for arthroplasty was 25.6 years (range, 5 to 60 years). These data are shown in Table 1.

All patients had deformities in the coronal plane. Fifteen also had deformities in the sagittal plane, while only one had a deformity in the axial plane (12° of external rotation). There were ten uniplanar and 15 biplanar deformities. The distribution of deformities and their statistics are shown in Table 2.

Nineteen patients had undergone previous surgical interventions and 22 had scars on the target area of the knee.

The range of motion (ROM) improved slightly, with mean values increasing from 92.6 to 96.4°. Despite this numerical improvement, the change was not statistically significant ($p = 0.303$) and was essentially attributable to a gain in extension, which ranged from 5.4 to 1.2° of flexural deformity. The change in ROM is illustrated in Fig. 3.

KSS values improved significantly, ranging from 27.1 points pre-operatively to 68.7 points post-operatively ($p = 0.000$) (Fig. 4).

The pre-operative mechanical axis ranged from 32° varus (negative) to 26° valgus (Table 3).

Post-operatively, there was significant improvement, with mean values ranging from − 9.3 to 0.6° ($p = 0.009$) (Fig. 5).

Twenty-two patients exhibited mechanical alignment of the implant, with deviation not exceeding 3°. Only four patients had higher values, three with valgus deviation (one with 4°, two with 5°) and one with 6° of varus deviation. After ligament balancing, all patients could be treated with posterior-stabilized (PS) implants.

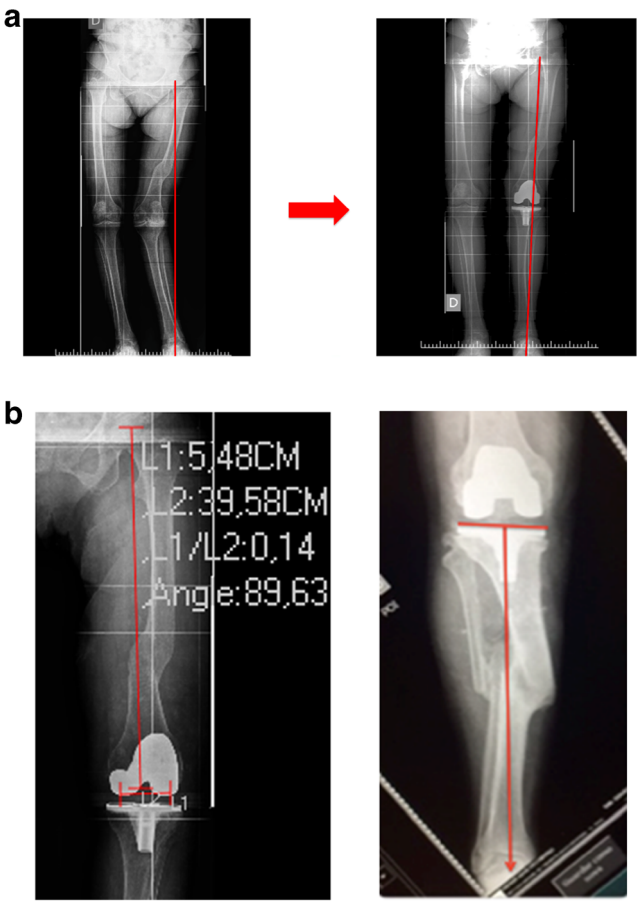

Fig. 2 **a** Assessment of anatomical axis before and after surgery. **b** Radiographic assessment of mechanical alignment of the implant

Table 1 Distance from the joint line and time to progression to TKA

Statistic	Distance from joint (cm)	Time elapsed between trauma and TKA (years)
Mean	9.9	25.6
Median	8.3	22.0
Standard deviation	6.3	16.2
Minimum	2.7	5.0
Maximum	25.2	60.0
Range	22.6	55.0
Coefficient of variation	0.6	0.6

TKA total knee arthroplasty

Table 2 Statistical analysis of deformities

Type of deformity		Deformity (degrees)					Coefficient of variation	Number of cases
		Mean	Median	Minimum	Maximum	Standard deviation		
Coronal	Varus	10	11	1	20	6	0.6	21
	Valgus	10	8	3	22	9	0.9	4
Sagittal	Flexion	11	6	2	37	12	1.1	10
	Extension	7	7	5	9	2	0.3	3

By the end of the sixth month of follow-up, only one patient needed reintervention (for manipulation under anesthesia due to arthrofibrosis).

Discussion

Osteoarthritis in patients with extra-articular deformities is neither common nor rare; up to 12% of TKA candidates are so affected [9]. Thus, it is not unusual for orthopaedic surgeons to come across this situation [10]. In these cases, the role of TKA is not only to relieve pain, but also to realign the limb [3]. Previous high tibial osteotomy seems not to be determinant for having worse outcomes after TKA [11]. Puliero et al. performed a ten year follow-up analysis in patients with varus deformities greater than 10° and concluded that TKA is a patient-friendly, and a predictable good outcome procedure [12].

Some authors consider prior or simultaneous osteotomy as the gold standard to treat extra-articular deformities, as it allows correction of all three planes and does not require wide detachment of soft tissues [3]. Gunst et al. suggested that lateral and medial parapatellar approaches presented equivalent results for TKA in mild valgus knees [13]. Asymmetric resection with ligament balancing is not a simple procedure and essentially depends on four factors: the magnitude of the deformity, its distance to the joint line of the knee, the direction of the deviation, and whether the femur or tibia are affected [14]. Thus, using fixed angles to define the deformity treatment method of choice does not reflect the true interference of the deformity with the joint. The method developed by Wang et al. [6] allows practical assessment of the level of resection asymmetry and of whether ligament integrity will be compromised. Although these authors advocate that the bone cut should not exceed 10 mm at the highest height of the trapezium, we followed the recommendations of Koenig et al. [5], who described asymmetric resections of up to 20 mm on the longer side, if they did not compromise the ligament attachment sites. Tan et al. suggested that the planned valgus cut angle and the femoral entry point should be individualized, since the deformity of the distal femoral diaphysis is quite various in different valgus knees [15]. Moreover, Palanisami et at. affirmed that valgus correction is variable and depends on femoral bowing, neck-shaft angle, and pre-operative deformity [16].

Post-traumatic osteoarthritis (PTOA) may affect up to 21–44% of patients with a history of lower limb fracture [4]. Lonner et al. [7] reported that PTOA is more common after tibial fractures than after femoral fractures, and that these cases follow a slower course. Bala et al. [9] reported that patients with sequelae after fractures progress to TKA at a younger age than those with primary OA. The mean age in our sample was 65.2 years, with only two patients undergoing TKA before age 60. In their sample of 15 patients, Wang et al. reported a mean time of 18.4 years from fracture to TKA. Although our sample was also composed of patients with deformities resulting from failure of osteotomies, which exhibit a sharp decline in durability from the 10th year onward

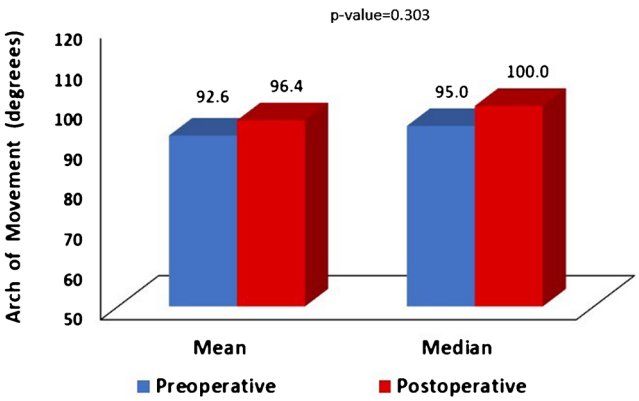

Fig. 3 Post-operative improvement in range of motion

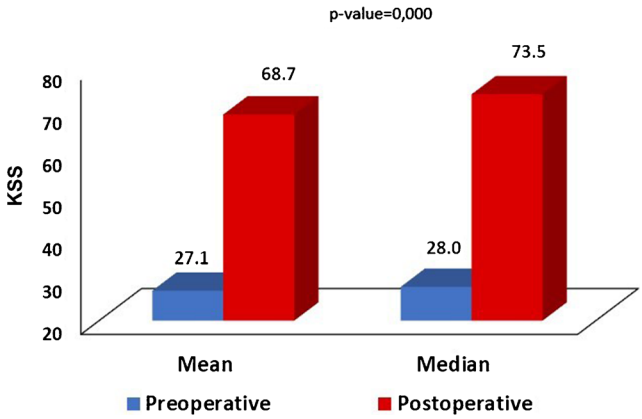

Fig. 4 Post-operative change in Knee Society Score

Table 3 Change in mechanical axis of the lower limb

Statistic	Pre-operative	Post-operative	Improvement
Mean	− 9.3	0.6	9.9
Median	− 9.1	1	11.4
Standard deviation	14.7	2.8	14.6
Minimum	− 32.31	− 6	− 29
Maximum	26	5	26.73
Range	58.31	11	55.73
Coefficient of variation	−1.58	5.10	1.48

[17], the time for progression to TKA was much longer, with an average of 25.6 years. These findings may be attributable to our less aggressive indications for arthroplasty, with continuation of conservative treatment until more advanced ages.

Twenty-one patients were overweight or obese and only four had a normal BMI. This confirms the role of obesity in the pathogenesis and progression of OA [18].

Range of motion exhibited slight improvement, essentially due to gain in extension. Our outcomes are consistent with those described by Weis et al. [19], who operated on 109 patients with sequelae of lower limb fractures and observed a slight improvement in ROM. We believe that, as described by Carvalho Junior et al. [20], pre-operative ROM is the main predictor of the ROM that will be achieved post-operatively.

The increase in KSS in the third post-operative month was significant ($p = 0.000$), which coincides with the findings of Saleh et al. [21] in their systematic review of the literature. As pain accounts for half of the Knee Society Score, this increase can be interpreted as a reflection of the patient's clinical improvement [21].

Candidates for TKA are generally older adults with a low haemodynamic reserve and less potential for consolidation. Osteotomy has the advantage of correcting the mechanical axis in all three planes, although the outcome of TKA then depends on site consolidation or, in the case of two-stage surgery, the patient will have a very long road to complete recovery. Lonner et al. [7] operated on 11 patients with sequelae of femoral fracture and PTOA. Corrective osteotomy was performed at the same time as prosthesis placement, and five patients experienced complications. Radke et al. [22] performed TKA in ten patients with proximal tibial osteotomy and tibial deformity. Two patients in their series had complications. Our sample, in which correction was performed via intra-articular resection and ligament balancing, had a low rate of complications, with only one revision surgery (manipulation of arthrofibrosis) in the first 6 months.

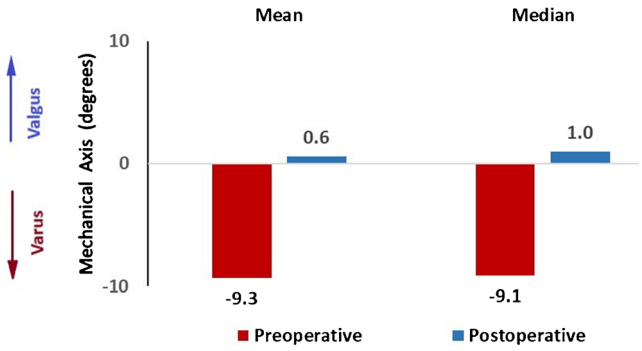

Fig. 5 Demonstration of improvement in the mechanical axis of the lower limb

Gang et al. performed TKA in nine patients with extra-articular deformities, using the asymmetric bone cut with ligament balancing technique in seven cases. Four cases developed intra-operative instability requiring conversion to a semi-constrained implant (Constrained Condylar Knee, CCK). Czekaj et al. affirmed that treatment of patients with severe (> 10°) varus or valgus deformities could be successfully achieved using low constraint deep-dish mobile bearing implant associated to standard approach and soft tissues management [23]. Another study suggested that a posterior cruciate-retaining prosthesis (e-Motion FP®) using computer navigation presented at least equivalent, even superior, results to standard posterior-stabilized prosthesis in the treatment of patients with over than 10° varum [24]. Luque et al. concluded that CCK implants were indicated to patients with unstable knee osteoarthritis presenting deformities greater than 22° or valgus or less than − 8° varus and insufficient collateral ligaments [25]. In our practice, CCK implants were always available during the operation, although no patient in the sample required this type of implant. All were treated with a posterior-stabilized (PS) prosthesis.

In PTOA of the knee with extra-articular deformity, prosthesis placement entails realignment of the limb to ensure stable fixation of the implant and to minimize wear of the component [2]. Mechanical alignment of up to 3° of varus or valgus with respect to the mechanical axis increases the durability of the implant [26]. This value was achieved in 20 patients; in the remaining five, deviation was 1° to 3° greater than planned. Only a longer follow-up time would be able to demonstrate whether this minor difference has a significant impact on implant durability.

Bottros et al. [27] advocate the use of navigation for patients with extra-articular deformity, as the changes in bony landmarks, impossibility of conventional intramedullary rod placement, and presence of osteosynthesis hardware can all hinder or preclude proper alignment of the implant with conventional alignment guides. We did not use a navigator because of the high cost of these systems. However, the satisfactory outcomes obtained demonstrate that adequate pre-operative planning can obviate the need for navigation entirely, as also argued by Gang et al. [28].

Our study has some limitations, including the short follow-up time, which may have been sufficient to detect such complications as early implant loosening. Moreover, we did not use a specific protocol for pain evaluation, since the Knee Society Score (KSS), which already includes pain, was used

as a parameter of functional improvement. However, our goal was to evaluate whether TKA alone was able to correct extra-articular deformities in patients with knee OA, and this was accomplished successfully.

In conclusion, in patients with extra-articular deformities, TKA with asymmetric resection and ligament balancing is a safe procedure which, although technically demanding, can relieve pain and realign the mechanical axis of the lower limb.

Compliance with ethical standards

Conflict of interest The authors have no conflicts of interest.

Research involving human participants The research project was approved by the institutional Research Ethics Committee with opinion number 2,046,597.

All procedures performed in studies involving human participants were in accordance with the ethical standards of the institutional research committee and with the 1964 Helsinki declaration and its later amendments or comparable ethical standards.

Informed consent Informed consent was obtained from all individual participants included in the study.

References

1. Krackow KA, Holtgrewe JL (1990) Experience with a new technique for managing severely overcorrected valgus high tibial osteotomy at total knee arthroplasty. Clin Orthop Relat Res 213–224
2. Deschamps G, Khiami F, Catonne Y, Chol C, Bussiere C, Massin P, French H, Knee S (2010) Total knee arthroplasty for osteoarthritis secondary to extra-articular malunions. Orthop Traumatol Surg Res 96:849–855
3. Chua W, Wang W (2013) Intra-articular correction of extra-articular tibial deformities with total knee arthroplasty. Int J Surg Case Rep 4: 276–278
4. Lunebourg A, Parratte S, Gay A, Ollivier M, Garcia-Parra K, Argenson JN (2015) Lower function, quality of life, and survival rate after total knee arthroplasty for posttraumatic arthritis than for primary arthritis. Acta Orthop 86:189–194
5. Koenig JH, Maheshwari AV, Ranawat AS, Ranawat CS (2009) Extra-articular deformity is always correctable intra-articularly: in the affirmative. Orthopedics 32
6. Wang JW, Wang CJ (2002) Total knee arthroplasty for arthritis of the knee with extra-articular deformity. J Bone Joint Surg Am 84-A: 1769–1774
7. Lonner JH, Siliski JM, Lotke PA (2000) Simultaneous femoral osteotomy and total knee arthroplasty for treatment of osteoarthritis associated with severe extra-articular deformity. J Bone Joint Surg Am 82:342–348
8. Silva ALP, Demange MK, Gobbi RG, Silva TFC, Pecora JR, Croci AT (2012) Translation and validation of the knee society score – kss for brazilian Portuguese. Acta Ortop Bras 20:25–30
9. Bala A, Penrose CT, Seyler TM, Mather RC 3rd, Wellman SS, Bolognesi MP (2015) Outcomes after total knee arthroplasty for post-traumatic arthritis. Knee 22:630–639
10. Papadopoulos EC, Parvizi J, Lai CH, Lewallen DG (2002) Total knee arthroplasty following prior distal femoral fracture. Knee 9: 267–274
11. Paredes-Carnero X, Leyes M, Forriol F, Fernández-Cortiñas AB, Escobar J, Babé JB (2018) Long-term results of total knee arthroplasty after failed high tibial osteotomy. Int Orthop 42(9): 2087–2096
12. Puliero B, Favreau H, Eichler D, Adam P, Bonnomet F, Ehlinger M (2018) Total knee arthroplasty in patients with varus deformities greater than ten degrees: survival analysis at a mean ten year follow up. Int Orthop
13. Gunst S, Villa V, Magnussen R, Servien E, Lustig S, Nevret P (2016) Equivalent results of medial and lateral parapatellar approach for total knee arthroplasty in mild valgus deformities. Int Orthop 40(5):945–951
14. Hungerford DS (2009) Extra-articular deformity is always correctable intra-articularly: to the contrary. Orthopedics 32
15. Tan H, Wang Y, Long T, Nie B, Mao Z, Yue B (2018) How to accurately determine the distal femoral valgus cut angle in the valgus knee arthroplasty. Int Orthop 42(3):537–542
16. Palanisami D, Iyyaampillai G, Shanmugam S, Natesan R, S R (2016) Individualised distal femoral cut improves femoral component placement and limb alignment during total knee replacement in knees with moderate and severe valgus deformity. Int Orthop 40(10):2049–2054
17. Hui C, Salmon LJ, Kok A, Williams HA, Hockers N, van der Tempel WM, Chana R, Pinczewski LA (2011) Long-term survival of high tibial osteotomy for medial compartment osteoarthritis of the knee. Am J Sports Med 39:64–70
18. Loures FB, de Araujo Goes RF, Labronici PJ, Barretto JM, Olej B (2016) Evaluation of body mass index as a prognostic factor in osteoarthrosis of the knee. Rev Bras Ortop 51:400–404
19. Weiss NG, Parvizi J, Hanssen AD, Trousdale RT, Lewallen DG (2003) Total knee arthroplasty in post-traumatic arthrosis of the knee. J Arthroplast 18:23–26
20. Carvalho LH Jr, Castro CAC, Goncalves MBJ, Rodrigues LCM, Cunha FVP, Lopes FL (2005) Range of motion after total knee arthroplasty. Rev Bras Ortop 13:233–234
21. Saleh KJ, Sherman P, Katkin P, Windsor R, Haas S, Laskin R, Sculco T (2001) Total knee arthroplasty after open reduction and internal fixation of fractures of the tibial plateau: a minimum five-year follow-up study. J Bone Joint Surg Am 83-A:1144–1148
22. Radke S, Radke J (2002) Total knee arthroplasty in combination with a one-stage tibial osteotomy: a technique for correction of a gonarthrosis with a severe (>15 degrees) tibial extra-articular deformity. J Arthroplast 17:533–537
23. Czekaj J, Fary C, Gaillard T, Lustig S (2017) Does low-constraint mobile bearing knee prosthesis give satisfactory results for severe coronal deformities? A five to twelve year follow up study. Int Orthop 41(7):1369–1377
24. Saragaglia D, Sigwalt L, Gaillot J, Morin V, Rubens-Duval B, Pailhé R (2018) Results with eight and half-years average follow-up on two hundred and eight e-Motion FP® knee prostheses, fitted using computer navigation for knee osteoarthritis in patients with over ten degrees genu varum. Int Orthop 42(4):799–804
25. Luque R, Rizo B, Urda A, Garcia-Crespo R, Moro E, López-Duran L (2015) Primary modular total knee replacement in severe and unstable osteoarthritis. Predictive factors for failure. Int Orthop 39(11):2125–2133
26. Parratte S, Pagnano MW, Trousdale RT, Berry DJ (2010) Effect of postoperative mechanical axis alignment on the fifteen-year survival of modern, cemented total knee replacements. J Bone Joint Surg Am 92:2143–2149
27. Bottros J, Klika AK, Lee HH, Polousky J, Barsoum WK (2008) The use of navigation in total knee arthroplasty for patients with extra-articular deformity. J Arthroplast 23:74–78
28. Xiao-Gang Z, Shahzad K, Li C (2012) One-stage total knee arthroplasty for patients with osteoarthritis of the knee and extra-articular deformity. Int Orthop 36:2457–2463