Technical Note

Harvest, Transport, and Storage of Fresh Humeral Head Osteochondral Allograft: Step-by-Step Protocol

Rodrigo Souto Borges Petros, M.D., Rafael Augusto Dantas Prinz, M.D., M.Sc., Rodrigo Ribeiro Pinho Rodarte, M.D., M.Sc., Diego Pinheiro Aguiar, Ph.D., and Eduardo Branco de Sousa, M.D., Ph.D.

Abstract: Articular cartilage defects are not common in the glenohumeral joint and are mostly found in patients after shoulder trauma, in patients with recurrent instability, or in patients who underwent previous surgical treatment. Articular cartilage defects lead to pain and loss of motion, consequently causing shoulder function impairment and reducing quality of life. In young patients, the use of osteochondral allografts for the treatment of humeral head defects may avoid well-known complications of shoulder arthroplasty. The goal of this Technical Note is to describe a step-by-step protocol for the harvesting, transport, and preservation of fresh humeral head osteochondral tissue for use in allograft transplantation.

Articular cartilage defects are relatively common in the glenohumeral joint, with rates of around 5% to 17% according to some authors, and are mostly found in patients after shoulder trauma, in patients with recurrent instability, or in patients who underwent previous surgical treatment.[1-3] Hence, diagnosis can be difficult, and defects are frequently found during arthroscopic or open surgical treatment of other diseases.[4]

Focal cartilage defects lead to pain and loss of motion, consequently causing shoulder function impairment and reducing quality of life. Although arthroplasty and humeral head resurfacing techniques are associated with improvement in pain and function, these techniques are more suitable for older and low-demand patients. On the other hand, in younger patients, autologous chondrocyte implantation, osteochondral autograft, and osteochondral allograft are described as treatment options owing to the poorer outcomes of arthroplasty described in this population.[2,3,5] Besides, humeral head reconstruction with osteochondral allografts can improve shoulder range of movement, leading to better functional outcome scores and resulting in lower subsequent dislocation rates.[6,7]

Most literature regarding allografts involves the use of articular cartilage specimens from the knee joint. However, this type of allograft does not seem suitable for reconstruction of the articular surface of the humeral head because of differences in both cartilage thickness and curvature.[4,5] Moreover, there is no consensus in the literature regarding the standardization of a protocol for the harvest, transport, and preservation of humeral osteochondral allografts in tissue banks.[8] So, the goal of this Technical Note is to describe a step-by-step protocol for the harvesting, transport, and preservation of fresh humeral head osteochondral tissue for use in allograft transplantation (Video 1).

Surgical Technique

Tissue Harvesting and Transport

After positive notification by the state's transplant central registry of a viable corpse donor (Table 1), a team (5 doctors and 3 nurses) is dispatched to the

From the Divisão de Ensino e Pesquisa, Instituto Nacional de Traumatologia e Ortopedia Jamil Haddad, São Cristóvão, Brazil (R.S.B.P., R.R.P.R, D.P.A., E.B.d.S.); Área de Transplante de Multitecidos, Instituto Nacional de Traumatologia e Ortopedia Jamil Haddad, São Cristóvão, Brazil (R.S.B.P., R.A.D.P.); and Centro Universitário Estadual da Zona Oeste, Campo Grande, Brazil (D.P.A.).

The authors report no conflicts of interest in the authorship and publication of this article. Full ICMJE author disclosure forms are available for this article online, as supplementary material.

Received February 18, 2021; accepted March 19, 2021.

Address correspondence to Eduardo Branco de Sousa, M.D., Ph.D., Divisão de Ensino e Pesquisa, Instituto Nacional de Traumatologia e Ortopedia Jamil Haddad, Avenida Brasil, 500-9° Andar, CEP 20940-070, Rio de Janeiro (RJ), Brazil. E-mail: eduardobsousa@globo.com

© 2021 THE AUTHORS. Published by Elsevier Inc. on behalf of the Arthroscopy Association of North America. This is an open access article under the CC BY-NC-ND license (http://creativecommons.org/licenses/by-nc-nd/4.0/).

2212-6287/21262

https://doi.org/10.1016/j.eats.2021.03.025

Table 1. Exclusion Criteria for Organ Donation

Group	Criteria
1	Diseases diagnosed or suspected before donation as follows: major burns, malignant neoplasms with potential to metastasize, active tuberculosis, sexually transmitted diseases, malaria, acquired immunodeficiency syndrome, or systemic bacterial or fungal disease diagnosed during hospitalization and sepsis.
2	Behavior or situations in 12 mo preceding donation as follows: contamination by toxic substance; injectable drug use that is illicit or without therapeutic indication; tattoos; acupuncture retouching; definitive makeup and body adornments with no possible evaluation of needle sterilization; dialysis or sexual relations with patients undergoing dialysis; paid sexual relations; multiple sexual partners; male individuals with sexual relations with other male individuals or their female partners; sexual relations with individuals with positive results for HIV, hepatitis B or C, or other blood-transmitted diseases; or detention for >24 h in prison or custodial facility
3	Unable to undergo donation considering the minimal interval required for safety between vaccination date and donation date Minimum 48-h interval: brucellosis, cholera, pertussis cough, diphtheria, typhoid fever (injectable), *Haemophilus influenzae*, hepatitis A, recombinant hepatitis B, leptospirosis, meningitis, bubonic plague, poliomyelitis (Salk), and tetanus Minimum 3-wk interval: BCG, mumps, yellow fever, oral typhoid fever, oral poliomyelitis (Sabin), and measles Minimum 4-wk interval: rubella, varicella, influenza, prophylactic antirabies, and antitetanic serum Minimum 1-yr interval: antirabies after animal exposure, plasma-derived hepatitis B, passive immunotherapy, and vaccines in experimental step
4	Diseases or therapeutics that must be controlled and justified in medical records regarding donor exclusion or not: immunosuppressant treatment; growth hormone treatment; prior organ and tissue transplant at <12 mo, except for dura mater or chemotherapy; chemotherapy or radiotherapy treatment, except for benign lesions; unknown result of surgery; prior biopsy because of cutaneous lesion; or prior transfusion of blood or its derivates at <12 mo, except when source is controlled
5	Specific exclusion criteria under tissue bank criteria: Segment exclusion: trauma with abrasions and major local hematoma or superficial cutaneous infections Whole-limb exclusion: deep venous puncture with infection signs

NOTE. The exclusion criteria are divided into 5 groups according to national regulations. If the corpse donor does not fulfill any of the criteria, serologic testing is performed and then harvest begins.

BCG, bacillus Calmette-Guérin vaccine; HIV, human immunodeficiency virus.

hospital where the donor's death occurred. On arrival, the team prepares the body for the removal of all bone tissue (Table 2), in the supine position, and collects blood for serologic testing (between 72 hours before and 6 hours after circulation arrest at room temperature; if the corpse is refrigerated, between 2°C and 8°C, up to 24 hours after circulation arrest). Detergent chlorhexidine is used to perform asepsis, and alcoholic chlorhexidine is used for antisepsis. The surgical drapes are then placed.

Table 2. Routine Harvesting Protocol According to Donor Age

Donor Age, yr	Harvesting Protocol
10-70	Bone is collected bilaterally from the femur, tibia, fibula, talus, iliac crest, proximal humerus, radius, and ulna, as well as lumbar vertebrae.
18-55	Besides bone, tendons are bilaterally collected: knee extensor mechanism with patella, Achilles tendon with bone plug, semitendinosus tendon, gracilis tendon, tibialis anterior tendon with bone plug, tibialis posterior tendon, flexor hallucis longus tendon, flexor carpi radialis tendon, and flexor digitorum superficialis and profundus tendons.
15-45	Besides bone and tendons, osteochondral tissue is collected.

NOTE. The harvesting protocol depends on the donor age. Bone is collected in patients aged 10 to 70 years. In patients aged between 18 and 55 years, bone and tendons are collected. Moreover, in patients aged between 15 and 45 years, bone, tendons, and osteochondral tissue are collected. Other tissues can be harvested depending on requests made by the orthopaedic division to the tissue bank.

The surgical technique for harvesting osteochondral tissue from the proximal humerus consists of performing the deltopectoral approach, using the coracoid process and the lateral surface of the humerus as anatomic references (Fig 1A). After skin incision, the deltoid and pectoralis major muscles are shifted laterally and medially, respectively. To improve visualization, a pectoralis major tenotomy is performed, and the deltoid muscle is detached from the lateral and posterior surfaces of the humerus with the aid of a surgical remover; 24-cm Hohmann surgical retractors may also be used to facilitate exposure.

Tenotomy of the subscapularis is performed at its insertion on the humeral lesser tuberosity. It is extremely important to avoid damaging the articular cartilage in this step. External rotation of the upper limb helps decrease this risk and increases surgical exposure. In this step, the axillary vessels and nerve, which pass inferior to the subscapularis muscle, are sectioned. The teres major tendon is also detached from the crest of the humeral lesser tuberosity. The rotator interval is opened, with tenotomy of the long head of the biceps, in the region of the supraglenoid tubercle. To facilitate exposure, tenotomy of the supraspinatus, infraspinatus, and teres minor tendons is performed under internal rotation of the upper limb, with extreme care taken not

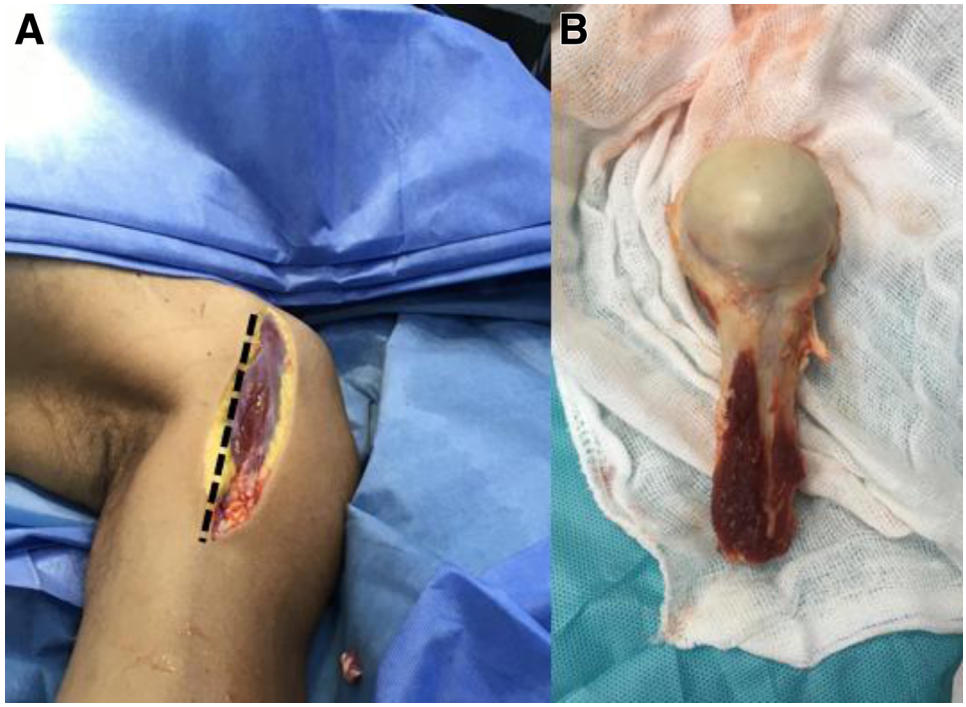

Fig 1. Surgical technique for harvesting osteochondral tissue from proximal humerus. (A) For harvesting, patient is placed supine, and the deltopectoral approach is performed (in the example, in the left shoulder), using the coracoid process and the lateral surface of the humerus as anatomic references (dashed line). (B) After completion of the osteotomy with the aid of a clamp, proximal humerus piece elevation and opening of the whole posterior and inferior capsule are performed, with removal of remaining muscle until complete release of the piece.

to damage the humeral articular cartilage. At the posterior humeral surface, the origin of the triceps muscle lateral head is sectioned.

A reciprocating saw and a bone clamp are used in the resection of the proximal humeral extremity, which is performed 10 to 15 cm below the humeral greater tuberosity (Fig 1B). After osteotomy with the aid of the clamp, proximal humeral piece elevation and opening of the whole posterior and inferior capsule are performed, with removal of remaining muscle until complete release of the piece. Two tissue samples are taken at this time and stored in a container at a controlled temperature (4°C) for microbiological analysis (fungi and aerobic bacteria) in the tissue bank.

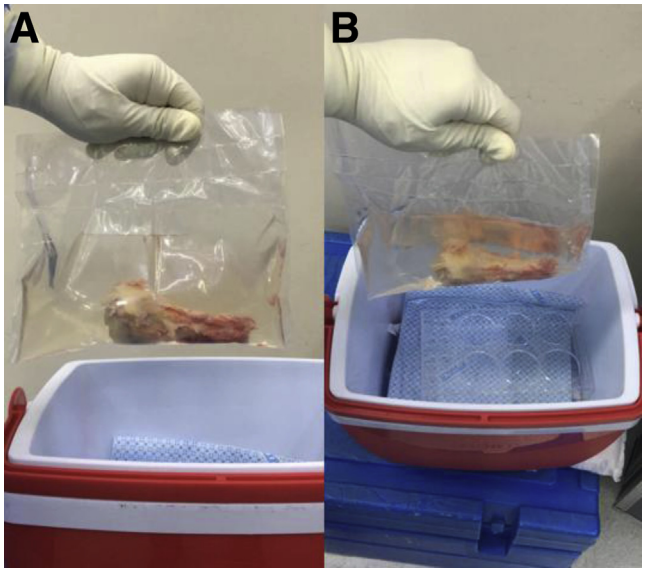

Fig 2. Graft accommodation for transport to tissue bank. (A, B) Packages containing the tissue are stored in a container at a controlled temperature (4°C) and sent for processing at the tissue bank.

The humeral proximal extremity is placed in 0.9% saline solution and stored in triple sterile plastic packing, which is appropriately sealed and contains the corpse donor identification number and initials, tissue identification with laterality, and harvesting date. Packages are stored in a container at a controlled temperature (4°C) and sent for processing at the tissue bank (Fig 2). The container inner temperature must be registered during tissue placement and removal for storage in the tissue bank refrigerator at 4°C. After removal of the humeral proximal extremity, the corpse donor body is recomposed, resembling natural anatomy, using polyvinyl chloride pipes or broomsticks, which are fixed to the glenoid with crossed Kirschner wires and covered with compresses before wound closure.

Tissue Reception and Storage

On arrival in the tissue bank facility, corpse donor data (name, harvesting date, and amount and type of tissue harvested) are registered. All legal documentation must be checked at this moment. When tissue is

Fig 3. Tissue storage for processing. On arrival in the tissue bank facility, corpse donor data (name, harvesting date, and amount and type of tissue harvested) are registered and checked. In the meantime, tissue is stored in the tissue-reception refrigerator at 4°C until processing.

removed from the transport container, the temperature and weight are measured and visual analysis of the packages is performed; these data are registered on the identification tag, which is sealed with the package. The tissue is then stored in the "tissue-reception refrigerator" at 4°C until processing (Fig 3). The samples collected during harvest are sent for microbiological analysis.

In the next step, the proximal humeral extremity undergoes radiologic screening. The tissue package is transported to the radiology unit in the same container at a controlled temperature. After radiographs are obtained, the tissue is transported back to the tissue bank and is stored in the tissue-reception refrigerator. The radiographic report is evaluated by the physician responsible for the tissue bank, who defines whether the tissue is adequate to continue processing.

Osteochondral Tissue Processing

Tissue processing is performed in an ISO class 5 room (Fig 4) located within the tissue bank by a member of the staff as soon as the team arrives in the facility. Processing is performed in a sterile room with negative pressure, organized using 3 tables. On the first table, 2 sterile flasks are prepared for before and after lavage (Fig 5A). All surgical instruments are positioned on the second table, such as clamps, scalpels, sterile drapes, syringes, oscillatory saws, batteries, and a lathe (Fig 5B). Finally, the third table is prepared with the sealer, scale, culture medium, and packages (Fig 5C).

The next step consists of cleaning plus removal of muscle and bone tissue not necessary for the transplant procedure and visual evaluation, with exclusion in the case of any articular cartilage injury. The first step of processing begins with the opening of 2 of the 3 sterile packages containing the tissue on the first table (Fig 6A). The physician responsible for processing catches the inner package, which is the most sterile, with a surgical clamp. The package is opened in a sterile (pre-lavage) flask. In this step, samples of the solution in which the tissue was immersed since harvesting are collected for microbiological analysis (fungi and anaerobic and aerobic bacteria) in culture flasks.



Fig 4. Tissue bank facility. (A-C) Tissue processing is performed in an ISO class 5 room, in a sterile manner and with negative pressure, located within the tissue bank.



Fig 5. Tissue processing organization. The room for tissue processing is organized using 3 tables to facilitate the procedure. (A) On the first table, 2 sterile flasks are prepared for before lavage (black arrow) and after lavage (white arrow). (B) All surgical instruments are positioned on the second table, such as clamps, scalpels (black arrow), sterile drapes, syringes, oscillatory saws, batteries (black circle), and a lathe (white arrow). (C) The third table is prepared with the sealer (white arrow), scale (black arrow), culture medium, and packages (black circle).

On the second table, tissue is fixed in a conventional lathe. Skeletonization begins with the removal of all remaining muscular and tendinous insertions (Fig 6 B and C), using scalpels and mechanical saws, leaving the proximal third of the humerus with only cartilage and bone (Fig 6D). During this step, it is important to make a few pauses to irrigation of the tissue with the prelavage solution to minimize damage to the humeral cartilage due to the heat caused by the mechanical saw. At the end of this step, a tissue fragment is collected for histopathologic evaluation (Fig 6E).

In the sequence, the tissue returns to the first table for continuous lavage with 0.9% saline solution in a second (post-lavage) flask. Three samples of this solution are collected for microbiological analysis (fungi and anaerobic and aerobic bacteria) in culture flasks (Fig 7A). Then, the tissue is dried with sterile compresses and transported to the third table, on which osteochondral tissue is measured with a graduated scale (Fig 7B). Tissue weighing is performed on a digital scale. After measurements, osteochondral tissue is stored in a sterile plastic package (internal package) containing the preservation medium, composed of Iscove's cell culture medium without serum (Thermo Fisher Scientific, Waltham, MA) supplemented with 10% human albumin and vancomycin, 100 μg/mL, to reduce the risk of chondrocyte death (Fig 7C). Double and triple sterile package sealing is then performed. Double package sealing, in this step, is not easy because of the tissue size and owing to the preservation medium, which sometimes leaks, making adequate sealing more difficult.

Processed tissue is stored in the "quarantine refrigerator" until the results of all the microbiological and histopathologic tests are known (Fig 8). In the case of positive culture findings, the tissue is discarded. If findings are negative, tissue is ready for transplant and the patient's surgery can be scheduled. All data are



Fig 6. Tissue processing step-by-step: part 1. (A) Processing begins with the opening of 2 of the 3 sterile packages containing the tissue. (B, C) The tissue is fixed in a conventional lathe; then, skeletonization begins with removal of all remaining muscular and tendinous insertions. (D) The proximal third of the humerus is left with only cartilage and bone. (E) A tissue fragment is collected for histopathologic evaluation.

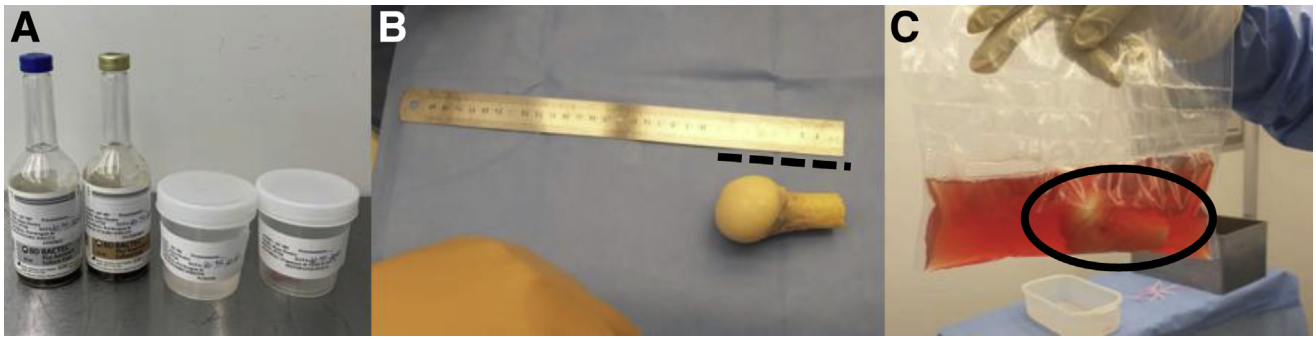

Fig 7. Tissue processing step-by-step: part 2. (A) The tissue undergoes continuous lavage with 0.9% saline solution in a second (post-lavage) flask, and samples of this solution are collected for microbiological analysis in culture flasks. (B) Osteochondral tissue is measured with a graduated scale (dashed line). (C) After measurements, osteochondral tissue is stored in a sterile plastic package containing the preservation medium (oval).

recorded in the corpse donor files and in the host patient files. Table 3 presents pearls and pitfalls regarding humeral head graft harvesting and processing.

Fig 8. Tissue quarantine after processing. Processed tissue is stored in the quarantine refrigerator until the results of all the microbiological and histopathologic tests are known.

Osteochondral Tissue Transplantation Planning

Host osteochondral lesions are diagnosed by standard radiographs of the shoulder and computed tomography (CT). The goal of CT is to measure the size of the humeral head cartilage defect, besides identifying the absence of a posterior glenoid border fracture or bone avulsion of the infraspinatus or supraspinatus tendon. Axial CT images are obtained immediately below the coracoid process. A circle is positioned over the humeral head; a line is then drawn from the lesser tuberosity to the posterior margin of the cartilage adjacent to the infraspinatus insertion, and a second line is drawn tangent to the defect region toward the anterior line. The angle between these lines is denominated the defect angle (Fig 9). On the basis of the defect size, the size of the humeral head allograft can be determined.

On the surgery date, osteochondral allograft is transported in a cooled container at 4°C and removed from the package only at the moment of transplant (Fig 10A). At the time of surgery, an osteotomy is performed in the anatomic humeral neck of the graft for isolation of the fresh humeral head osteochondral allograft (Fig 10B), which is adapted for transplantation and filling of the cartilage defect, restoring the spherical humeral head anatomy (Fig 10C).

Discussion

Owing to poorer long-term results of arthroplasty in young patients, alternative techniques that can be applied to patients younger than 50 years who present with major humeral head chondral lesions have been studied to restore the articular surface anatomy in a biological way using restorative techniques such as the fresh osteochondral allograft transplantation.[9] Osteochondral allografts are similar to autografts and present the advantages of a shorter surgical time, lower harvest-associated morbidity, and the possibility of treating lesions larger than 2 cm.[2].

Table 3. Pearls and Pitfalls

Pearls	Pitfalls
During subscapularis tenotomy, external rotation of the upper limb should be performed.	There is a risk of articular cartilage damage and limited surgical exposure during harvesting.
One should perform tenotomy of the supraspinatus, infraspinatus, and teres minor tendons under internal rotation during harvesting.	There is a risk of damage to humeral articular cartilage during osteochondral tissue harvesting.
After dissection of the shoulder and arm, one should open the shoulder capsule and remove the proximal third of the humerus, separated from the scapula and clavicle.	Differently from the approach in the knee, in which the joint is collected without opening the joint capsule, this approach is not viable in the shoulder owing to the need to remove a substantial amount of the scapula. Achieving this would be extremely difficult, increasing the harvesting time and the risk of contamination. Besides, the supine positioning of the donor corpse necessary for the remaining procedures makes the approach for the scapula difficult. Finally, removal of the scapula would lead to unsatisfactory reconstruction of the donor corpse esthetics, leading to family disapproval.
Partial sealing should be performed before filling the inner package with medium, leaving a small aperture. Then, the package is filled with medium with the aid of a funnel, which is removed, allowing double sealing of this small aperture.	During processing, double package sealing is more difficult because of the tissue size and the preservation medium, which sometimes leaks.

The harvesting procedure requires a corpse donor and fitting of the articular geometry of the graft to the patient.[10]

Osteochondral allografts can be fresh, when stored at 4°C, or frozen, when stored at −80°C. Frozen grafts at −80°C lead to a considerable reduction of the host immune response while preserving the biomechanical properties, although chondrocyte viability significantly decreases over time.[11] Fresh osteochondral allografts refer to tissue harvested 24 hours after donor death and stored, almost aseptically, in a refrigerator at 4°C, until microbiological tests are performed to allow the transplant. This type of graft presents, as its main advantage, the fact that it contains hyaline cartilage with subchondral bone support, as well as viable chondrocytes at higher numbers.[12-14] However, fresh osteochondral allograft viability decreases over time[14,15] and with the medium used for storage.[11]

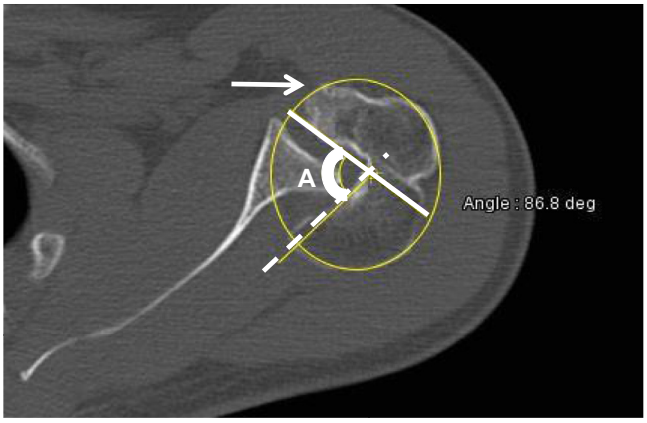

Fig 9. Calculation of host defect size. The size of the humeral head cartilage defect is measured on axial computed tomography images obtained immediately below the coracoid process. A circle is positioned over the humeral head (white arrow); a line (solid white line) is then drawn from the lesser tuberosity to the posterior margin of cartilage adjacent to the infraspinatus insertion, and a second line (dashed white line) is drawn tangent to the defect region toward the anterior line. The angle between these lines (A) is denominated the defect angle, which is used to calculate the size of the allograft to be transplanted.

Preservation of human osteochondral allografts has previously been studied for the treatment of knee lesions.[16,17] Regarding the shoulder, few studies have evaluated the use of osteochondral allografts for treating humeral head articular cartilage lesions.[7] The few existing reports have mainly described the use of frozen allografts,[7,18,19] whereas studies involving the use of fresh allografts are scarce.[20,21] Those studies, however, although rare, have presented promising results regarding the use of this type of graft, showing good functional results, pain improvement, and no complications. When chondrocytes remain viable during storage, they maintain matrix integrity and, so, the graft properties.[8] Besides, long-term allograft transplant survival depends on graft chondrocyte viability, on matrix maintenance, and on the graft incorporation to host bone.[8,22-24] Table 4 presents the advantages, disadvantages, and risks of the described technique. On the basis of this report, as described in this protocol, after adequate harvesting, transport, and storage, fresh humeral head osteochondral allograft is an adequate option for the treatment of patients with massive proximal humeral chondral lesions.

Acknowledgment

The authors thank "Ministério da Saúde" for the support.

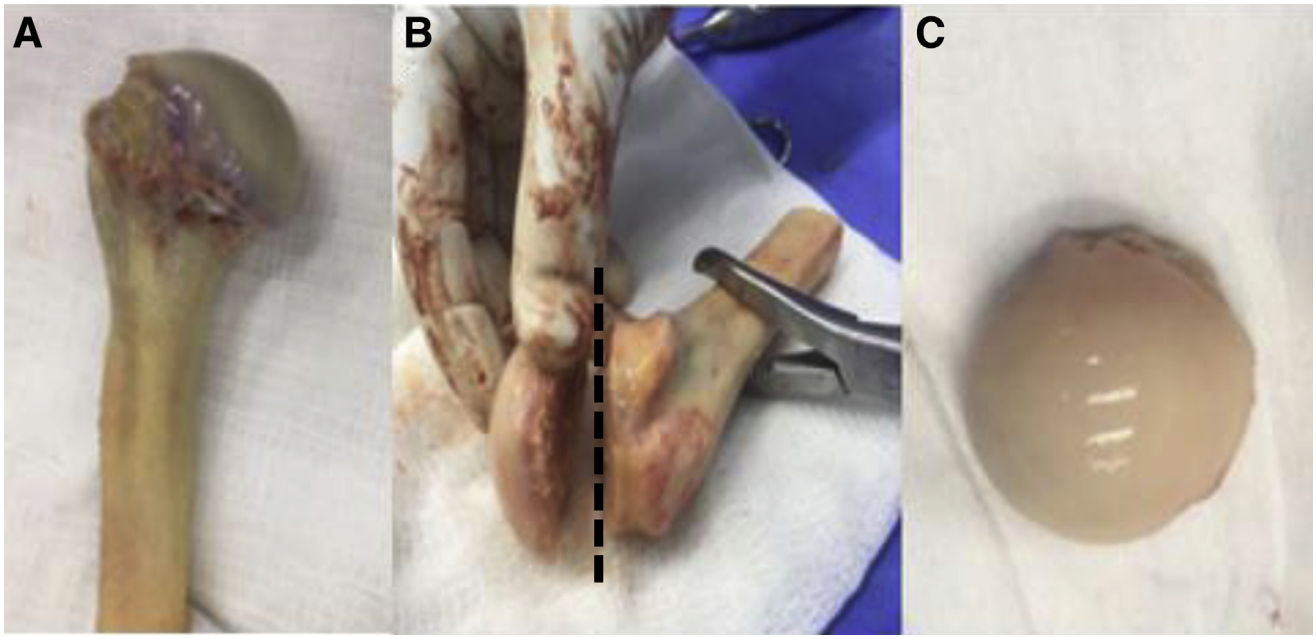

Fig 10. Preparation of osteochondral graft for transplantation. (A) The proximal third of the humerus is removed from the package only at the moment of transplant. An osteotomy is performed in the anatomic humeral neck of the graft for isolation of the fresh humeral head osteochondral allograft (dashed line) (B) and adapted for transplantation and filling of the cartilage defect, restoring the spherical humeral head anatomy (C).

Table 4. Advantages, Disadvantages, and Risks

Advantages
Biological reconstruction of humeral head
High preservation rates of viable hyaline cartilage
Good functional results and pain improvement in young persons
High rates of osseointegration
Disadvantages
Active activity restriction until osteochondral tissue osseointegration
Limited availability in some regions of country
Postoperative precautions owing to opening of subscapularis
Risks
Risk of chondrolysis because of use of hardware
Risk of graft resorption
Risk of graft-versus-host disease
Low but existing risk of allograft disease transmission

References

1. Bhatia S, Hsu A, Lin EC, et al. Surgical treatment options for the young and active middle-aged patient with glenohumeral arthritis. *Adv Orthop* 2012;2012:1-8.
2. Capito NM, Owens BD, Sherman SL, Smith MJ. Osteochondral allografts in shoulder surgical procedures. *JBJS Rev* 2016;15:4.
3. Riff AJ, Yanke AB, Shin JJ, Romeo AA, Cole BJ. Midterm results of osteochondral allograft transplantation to the humeral head. *J Shoulder Elbow Surg* 2017;26:e207-e215.
4. Sedil AJ, Kraeutler MJ. Management of articular cartilage defects in the glenohumeral joint. *J Am Acad Orthop Surg* 2018;26:e230-e237.
5. Provencher MT, Sanchez G, Schantz K, et al. Anatomic humeral head reconstruction with fresh osteochondral talus allograft for recurrent glenohumeral instability with reverse Hill-Sachs lesion. *Arthrosc Tech* 2017;6:e255-e261.
6. Wang KC, Waterman BR, Cotter EJ, Frank RM, Cole BJ. Fresh osteochondral transplantation for focal chondral defect of the humerus associated with anchor arthropathy and failed SLAP repair. *Arthrosc Tech* 2017;6:e1443-e1449.
7. Saltzman BM, Riboh JC, Cole BJ, Yanke AB. Humeral head reconstruction with osteochondral allograft transplantation. *Arthroscopy* 2015;31:1827-1834.
8. Beer AJ, Tauro TM, Redondo ML, Christian DR, Cole BJ, Frank RM. Use of allografts in orthopaedic surgery: Safety, procurement, storage, and outcomes. *Orthop J Sports Med* 2019;7. 2325967119891435.
9. Harb A, Von Horn A, Gocalek K, et al. Lactated Ringer-based storage solutions are equally well suited for the storage of fresh osteochondral allografts as cell culture medium-based storage solutions. *Injury* 2017;48:1302-1308.
10. Torrie AM, Kesler WW, Elkin J, Gallo RA. Osteochondral allograft. *Curr Rev Musculoskelet Med* 2015;8:413-422.
11. Ball ST, Amiel D, Williams SK, et al. The effects of storage on fresh human osteochondral allografts. *Clin Orthop Relat Res* 2004;418:246-252.
12. Tschon M, Veronesi F, Giannini S, Fini M. Fresh osteochondral allotransplants: Outcomes, failures, and future developments. *Injury* 2017;48:1287-1295.
13. Stoker AM, Stannard JP, Kuroki K, Bozynski CC, Pfeiffer FM, Cook JL. Validation of the Missouri Osteochondral Allograft Preservation System for the maintenance of osteochondral allograft quality during prolonged storage. *Am J Sports Med* 2018;46:58-65.

14. Bruns J, Werner M, Habermann C. Osteochondritis dissecans: Etiology, pathology, and imaging with a special focus on the knee joint. *Cartilage* 2018;9:346-362.
15. Cinats D, Miller S, Abusara Z, et al. Evolution of a novel tissue preservation protocol to optimize osteochondral transplantation outcomes. *Cartilage* 2021;12:31-41.
16. De Sousa EB, Aguiar DP, Barcelos JF, Duarte MEL, Olej B. Approaches to preserve human osteochondral allografts. *Cell Tissue Bank* 2015;16:425-431.
17. Vivacqua TA, Prinz RD, Cavanellas N, Barreto JM, de Sousa EB, Aguiar DP. Protocol for harvest, transport, and storage of human osteochondral tissue. *Rev Bras Ortop* 2020;55:163-169.
18. Gerber C, Lambert SM. Allograft reconstruction of segmental defects of the humeral head for the treatment of chronic locked posterior dislocation of the shoulder. *J Bone Joint Surg Am* 1996;78:376-382.
19. Snir N, Wolfson TS, Hamula MJ, Gyftopoulos S, Meislin RJ. Arthroscopic anatomic humeral head reconstruction with osteochondral allograft transplantation for large Hill-Sachs lesions. *Arthrosc Tech* 2013;2:e289-e293.
20. Black LO, Ko JWK, Quilici SM, Crawford DC. Fresh osteochondral allograft to the humeral head for treatment of an engaging reverse Hill-Sachs lesion: Technical case report and literature review. *Orthop J Sports Med* 2016;4:1-5.
21. Proencher MT, Leclere LE, Ghodadra N, Solomon DJ. Postsurgical glenohumeral anchor arthropathy treated with a fresh distal tibia allograft to the glenoid and a fresh allograft to the humeral head. *J Shoulder Elbow Surg* 2010;19:e6-e11.
22. Krych AJ, Saris DBF, Stuart MJ, Hacken B. Cartilage injury in the knee: Assessment and treatment options. *J Am Acad Orthop Surg* 2020;28:914-922.
23. De Caro F, Bisicchia S, Amendola A, Ding L. Large fresh osteochondral allografts of the knee: A systematic clinical and basic science review of the literature. *Arthroscopy* 2015;31:757-765.
24. Schreiner AJ, Stocker AM, Bozynski CC, Kuroki K, Stannard JP, Cook JL. Clinical application of the basic science of articular cartilage pathology and treatment. *J Knee Surg* 2020;33:1056-1068.