ELSEVIER

RBO REVISTA BRASILEIRA DE ORTOPEDIA

www.rbo.org.br

Case report

Parosteal aneurysmal bone cyst☆

Walter Meohas, Ana Cristina de Sá Lopes, João Victor da Silveira Möller, Luma Duarte Barbosa, Marcelo Bragança dos Reis Oliveira*

Instituto Nacional de Traumatologia e Ortopedia (Into), Rio de Janeiro, RJ, Brazil

ARTICLE INFO

Article history:
Received 4 June 2014
Accepted 23 October 2014
Available online 1 September 2015

Keywords:
Aneurysmal bone cyst
Calcitonin
Corticosteroids
Infiltration

ABSTRACT

The incidence of aneurysmal bone cysts is 0.14 cases per 100,000 individuals. Parosteal aneurysmal bone cysts are the least prevalent subtype and represent 7% of all aneurysmal bone cysts. We present the case of a 38-year-old male patient with pain and bulging in his right arm for eight months. He had previously been diagnosed as presenting giant-cell tumor, but his slides were reviewed and his condition was then diagnosed as parosteal aneurysmal bone cyst. The patient was treated with corticosteroid and calcitonin infiltration into the lesion and evolved with clinical and radiological improvement within the first five weeks after the operation.

© 2015 Sociedade Brasileira de Ortopedia e Traumatologia. Published by Elsevier Editora Ltda. All rights reserved.

Cisto ósseo aneurismático parosteal

Palavras-chave:
Cisto ósseo aneurismático
Calcitonina
Corticosteroides
Infiltração

RESUMO

O cisto ósseo aneurismático tem uma incidência de 0,14 a cada 100 mil indivíduos. O subtipo parosteal é o menos prevalente, representa 7% de todos. Apresentamos um paciente masculino, 38 anos, com dor e abaulamento em braço direito havia oito meses. Diagnosticado previamente como tumor de células gigantes, teve sua lâmina revisada e então foi feito o diagnóstico de cisto ósseo aneurismático parosteal. O paciente foi tratado com infiltração intralesional de corticosteroide e calcitonina e evoluiu com melhoria clínica e radiológica já nas primeiras cinco semanas pós-operatórias.

© 2015 Sociedade Brasileira de Ortopedia e Traumatologia. Publicado por Elsevier Editora Ltda. Todos os direitos reservados.

☆ Work performed at the Instituto Nacional de Traumatologia e Ortopedia (INTO), Rio de Janeiro, RJ, Brazil.

* *Corresponding author.*
E-mails: joao_moller@hotmail.com, joaomoller@gmail.com (J.V. da Silveira Möller).

http://dx.doi.org/10.1016/j.rboe.2015.08.008

2255-4971/© 2015 Sociedade Brasileira de Ortopedia e Traumatologia. Published by Elsevier Editora Ltda. All rights reserved.

Introduction

Aneurysmal bone cysts were first described by Jaffe and Lichtenstein in 1942.[1] They account for 1–2% of all primary bone tumors and affect the metaphyseal region of long bones in children, adolescents and young adults.[2,3]

This lesion typically develops inside bones.[4] Cysts located in the cortical bone are rare and account for 7–9.3% of all aneurysmal bone cysts.[5,6]

Few cases have been reported in the literature. The approach used is individualized and varies according to the experience of each service. We present a case of parosteal aneurysmal bone cyst that was treated in accordance with our experience.

Case report

The patient was a 38-year-old man of mixed race with a complaint of pain and bulging in his right arm. It was of progressive nature and the patient had had the complaint for at least eight months. He said that he had not suffered any trauma or undergone previous surgery.

The patient, who had been attended previously at another service, underwent a biopsy from which the histopathological diagnosis was compatible with a giant-cell tumor. When he arrived at our service, because of the clinical and radiological characteristics of the slides (Figs. 1–4), a review of them was requested.

This review showed the presence of a lesion formed by cyst membranes that sometimes showed complete septation constituted by fusiform and multinucleated giant cells. Bone trabeculae dissociated by connective tissue were noted, along with neoformed bone trabeculae of reactive pattern, which led to the diagnosis of parosteal aneurysmal bone cyst.

Infiltration into the lesion using calcitonin and corticosteroid was indicated after reaching a group decision. In the fifth postoperative week, the lesion was already seen to be undergoing an ossification process (Fig. 5).

Discussion

Aneurysmal bone cysts were first described by Jaffe and Lichtenstein in 1942. According to the World Health Organization, they are characterized as benign cystic bone lesions composed of bone voids that are filled with blood and separated by septa of connective tissue containing fibroblasts, osteoclastic giant cells and reactive bone tissue.[1–3,7]

These cysts account for 1–2% of all primary bone tumors and their incidence is 0.14 per 100,000 individuals.[8] The lesions affect the metaphyseal region of the long bones of children, adolescents and young adults.[2,3]

The lesions generally develop inside bones and cause thinning of the cortex and possibly bone protrusion.[4] Localized cysts in the cortical bone are rare and were previously named subperiosteal giant cells or subperiosteal osteoclasis.[4] In 1950, Lichtenstein[9] published an article that elucidated and differentiated parosteal aneurysmal bone cysts from

Fig. 1 – Radiographs of the right humerus in anteroposterior and lateral view.

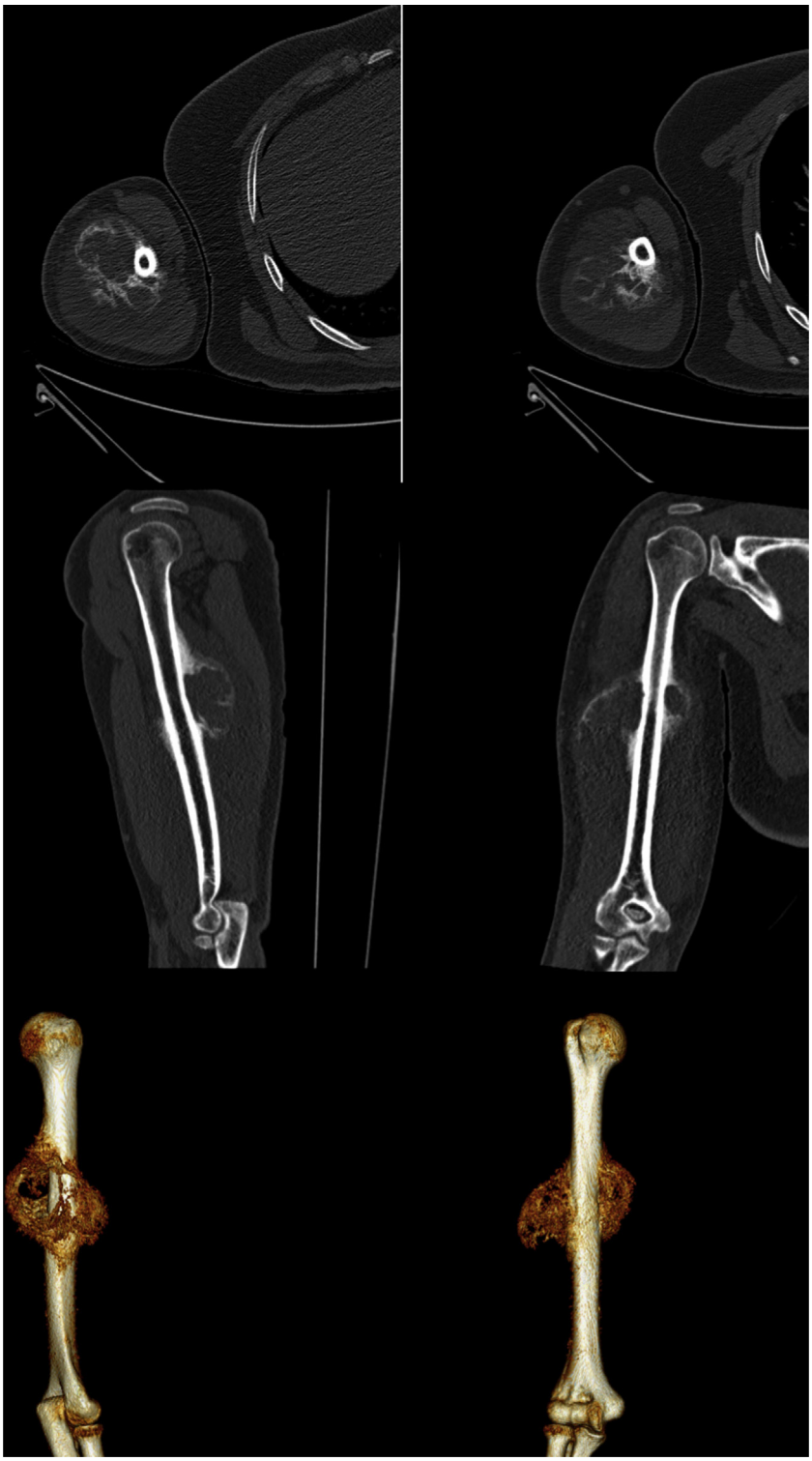

Fig. 2 – Tomographic features.

subperiosteal giant cells, hemangiomas and osteogenic sarcomas.

In 1957, Sherman and Soong[5] classified aneurysmal bone cysts into three types: eccentric, parosteal and central. The parosteal subtype is the least frequent subtype, accounting for 7–9.3% of all aneurysmal bone cysts.[5,6]

Pain is the most prevalent symptom, and its duration may be weeks to months.[2] Radiographically, these cysts present as single eccentric and insufflative lesions that reach the periosteum and have well-defined margins.[2,3] Their presence may be associated with onion-skin periosteal reactions and Codman's triangle.[2,6]

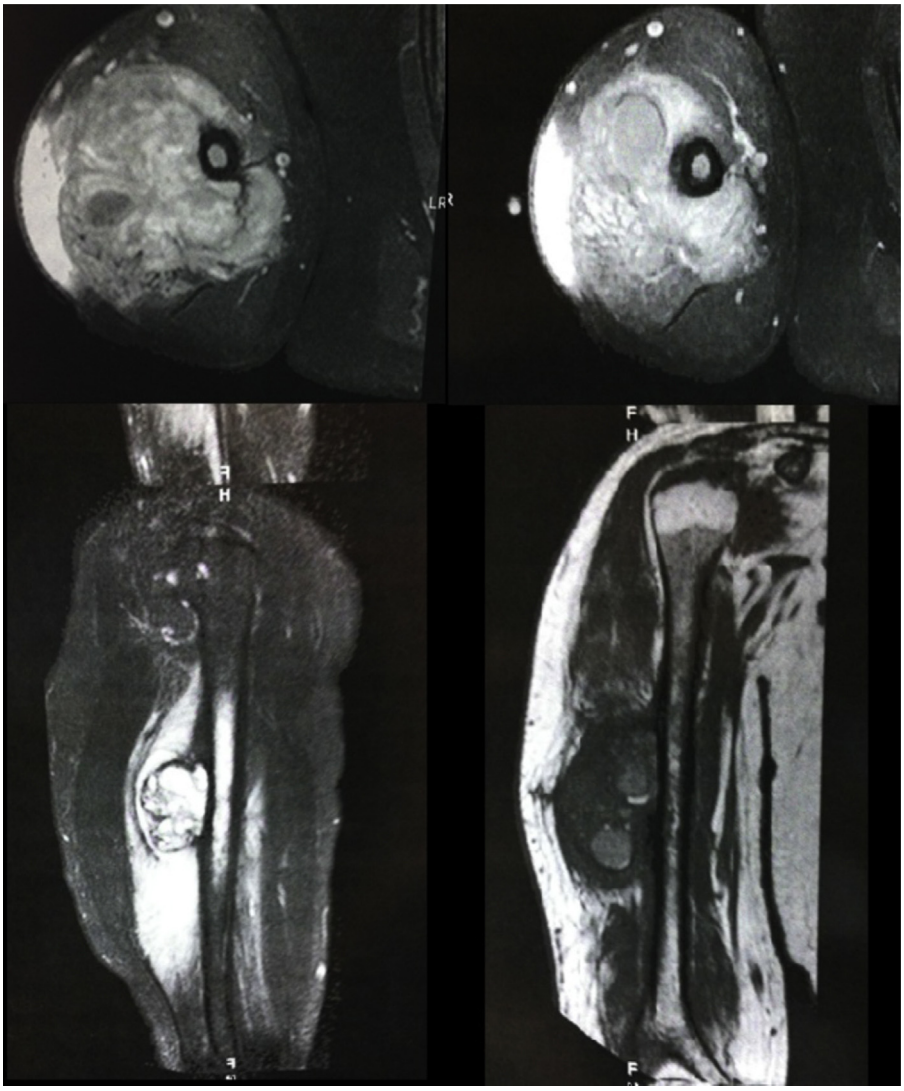

Fig. 3 – Magnetic resonance.

Tomography helps in making the differential diagnosis of these lesions. They show liquid density and may clearly demonstrate the liquid levels.[2,6] Scintigraphy shows that there is greater uptake at the periphery of the lesion.[2] In magnetic resonance imaging, the lesion is well defined, with lobulated outlines and liquid levels.[2]

The histology of aneurysmal bone cysts is characterized by voids filled with blood. These voids are covered by a single layer of undifferentiated cells. The solid tissue surrounding the lesion is composed of richly vascularized fibrosis.[2] Diagnostic differentiation between giant-cell tumors and osteosarcoma with telangiectasia is anatomopathologically complex.[2]

Because these are aggressive lesions, the treatment consists of curettage, with or without subsequent adjuvants such as bone grafts, bone marrow aspirate, cryotherapy, argon, phenol or calcitonin with corticosteroid injection into the lesion.[7,10] In our service, use of corticosteroids in association with calcitonin, injected into the lesion, is the preferred method for treating this type of lesion. Cases of resolution of lesions after an episode of fracturing or after a biopsy, or even spontaneously, have been described.[7,8] Lesion recurrence is associated with young patients, previous aneurysmal bone cysts, location adjacent to a joint or growth plate, low mitotic count and presence of other open growth plates.[8]

Here, we presented a rare case of parosteal aneurysmal bone cyst in which the clinical, radiological and anatomopathological findings and presence of a multidisciplinary team were essential in order to completely elucidate the diagnosis.

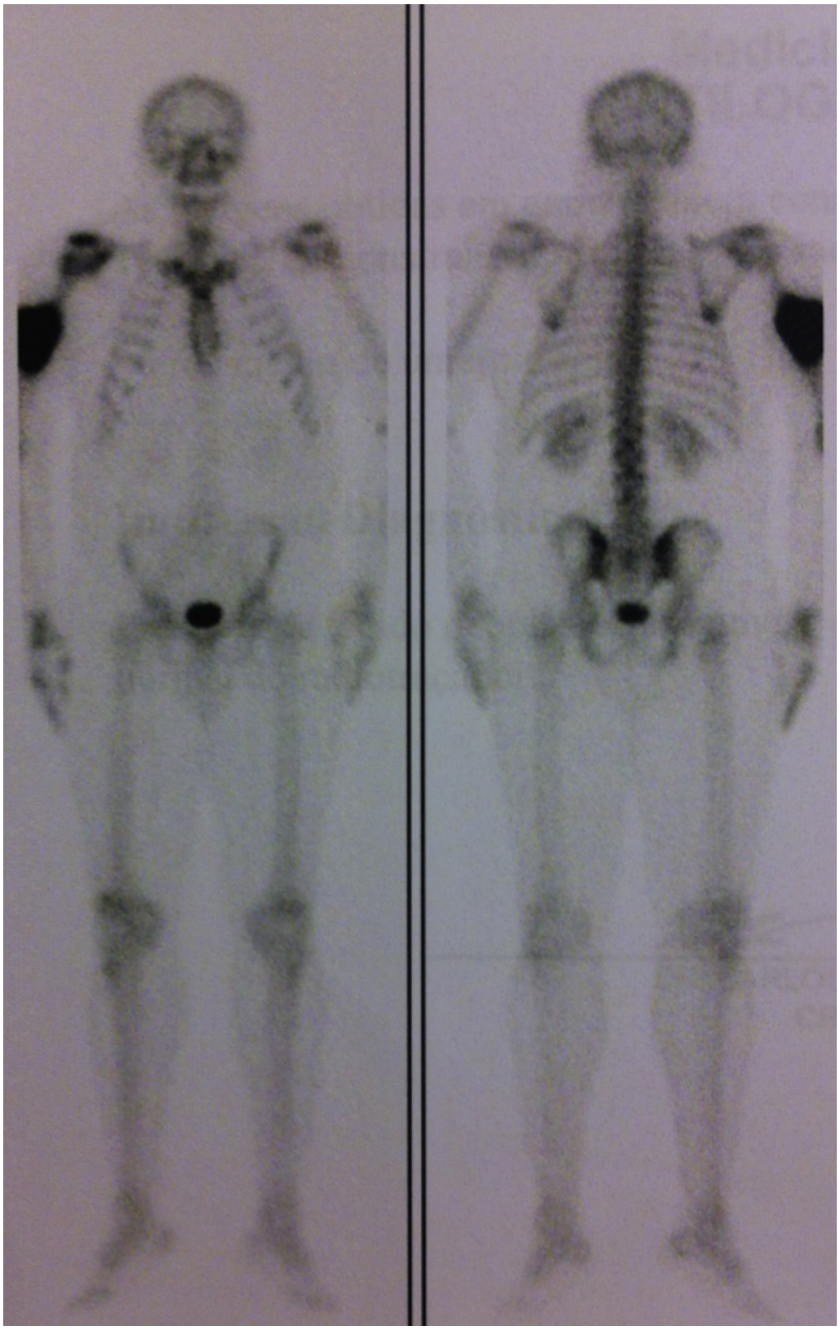

Fig. 4 – Bone scintigraphy.

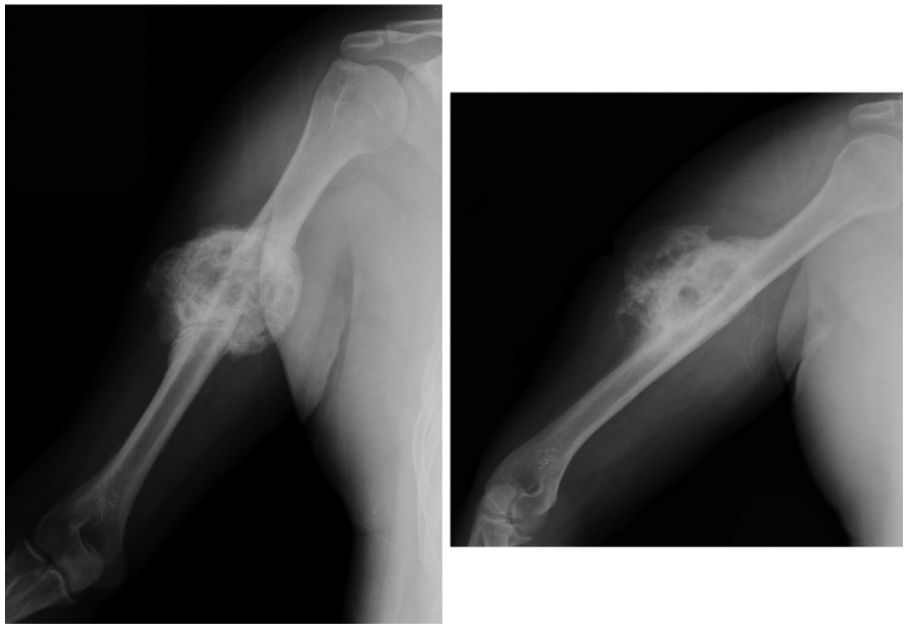

Fig. 5 – Postoperative radiographs.

Conflicts of interest

The authors declare no conflicts of interest.

REFERENCES

1. Jaffe HL, Lichtenstein L. Solitary unicameral bone cyst: with emphasis on the roentgen picture. The pathologic appearance and the pathogenesis. Arch Surg. 1942;44(6):1004–25.
2. Jesus-Garcia R. Diagnóstico e tratamento de tumores ósseos. 2nd ed. Rio de Janeiro: Elsevier; 2013.
3. Pietschmann MF, Oliveira AM, Chou MM, Ihrler S, Niederhagen M, Baur-Melnyk A, et al. Aneurysmal bone cysts of soft tissue represent true neoplasm. A report of two cases. J Bone Joint Surg Am. 2011;93(45):1–8.
4. Kobayashi S, Hayakawa K, Takeno K, Baba H, Meir A. Parosteal aneurysmal bone cyst of the humerus with birdcage-like ossification on three-dimensional CT scanning: a case report. Joint Bone Spine. 2009;76(6):705–7.
5. Sherman RS, Soong KY. Aneurysmal bone cyst: its roentgen diagnosis. Radiology. 1957;68(1):54–64.
6. De Dios AMV, Bond JR, Shives TC, McLeod RA, Unni KK. Aneurysmal bone cyst. A clinicopathologic study of 238 cases. Cancer. 1992;69(12):2921–31.
7. Reddy KIA, Sinnaeve F, Gaston CL, Grimer RJ, Carter SR. Aneurysmal bone cysts: do simple treatments work? Clin Orthop Relat Res. 2014;472(6):1901–10.
8. Steffner RJ, Liao C, Stacy G, Atanda A, Attar S, Avedian R, et al. Factors associated with recurrence of primary aneurysmal bone cysts: is argon beam coagulation an effective adjuvant treatment? J Bone Joint Surg Am. 2011;93(21):e1221–9.
9. Lichtenstein L. Aneurysmal bone cyst: a pathological entity commonly mistaken for giant cell tumor and occasionally for hemangioma and osteosarcoma. Cancer. 1950;3(2):279–89.
10. Docquier PL, Dellove C. Treatment of aneurysmal bone cysts by introduction of demineralized bone and autogenous bone marrow. J Bone Joint Surg Am. 2005;87(10):2253–8.