REV BRAS ORTOP. 2017;52(S1):63–68

SOCIEDADE BRASILEIRA DE ORTOPEDIA E TRAUMATOLOGIA

RBO REVISTA BRASILEIRA DE ORTOPEDIA

www.rbo.org.br

Technical note

Posterior sacroiliac osteotomy: an alternative to the ilioinguinal approach for pelvic reconstruction in misalignment lesions☆

João Antonio Matheus Guimarães, Vinícius Magno da Rocha, André Luiz Loyelo Barcellos*

Instituto Nacional de Traumatologia e Ortopedia Jamil Haddad, Rio de Janeiro, RJ, Brazil

ARTICLE INFO

Article history:
Received 9 December 2016
Accepted 26 January 2017
Available online 24 August 2017

Keywords:
Osteotomy
Bone screws
Sacroiliac joint
Pelvic bones

ABSTRACT

Pelvic ring fractures occur in association with potentially fatal lesions, whose treatment is a priority in the polytrauma setting. As consequence, the definitive orthopedic approach may be postponed, leading patients to chronic and potentially disabling deformities. The treatment of these deformities is a challenge, requiring highly complex and staged surgical reconstructions. The ilioinguinal approach has been widely used in these surgeries, because it allows the release and mobilization of the hemipelvis and, in some cases, anterior fixation of the sacroiliac joint. However, in most cases, stable pelvic ring reconstruction requires this approach to be complemented by two other surgical approaches (posterior longitudinal and Pfannestiel). This requirement critically increases the surgical time and the risk of complications, such as neurovascular lesions and surgical wound infection. The current study presents a posterior osteotomy technique for posterior and anterior release of the sacroiliac joint, eliminating the need for ilioinguinal approach. The technique is performed by posterior longitudinal access; it allows adequate mobilization of the hemipelvis and reduction of vertical and rotational deformities, before the spinopelvic fixation and reduction of the pubic symphysis.

© 2017 Sociedade Brasileira de Ortopedia e Traumatologia. Published by Elsevier Editora Ltda. This is an open access article under the CC BY-NC-ND license (http://creativecommons.org/licenses/by-nc-nd/4.0/).

Osteotomia sacroilíaca posterior: uma opção ao acesso ilioinguinal na reconstrução pélvica em lesões inveteradas

Palavras-chave:
Osteotomia
Parafusos ósseos
Articulação sacroilíaca
Osso pélvico

RESUMO

As fraturas do anel pélvico ocorrem em associação com lesões potencialmente graves, cujo tratamento é prioritário no cenário de atendimento ao politraumatizado. Como consequência, a abordagem ortopédica definitiva pode ser postergada, fazendo com que os pacientes se apresentem com deformidades inveteradas e potencialmente incapacitantes. O tratamento dessas deformidades é um desafio, requer reconstruções cirúrgicas estagiadas e altamente

☆ Study conducted at Instituto Nacional de Traumatologia e Ortopedia Jamil Haddad, Rio de Janeiro, RJ, Brazil.

* *Corresponding author*.
E-mail: jguimaraes@into.saude.gov.br (J.A. Guimarães).

http://dx.doi.org/10.1016/j.rboe.2017.08.010

2255-4971/© 2017 Sociedade Brasileira de Ortopedia e Traumatologia. Published by Elsevier Editora Ltda. This is an open access article under the CC BY-NC-ND license (http://creativecommons.org/licenses/by-nc-nd/4.0/).

complexas. O acesso ilioinguinal tem sido amplamente usado nessas cirurgias, pois permite a liberação e mobilização da hemipelve e, em alguns casos, a fixação anterior da articulação sacroilíaca. Entretanto, na maioria das vezes, uma reconstrução estável requer que esse acesso seja usado em associação com outros dois acessos cirúrgicos (longitudinal posterior e Pfannestiel), o que aumenta sobremaneira o tempo cirúrgico e o risco de complicações, como lesões neurovasculares e infecção da ferida operatória. No presente estudo, apresentamos uma técnica de osteotomia posterior para liberação posterior e anterior da articulação sacroilíaca que elimina a necessidade de uso do acesso ilioinguinal. A técnica é feita pelo acesso longitudinal posterior e permite mobilização adequada da hemipelve e redução de deformidades verticais e rotacionais antes da fixação espinopélvica e redução da sínfise púbica.

© 2017 Sociedade Brasileira de Ortopedia e Traumatologia. Publicado por Elsevier Editora Ltda. Este é um artigo Open Access sob uma licença CC BY-NC-ND (http://creativecommons.org/licenses/by-nc-nd/4.0/).

Introduction

Pelvic ring injuries result from high energy trauma. Their association with cranioencephalic trauma, pulmonary contusions, and/or abdominal visceral lesions increases the length of stay in intensive care units (ICU) for clinical stabilization.[1] In some countries, the difficulty to access specialized orthopedic centers for the treatment of these lesions further delays the definitive approach; it also increases the length of hospital stay and the morbidity resulting from prolonged use of external fixators.[1–3]

It is not uncommon for these survivors to evolve with pain, functional limitation and, in some cases, neurological deficits associated with inveterate deformity,[3] whose treatment is still a challenge. Some of the difficulties to be overcome include vicious consolidation, exuberant formation of bony callus, proximity to abdominopelvic organs and neurovascular structures, and implant positioning in complex fracture patterns, with bone loss and/or infection resulting from prolonged use of external fixators.[1–4]

In most cases, inveterate pelvic ring lesions are treated with three surgical approaches: (1) ilioinguinal approach (first window), to release the anterior portion of the sacroiliac joint (SIJ); (2) longitudinal posterior approach to the sacrum, to release the posterior portion of the SIJ and posteriorly fixate the pelvic ring; and (3) the Pfannenstiel approach, to reduce and fixate the pubic symphysis (PS).[1,2] The present study presents a technique that eliminates the need for the first ilioinguinal window, reducing the risk of neurovascular injury and infection, as well as surgical time and operative blood loss.

Description of the method

In the reported technique, the authors describe the case of a 40-year-old patient, victim of a 12-meter fall, who suffered direct trauma to the lower limbs. In addition to the pelvic injury, the patient was admitted to the emergency unit with head and abdominal trauma, pulmonary contusion and multiple rib fractures on the right, fracture-dislocation of the right foot, and neurological deficit of the right L5 nerve root. After initial stabilization of the pelvis (with external fixator) and of the fracture-dislocation of the foot and exploratory laparotomy, the patient stayed in the ICU for eight weeks until clinical stabilization. The external fixator was then removed in the ICU, on the sixth week after the trauma.

Two years after the accident, the patient was re-assessed. She complained of low back pain, pain in the right inguinal region, and difficulty in walking and sitting for long periods. New imaging tests revealed deformity in lateral rotation and high right hemipelvis (Fig. 1A–D), which led to shortening of the ipsilateral lower limb. Surgical treatment was indicated for reconstruction of the pelvic ring.

Surgical technique

First stage

We performed a posterior longitudinal approach to the sacrum with the patient in ventral decubitus positioning, under general anesthesia, followed by dissection of the musculature to allow wide visualization of the right SIJ. The L5, S1, and iliac instrumentation were performed bilaterally, aiming to achieve spinopelvic fixation after osteotomy and correction of the deformity. The ossification observed on the SIJ, sacral wing, and transverse process of L5 was carefully removed, allowing the release of the L5 root, which was trapped between the sacral wing and the transverse process by the raised right hemipelvis. Careful osteotomies were made in the SIJ from its cephalic to caudal ends; thin osteotomes were used from the posterior sacral aspect toward the inside of the joint, creating a progressively wider groove in the joint space (Fig. 2A–C). At this stage, as a protective measure for the vessels and pelvic organs, we ensured that the osteotomes did not surpass the anterior portion of the joint. The thin bony layer remaining in the anterior portion of the joint was then removed with Kerrison punches (Fig. 2D). Before wound closure, a fragment of the iliac crest bone was resected for use in the next stage of surgery.

Second stage

Still under general anesthesia, the patient was placed in the dorsal decubitus positioning. The PS was accessed through a Pfannenstiel approach. The PS was reduced with bone tweezers, and was fixated with a reconstruction plaque. The symphysis was revitalized and the iliac crest obtained in the

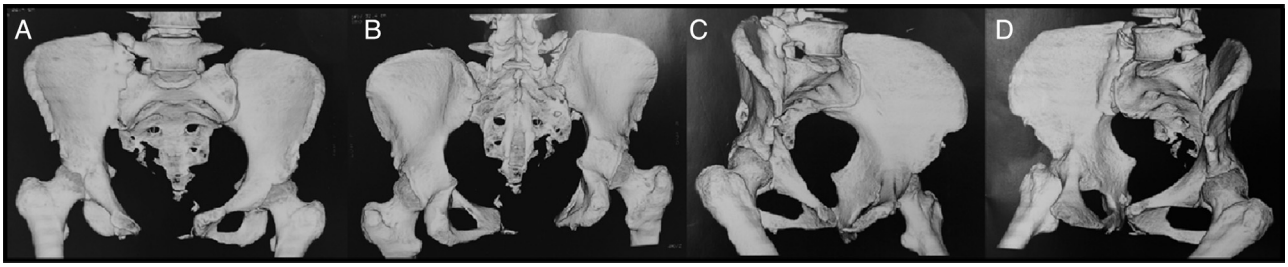

Fig. 1 – Three-dimensional computed tomography reconstruction two years after the trauma. (A) Anterior view; (B) posterior view; (C) left wing view; (D) right wing view.

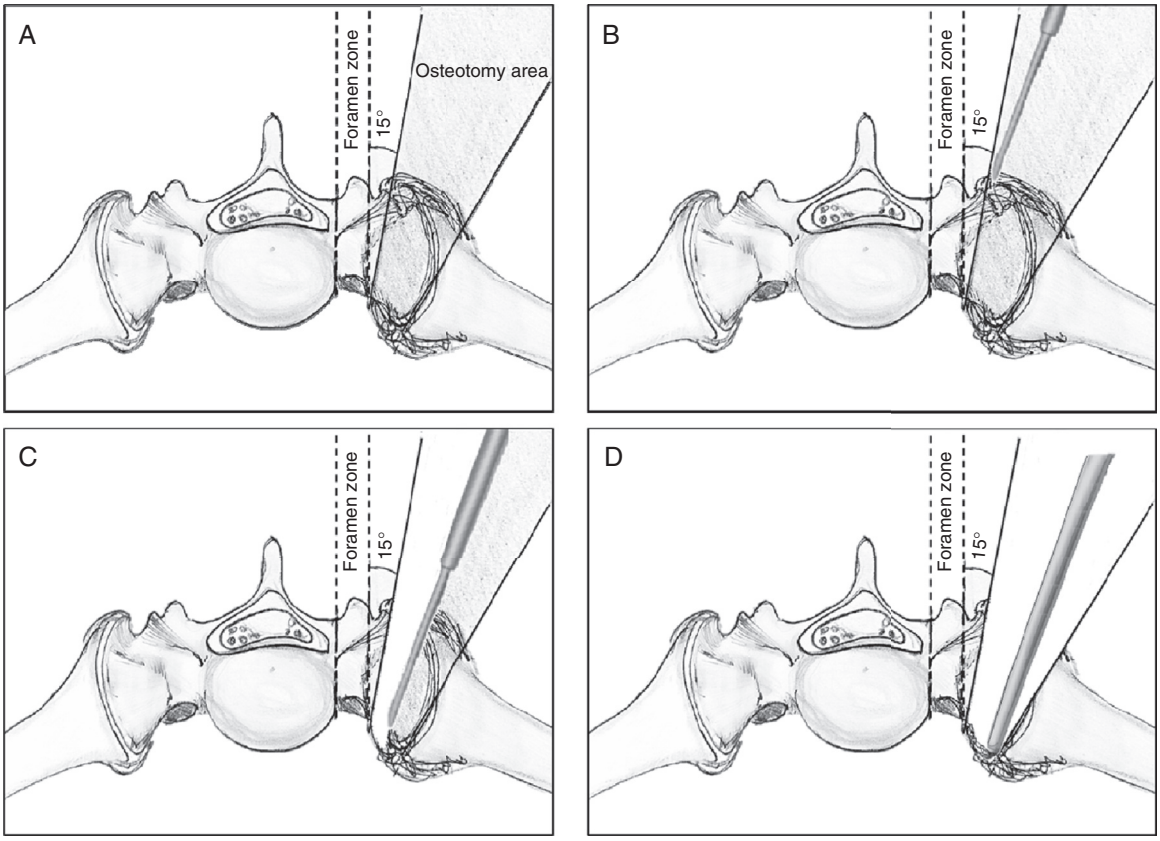

Fig. 2 – Posterior sacroiliac osteotomy. (A) Demonstration of the area of safety and angle of attack of the osteotome for the sequential bone cuts; (B and C) sequential bone resection, with groove creation and maintenance of the thin anterior cortical layer; (D) completion of osteotomy using a Kerrison punch.

previous step was interposed, in order to achieve joint fusion. A second plate was positioned to fixate the graft and provide additional rigidity to the assembly. The wound was closed in planes, with good coverage of the implants.

Third stage

Patient was repositioned in the ventral decubitus and the access made in the first stage was reopened. The deformity was reduced with pliers that allowed distraction of the heads of the L5 and iliac screws (Fig. 3A). Spinopelvic fixation was performed by locking the nails to the screws and joining them through a transverse connector. A spongy graft from the iliac crest was then placed in the osteotomy bed and the SIJ (Fig. 3B). Finally, the wound was closed in layers, with the subcutaneous installation of Hemovac® drain.

The patient remained hospitalized for seven days after surgery, was released to ambulation on the third postoperative day, and has been followed-up regularly in the outpatient clinic for 18 months, showing improvement in both pain and gait. Lesion consolidation was observed sixth month after surgery (Fig. 4A and B). The L5 nerve root function has not been retrieved.

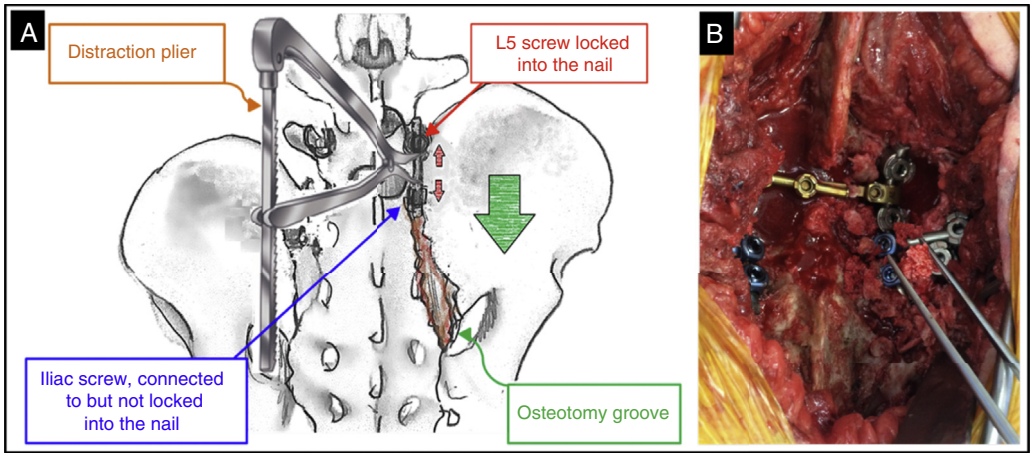

Fig. 3 – Posterior reduction of deformity. (A) Drawing of the technique and (B) grafting of the osteotomy groove.

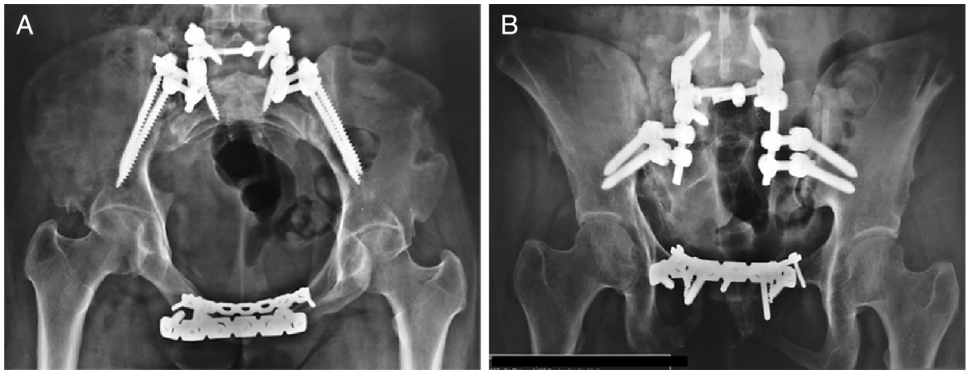

Fig. 4 – Radiographs of the first postoperative year. (A) Inlet view and (B) outlet view.

Final remarks

When addressed in the emergency room, most unstable pelvic fractures are treated with external fixators, even if temporarily. Lindhal et al.[3] reported a series of 110 cases of unstable fractures treated with external fixation; in 85% of cases, the results were unsatisfactory. In their study, the main complication was vicious consolidation with residual deformity (58%).

Although these deformities are associated with reduced quality of life, the present authors agree with Mears and Velyvis[4] that not all patients would benefit from surgical reconstruction. Given the complexity of these lesions, clinical and radiological aspects should be taken into account, as well as the experience of the surgical team and the availability of adequate implants for the treatment of these patients. Both hemipelvic vertical deviation greater than 10 mm and rotation greater than 10 degrees are associated with chronic pain and functional limitation; these parameters are used to indicate reconstruction in patients presenting with pain, progressive neurological deficit, and/or gait difficulty.[2,5]

Usually, surgical reconstruction requires a staged approach to recreate the initial lesion, allowing its mobilization and correction of the deformity. For each stage of treatment, a different surgical approach is used (Table 1).

Injuries with multidirectional instability usually present with ascending and rotating hemipelvis, circumferential calcification of the SIJ, and soft tissue retraction, and frequently require triple-staged approach.[2] In this approach, the ilioinguinal access is used for anterior release of the SIJ, and has been considered a cornerstone of the treatment.[2,4] This access increases operative time, blood loss, and the risk of heterotopic ossification; it also puts the L5 nerve root and inguinal neurovascular bundle at risk and has already been linked to abductor muscle weakness, incisional hernias, and postoperative infections.[6]

The technique presented in this article waives the need for an ilioinguinal access, without impairing the release of the anterior portion of the SIJ. The progressive enlargement of the osteotomy area creates space for both the vertical and rotational correction of the deformity, without excessive bone resection. Furthermore, when the ilium is fused to the L5 transverse process, as observed in the present case, adequate

Table 1 – Access options in the staged approach for reconstruction of inveterate pelvic deformities.

	Surgical accesses	Indication
Anterior–posterior–anterior		
(1) Ilioinguinal	Release with or without fixation of the anterior sacroiliac joint	Deformities with vertical and rotational deviation of the hemipelvis, with circumferential calcification of the sacroiliac joint and opening of the pubic symphysis
(2) Posterior longitudinal	Release and fixation of the posterior sacroiliac joint	
(3) Pfannenstiel	Reduction and fixation of the pubic symphysis	
Posterior–anterior–posterior		
(1) Posterior longitudinal	Posterior release of the sacroiliac joint	Deformities with vertical and rotational deviation of the hemipelvis, with predominantly posterior calcification of the sacroiliac joint and opening of the pubic symphysis
(2) Pfannenstiel	Anterior reduction and fixation of the pubic symphysis	
(3) Posterior longitudinal	Posterior fixation of the sacroiliac joint	
Anterior–posterior		
(1) Ilioinguinal	Anterior release of sacroiliac joint	Deformities with minimal vertical deviation, minimal opening of the pubic symphysis, and calcification of the sacroiliac joint
(2) Posterior longitudinal	Posterior fixation of the sacroiliac joint	
Anterior–anterior		
(1) Ilioinguinal	Anterior release and fixation of the sacroiliac joint	Rotational deformities with posterior sacroiliac integrity and anterior opening of the sacroiliac joint and the pubic symphysis
(2) Pfannenstiel	Reduction and fixation of the pubic symphysis	
Posterior		
Posterior longitudinal	Posterior release and fixation of the sacroiliac joint	Vertical and/or rotational deformities with minimal opening of the pubic symphysis
Anterior		
Ilioinguinal	Release and fixation of the anterior sacroiliac joint	Deformities with anterior sacroiliac opening and minimal opening of the pubic symphysis
or		
Pfannenstiel	Reduction and fixation of the pubic symphysis	Rotational deformities with sacroiliac integrity and opening of the pubic symphysis

reduction of the hemipelvis through the ilioinguinal approach becomes infeasible.

Another aspect that deserves attention is the insufficient stability of the anterior sacroiliac osteosynthesis, which makes posterior complementation necessary, especially in deviated and aged lesions.[7] Moreover, skeletal traction or use of Schanz screws as a joystick may be necessary to reduce the ilium and to position the anterior sacroiliac plates. When the release is made through a posterior approach, the distraction maneuvers between L5 and the iliac screws allow adequate reduction, not requiring additional devices that further increase morbidity and duration of the surgery.[8]

In the present patient, the Pfannenstiel access was used in the second stage of surgery to reduce and fixate the PS, providing greater stability to the pelvic ring. Biomechanical studies that evaluate the importance of this stage in pelvic reconstruction are still necessary. The need to fusion the SIJ is another controversial point in the presented technique. The authors used grafts in the osteotomy area, because some areas of the groove made remained with no bone contact even after the deformity was reduced. The contralateral SIJ is also fused, because the authors believe that this allows reduction of the biomechanical stress on the screws inserted in the ilium and thus the risk of loosening or breaking.

This technique is a promising option, but it is equally technically demanding. The main limitation is still the need for integration between the orthopedic trauma surgery and the spine surgery teams. Training new orthopedists in advanced courses of pelvic trauma is an investment that must be considered in light of the growing number of trauma patients and the creation of specialized centers.

Conflicts of interest

The authors declare no conflicts of interest.

REFERENCES

1. Kanakaris NK, Angoules AG, Nikolaou VS, Kontakis G, Giannoudis PV. Treatment and outcomes of pelvic malunions and nonunions: a systematic review. Clin Orthop Rel Res. 2009;467(8):2112–24.
2. Oransky M, Tortora M. Nonunions and malunions after pelvic fractures: why they occur and what can be done? Injury. 2007;38(4):489–96.
3. Lindahl J, Hirvensalo E, Bostman O, Santavirta S. Failure of reduction with an external fixator in the management of injuries of the pelvic ring Long-term evaluation of 110 patients. J Bone Joint Surg Br. 1999;81(6):955–62.

4. Mears DC, Velyvis J. Surgical reconstruction of late pelvic post-traumatic nonunion and malalignment. J Bone Joint Surg Br. 2003;85(1):21–30.
5. van Gulik TM, Raaymakers EL, Broekhuizen AH, Karthaus AJ. Complications and late therapeutic results of conservatively managed, unstable pelvic ring disruptions. Neth J Surg. 1987;39(6):175–8.
6. Wang P, Zhu X, Xu P, Zhang Y, Wang L, Liu X, et al. Modified ilioinguinal approach in combined surgical exposures for displaced acetabular fractures involving two columns. Springerplus. 2016;5(1):1602.
7. Lindahl J, Hirvensalo E. Outcome of operatively treated type-C injuries of the pelvic ring. Acta Orthop. 2005;76(5): 667–78.
8. Jones CB, Sietsema DL, Hoffmann MF. Can lumbopelvic fixation salvage unstable complex sacral fractures? Clin Orthop Rel Res. 2012;470(8):2132–41.