Article published online: 2022-06-20

Midterm Radiographic Results and Reoperations of Tantalum Trabecular Metal Cones in Knee Arthroplasties

Reoperações e resultados radiográficos de médio prazo do uso de cone de metal trabecular de tântalo nas artroplastias do joelho

Sandra Tie Nishibe Minamoto[1] Luís Felipe Tupinambá da Silva[1] José Leonardo Rocha de Faria[1] Hugo Alexandre de Araujo Barros Cobra[1] Idemar Monteiro da Palma[2] Alan de Paula Mozella[1]

[1] Orthopedists, Instituto Nacional de Traumatologia e Ortopedia, Rio de Janeiro, RJ, Brazil
[2] Orthopedic Physicians Hospital Rios D'Or da Rede D'Or São Luiz, Rio de Janeiro, RJ, Brazil

Address for correspondence Sandra Tie Nishibe Minamoto, MD, Instituto Nacional de Traumatologia e Ortopedia, Grupo de Cirurgia do Joelho, Rio de Janeiro, RJ, Brazil (e-mail: sandraminamoto@yahoo.com.br).

Rev Bras Ortop 2022;57(5):734–740.

Abstract

Objective The management of bone loss represents a challenge in revisions of total knee arthroplasty (rTKA) and in complex primary total knee arthroplasties (TKAs). The purpose of the present study was to evaluate the midterm outcomes (5-year minimum follow-up) of knee reconstructions with tantalum trabecular metal (TM) cones on bone defects Anderson Orthopaedics Research Institute (AORI) 2 and 3.

Materials and Methods A retrospective analysis of the medical records of patients operated on between July 2008 and November 2014 was performed, collecting the following data: age, gender, laterality, body mass index, etiology of arthrosis, comorbidities, AORI classification of bone defects, causes for revision, readmissions, reoperations, perioperative and postoperative complications, radiographic signs of osteointegration, and maintenance of the TM support.

Results A total of 11 patients with a mean follow-up of 7.28 years (standard deviation [SD] = 1.88; range = 5.12–10 years) was evaluated, with 1 patient operated upon for a primary arthroplasty, 6 for revision arthroplasties, and 4 for a second revision arthroplasty (re-revision).

There were complications with the surgical wound, injury to the extensor mechanism and loosening of the femoral component in three of the patients that led to the

Keywords
- arthroplasty, replacement, knee
- osteointegration
- knee prosthesis
- biocompatible materials

* *Study developed at the National Institute of Traumatology and Orthopedics, Rio de Janeiro, Brazil.*

received April 1, 2020
accepted July 8, 2021
published online June 20, 2022

DOI https://doi.org/10.1055/s-0041-1739465.
ISSN 0102-3616.

© 2022. Sociedade Brasileira de Ortopedia e Traumatologia. All rights reserved.
This is an open access article published by Thieme under the terms of the Creative Commons Attribution-NonDerivative-NonCommercial-License, permitting copying and reproduction so long as the original work is given appropriate credit. Contents may not be used for commercial purposes, or adapted, remixed, transformed or built upon. (https://creativecommons.org/licenses/by-nc-nd/4.0/)
Thieme Revinter Publicações Ltda., Rua do Matoso 170, Rio de Janeiro, RJ, CEP 20270-135, Brazil

necessity of four procedures due to complications with the surgical wound, injury to the extensor mechanism and loosening of the femoral component. Radiological signs of osteointegration of the trabecular cones were observed in all patients. We did not observe migration of the TM cones or the prosthetic components in the sample.

Conclusion The tantalum metaphyseal cones were able to provide efficient structural support to prosthetic implants with radiographic signs of osteointegration in the medium term.

Resumo

Objetivo O manejo da perda óssea representa um grande desafio em cirurgias de revisão de artroplastia do joelho (rATJ) e em artroplastias totais do joelho (ATJ) primárias complexas. O objetivo do presente estudo foi avaliar os resultados em médio prazo (seguimento mínimo de 5 anos) das reconstruções de joelho nas quais cones de metal trabecular (MT) de tântalo foram utilizados para tratamento de defeitos ósseos tipos 2 e 3, de acordo com a classificação proposta pela Anderson Orthopaedic Research Institute (AORI).

Métodos Feita análise retrospectiva dos prontuários dos pacientes operados entre julho de 2008 e novembro de 2014, coletando-se os seguintes dados: idade, gênero, lateralidade, índice de massa corporal, etiologia da artrose, comorbidade, classificação AORI da falha óssea, causa da revisão da artroplastia total do joelho, reinternações, reoperações, complicações peri- e pós-operatórias, ocorrência de osteointegração radiográfica e manutenção da função de suporte do MT.

Resultados Foram avaliados 11 pacientes com tempo médio de seguimento de 7,28 anos (desvio padrão [DP] = 1,88; variação = 5,12–10 anos), sendo que 1 paciente foi submetido a artroplastia primária, 6 a artroplastia de revisão e 4 a segunda revisão de artroplastia (re-revisão). Três pacientes necessitaram de quatro reoperações devido a complicações com a ferida operatória, a lesão do mecanismo extensor e a soltura do componente femoral. Sinais de osteointegração dos cones trabeculados foram observados em todos os pacientes. Não observamos migração do cone de MT ou dos componentes protéticos.

Conclusão Os cones metafisários de tântalo foram capazes de prover suporte estrutural eficiente aos implantes protéticos com sinais radiográficos de osteointegração em médio prazo.

Palavras-chave
- artroplastia do joelho
- osteointegração
- prótese do joelho
- materiais biocompatíveis

Introduction

The management of bone loss represents a huge challenge in revisions (rTKA) and complex primary total knee arthroplasties (TKAs). Bone deficiency usually presents a multifactorial etiology, such as the evolution of the joint degenerative process, the design of the old prosthesis, the mechanism of failure may be related to technical errors during the primary surgery or difficulties in removing fixed implants.[1,2]

Several classifications of bone defects have been proposed and, currently, the most used is the one developed by the Anderson Orthopaedics Research Institute (AORI). In this system, the defect is classified after removal of the implant. Type 1 defects present intact metaphyseal bone with minor flaws that do not compromise support and fixation of the revision implant; type 2 defects compromise the metaphyseal bone of one (2A) or both femoral condyle or tibial condyles (2B), and type 3 defects present cortical and cancellous bone deficit in the metaphysis, occasionally associated with collateral ligament detachment.[3]

The proper management of these bony defects depends, among other factors, on its size, location, configuration, and cortical involvement. Therefore, there are several options for treating these bone deficiencies, such as the utilization of methylmethacrylate augmented with screws, modular metal wedges, autologous bone and allograft and, more recently, trabecular metal (TM) in the form of cones or metaphyseal sleeves.[2–5]

Despite the existence of these options, the ideal one for the treatment of AORI 2 or 3 defects remains controversial.[4] Structural allografts, although widely used, presents significant disadvantages, such as bone resorption, graft fracture, nonunion to the host bone, possibility of diseases transmission, and limited availability.[5] Another important limitation of this method refers to the durability of its support capability in the medium and long-term.[6]

Thus, tantalum TM cones represent a modern option for treating these major bone failures,[6–8] given their greater potential for biological fixation and, thus, for the promotion of structural support and immediate mechanical stability.

 © 2022. Sociedade Brasileira de Ortopedia e Traumatologia. All rights reserved.

Several studies have demonstrated the effectiveness of tantalum cones in providing stable fixation, reliable support, and high osteointegration index, with good short-term clinical results.[6–11] However, long-term follow-up is needed in order to evaluate the durability of these reconstructions.

The aim of the present study was to evaluate the medium-term results, with a minimum 5-year follow-up, of complex primary and revision TKAs in which tantalum metaphyseal cones were used for the treatment of large tibial and/or femoral bone defects.

Materials and Methods

After approval by the Research Ethics Committee (CAAE no. 06896019.8.0000.5273), a retrospective analysis of the medical records of all patients who had been operated upon for a primary or revision total knee arthroplasty (TKA) was performed in the period between July 2008 and November 2014. There was no age limit or restriction regarding the gender of the participants.

The following data were collected from all patients: age, gender, laterality, body mass index (BMI), etiology of the arthritic process, comorbidities, AORI classification of the bone failure, cause of TKA revision, readmissions, reoperations, perioperative and, postoperative complications, and outcomes.

Bone defects were categorized according to the AORI classification by the three senior authors and, in case of disagreement, it was opted to to consider that which had been reached a simple majority. The authors also performed the analysis of the X-ray sequences to determine the occurrence of osteointegration, and the maintenance of the support function of tantalum cones. The criterion for defining the occurrence of osteointegration was the presence of a bony reaction at the trabecular metal-host bone interface, configured by the presence of sclerosis associated with the absence of radiolucency lines. The maintenance of the support function was evaluated through eventual migration of the implants or by the presence of a progressive radiolucency line.

Descriptive analyses for quantitative data were performed, and the means were presented, accompanied by the respective standard deviations ($\pm$SD), medians, minimum and maximum values and first and third interquartile interval (IQ). Categorical variables were expressed through their frequencies and percentages. All analyses were performed with IBM SPSS Statistics for Windows version 21 (IBM Corp., Armonk, NY, USA) with a significance level of $\alpha = 0.05$. The implant survival analysis was not performed due to the low number of participants in the research.

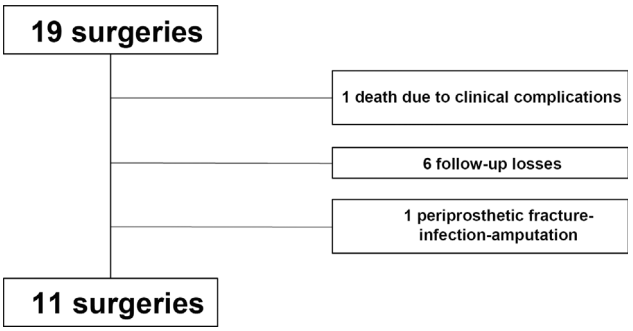

Fig. 1 Number of surgeries and exclusion reasons.

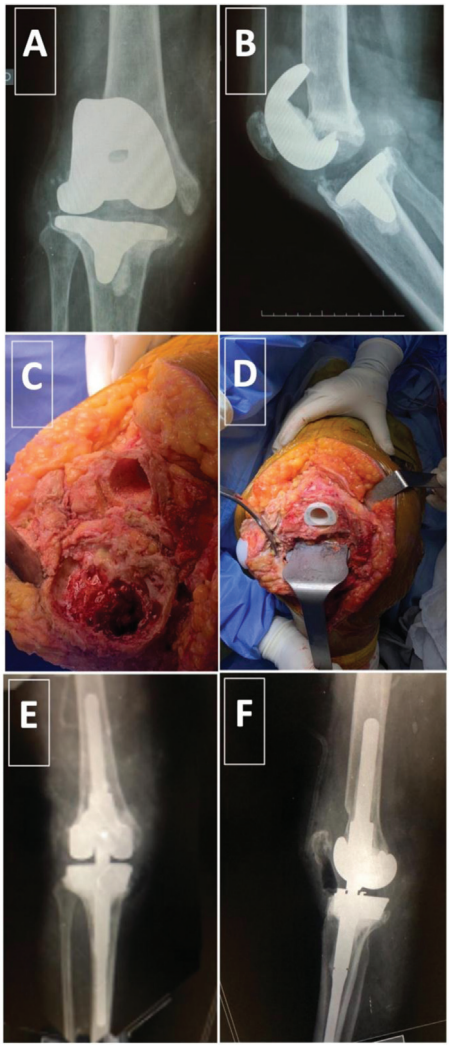

Fig. 2 (A and B) Radiographs in anteroposterior and aseptic loosening profile of the femoral component; (C) intraoperative aspect of bone loss; (D) implanted trabecular metal femoral cone; (E and F) postoperative X-rays.

Results

From November 2008 to November 2014, TM was used to treat large bone defects in 19 complex primary arthroplasty or knee revision surgeries. One patient died due to clinical complications 40 days after the procedure. Another patient with a periprosthetic fracture and deep infection after open reduction and internal fixation (ORIF), had to have an above-the-knee amputation (AKA) amputation 2 years after the index surgery. Six patients were excluded due to loss to follow-up. Therefore, 11 patients with a minimum 5-year follow-up for the implantation of the metaphyseal TM cones had their data analyzed (►**Figures 1** and **2**).

 © 2022. Sociedade Brasileira de Ortopedia e Traumatologia. All rights reserved.

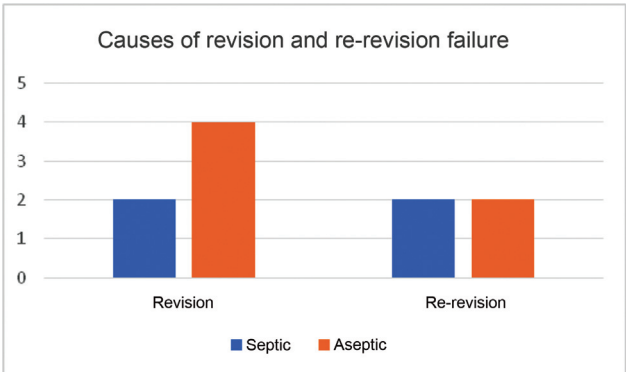

Fig. 3 Distribution of causes of total knee arthroplasty failure that required tantalum metaphysary cones to treat bone defect

The mean follow-up was 7.28 years (SD = 1.88; range = 5.12–10 years). The mean age of the patients at the time of the procedure procedure was 67.54 years (SD = 10.74 years; range = 45–86 years). Eight patients were female (72.72%) and 3 were males (27.27%). The mean BMI was 29.78kg/m^2 (SD = 6.36; range = 22.76–43.41 kg/m2). Mean length of stay (LOS) was 6 days (IQ = 4.50–7.50). The distribution of Charlson comorbidity score ranged from 0 to 5, and most patients had Charlson Index 2.

Four procedures were performed on the right knee and seven in the left knee. One patient with Charcot-like arthropathy underwent primary arthroplasty (9.09%) with revision components (rotating hinged knee). Six other patients underwent revision arthroplasty (54.55%), and second revision (re-revision) was performed in 4 cases (36.26%). ►**Figure 3** shows the distribution between septic and aseptic failures of the cases of revision (rTKA) and re-revision. ►**Table 1** demonstrates the causes of aseptic failures.

Regarding surgical pathways, surgery was performed by conventional approach in 9 surgeries (81.81%) and by extended approach in 2 surgeries. The Coonse-Adams approach was used in an aseptic re-revision case, while osteotomy of the anterior tibia tuberosity (TTO) was the choice in aseptic revision surgery.

In eight patients, highly constricted implants (Rotating Hinge Knee – Zimmer Biomet, Warsaw, IN, EUA) were used, and semiconstricted implants (Legacy Constrained Condylar Knee – Zimmer Biomet, Warsaw, IN, EUA or Total Condylar 3– DePuy Synthes, West Chester, PA, EUA) were used in three patients.

Tantalum cones were implanted in the tibia in 10 patients, while femoral cones were needed in 2 and a trabecular metal cones were used in 1 patient. ►**Table 2** shows the classification of the bone defects. The patient who required tantalum cone in the femur and in the tibia had an AORI 3 defect in the femur and a 2b defect in the tibia (►**Figure 4**).

The analysis of sequential radiographic images showed that all 11 patients showed signs of osteointegration of the implant. We did not observe signs of loss or migration of the trabecular metal cone or of the prosthetic components in any patient as well as no signs of osteolysis.

Table 1 Causes of aseptic failures

	Revision	Re-revision
Pain	1	0
Instability	1	1
Aseptic release	2	1
	4	2

Table 2 Classification of defects with trabecular metal cones

	Tibia	Femur
1	0	0
2a	1	0
2b	6	0
3	3	2
	10	2

Fig. 4 (A and B) Preoperative radiographs demonstrating failure of knee prosthesis with medial tibial defect due to sinking of the component; (C and D) postoperative radiographs demonstrating treatment of bone defect with tibial metaphysary cone.

 © 2022. Sociedade Brasileira de Ortopedia e Traumatologia. All rights reserved.

Two patients had early complications, one of which with a subcutaneous hematoma that required surgical procedures for drainage and control. The second patient presented with erysipelas with erysipelas in the operated limb 20 days after surgery, requiring hospitalization for antibiotic therapy and resolution of the condition. During the study period, we did not observe of complications or reoperations directly related to the use of tantalum cones.

During the follow-up period, two patients required reoperations, totaling four surgeries. One of them, previously mentioned for hematoma drainage in two approaches, was submitted to an extensor mechanism transplantation due to osteonecrosis and fragmentation of the native patella after a 4-year follow-up. The second patient with no tantalum femoral cone had loosening associated with sinking of the femoral component 9 years after the initial surgery, and had to have a revision of the femoral component. During the intraoperative evaluation, the tibial tantalum was fixed and with signs of osteointegration (►**Figure 5**).

Discussion

The optimal treatment of large bone defects in complex primary or knee revision arthroplasties remains undefined. More recently, tantalum TM cones have demonstrated promising results in short-term evaluation for the treatment of these bone losses. However, the duration of support capacity, and clinical results in the medium- and long-term, require evidence.[12–16] Our main result was to demonstrate the absence of mechanical failures and migration of prosthetic components with the use of metaphyseal cones in the medium-term evaluation.

Although short-term clinical results with tantalum cones are favorable,[6–9,11,20–23] there are few studies evaluating medium-term results.[16–18] Tantalum is a transition metal that remains relatively inert in vivo. It is a structure of open cells in dodecahedrons in sequence, thus simulating the microstructure of the cancellous bone. Therefore, it is quite attractive as a biomaterial due to its low stiffness, high porosity, and high coefficient of friction, besides serving as a structure for osteoblastic activity. In general, bone growth in pores occurs on average 13% in 2 weeks, 53% in 4 weeks, and up to 80% in 1 year, and it is possible to verify evidence of osteointegration on radiographs in an average period of 36 months.[27] The low modulus of elasticity, similar to cortical and cancellous bone, reduces bone resorption in the periphery of the implant by inadequate load distribution, favoring the maintenance of bone mineral density around the implant. This is an advantage, considering the frequent need for high constriction in complex primary and revision TKA.[28] In our study, semiconstricted implants were used in three patients, and constricted implants in eight patients.

In addition, the high coefficient of friction provides immediate mechanical stability; therefore, the impaction of cones in the metaphyseal bone offers strong instantaneous mechanical support that allows controlling the rotational forces of the implants, protecting fixation and bone ingrowth. Proper stress transfer also allows the use of shorter stems.[25,28] Other important characteristics are low cytotoxicity and leukocyte activation capacity, making it one of the most biocompatible materials to date, what may be an interesting feature in infected revision arthroplasties.[25,29]

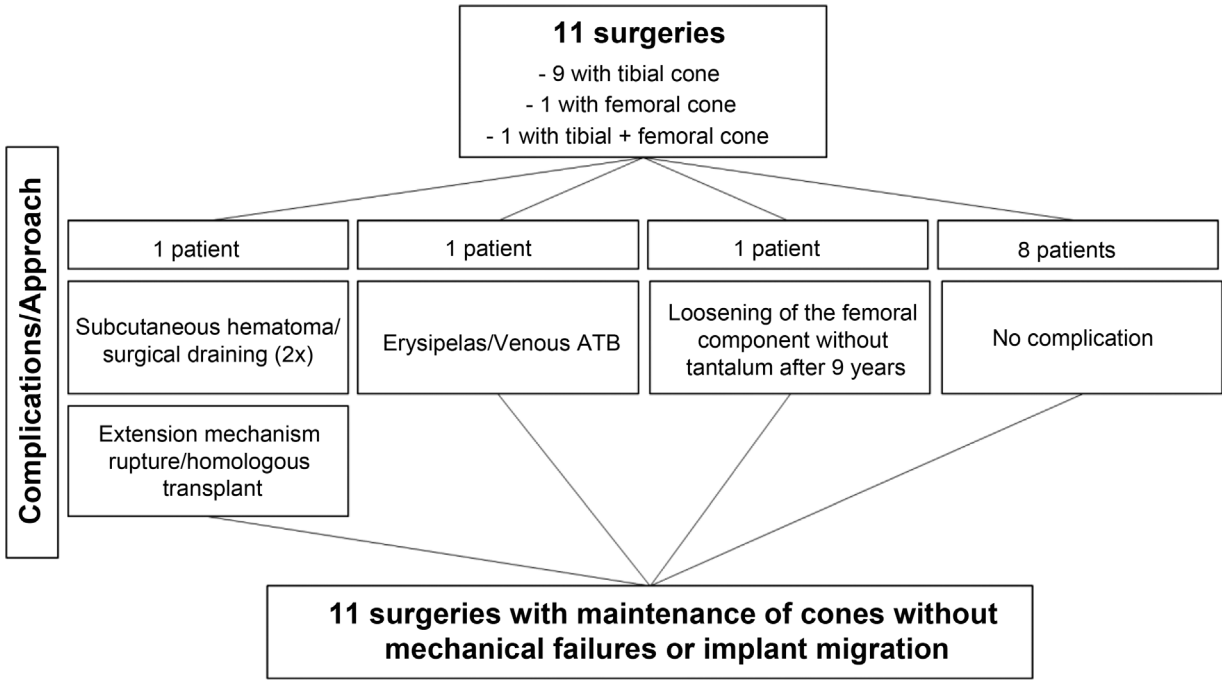

Fig. 5 Evolution and complications of patients submitted to surgery using trabecular metal cones.

 © 2022. Sociedade Brasileira de Ortopedia e Traumatologia. All rights reserved.

In the present study, 3 patients (36.36%) required four reoperations due to complications with the surgical wound, with the extensor mechanism, and loosening of the femoral component. This rate is higher than that found in the meta-analysis performed by Divano et al.,[30] who, when analyzing 19 studies, showed an average rate of reoperations of 16.19%. However, the reoperations in our study were not directly related to complications of the metaphyseal cone. Most studies of this meta-analysis showed early results of the use of tantalum cones, with a mean follow-up of 3.65 years. Our rates are closer to those of a study with a longer follow-up such as that presented by Kamath et al.,[25] who evaluated, for 70 months, 63 patients who were treated with tibial cones in revisions TKAs and had 24% of reoperations. Similarly, it also approximates the rates observed by Potter et al.,[24] who found a survival rate of 70% in 5 years.

In our sample, all patients showed signs of osteointegration on X-ray at the last follow-up follow-up. These results are in line with other studies[6–9,11,20–22] that analysed a total of 285 cones in 242 knees submitted to TKA revision and that demonstrated that in only 2 knees (0.7%) there were no radiographic signs of bone ingrowth.

The present study has limitations, many of which inherent to its retrospective nature. We recognize the subjectivity that radiographic analysis presents, particularly when performed retrospectively, and we tried to mitigate this inaccuracy through the opinion of 3 surgeons with 13, 20 and 37 years experience in knee surgery. Another important factor is that the study population is characteristically formed by elderly patients, and it is possible have had some loss to follow-up by decease. In addition, the group of patients is relatively small, but similar to those of previous studies.[6–9,11,20–23] Thus, in a series with a limited number of patients, it is impossible to detect unusual complications and low-frequency events that may be clinically important. Nevertheless, this is one of the few studies in Brazil that describes the results of the treatment of large bone defects with tantalum metaphyseal cones.

Conclusions

In our study, tantalum metaphyseal cones showed to be or demonstrated to be able to provide efficient structural support to prosthetic implants with radiographic signals of osteointegration in the medium-term. Therefore, the use of trabecular metal cones represents an attractive option for the treatment of large bone defects in complex primary and revision TKAs. However, prospective studies with a larger sample and longer follow-up is warranted.

Source of Funding
No financial support.

Conflict of Interests
The authors have no conflict of interests to declare.

References

1 Whittaker JP, Dharmarajan R, Toms AD. The management of bone loss in revision total knee replacement. J Bone Joint Surg Br 2008; 90(08):981–987
2 Panegrossi G, Ceretti M, Papalia M, Casella F, Favetti F, Falez F. Bone loss management in total knee revision surgery. Int Orthop 2014; 38(02):419–427
3 McAuley JP, Engh GA. Constraint in total knee arthroplasty: when and what? J Arthroplasty 2003;18(03, Suppl 1):51–54
4 Bush JL, Wilson JB, Vail TP. Management of bone loss in revision total knee arthroplasty. Clin Orthop Relat Res 2006;452(452): 186–192
5 Dennis DA. The structural allograft composite in revision total knee arthroplasty. J Arthroplasty 2002;17(04, Suppl 1):90–93
6 Lachiewicz PF, Bolognesi MP, Henderson RA, Soileau ES, Vail TP. Can tantalum cones provide fixation in complex revision knee arthroplasty? Clin Orthop Relat Res 2012;470(01):199–204
7 Jensen CL, Winther N, Schrøder HM, Petersen MM. Outcome of revision total knee arthroplasty with the use of trabecular metal cone for reconstruction of severe bone loss at the proximal tibia. Knee 2014;21(06):1233–1237
8 Long WJ, Scuderi GR. Porous tantalum cones for large metaphyseal tibial defects in revision total knee arthroplasty: a minimum 2-year follow-up. J Arthroplasty 2009;24(07):1086–1092
9 Rao BM, Kamal TT, Vafaye J, Moss M. Tantalum cones for major osteolysis in revision knee replacement. Bone Joint J 2013;95-B (08):1069–1074
10 Mozella AdeP, Olivero RR, Alexandre H, Cobra AB. Use of a trabecular metal cone made of tantalum, to treat bone defects during revision knee arthroplasty. Rev Bras Ortop 2014;49(03):245–251
11 Derome P, Sternheim A, Backstein D, Malo M. Treatment of large bone defects with trabecular metal cones in revision total knee arthroplasty: short term clinical and radiographic outcomes. J Arthroplasty 2014;29(01):122–126
12 Lonner JH, Lotke PA, Kim J, Nelson C. Impaction grafting and wire mesh for uncontained defects in revision knee arthroplasty. Clin Orthop Relat Res 2002;(404):145–151
13 Toms AD, Barker RL, Jones RS, Kuiper JH. Impaction bone-grafting in revision joint replacement surgery. J Bone Joint Surg Am 2004; 86(09):2050–2060
14 Clatworthy MG, Ballance J, Brick GW, Chandler HP, Gross AE. The use of structural allograft for uncontained defects in revision total knee arthroplasty. A minimum five-year review. J Bone Joint Surg Am 2001;83(03):404–411
15 Engh GA, Ammeen DJ. Use of structural allograft in revision total knee arthroplasty in knees with severe tibial bone loss. J Bone Joint Surg Am 2007;89(12):2640–2647
16 Berend KR, Lombardi AV Jr. Distal femoral replacement in non-tumor cases with severe bone loss and instability. Clin Orthop Relat Res 2009;467(02):485–492
17 Bauman RD, Lewallen DG, Hanssen AD. Limitations of structural allograft in revision total knee arthroplasty. Clin Orthop Relat Res 2009;467(03):818–824
18 Chun CH, Kim JW, Kim SH, Kim BG, Chun KC, Kim KM. Clinical and radiological results of femoral head structural allograft for severe bone defects in revision TKA–a minimum 8-year follow-up. Knee 2014;21(02):420–423
19 Pour AE, Parvizi J, Slenker N, Purtill JJ, Sharkey PF. Rotating hinged total knee replacement: use with caution. J Bone Joint Surg Am 2007;89(08):1735–1741
20 Meneghini RM, Lewallen DG, Hanssen AD. Use of porous tantalum metaphyseal cones for severe tibial bone loss during revision total knee replacement. J Bone Joint Surg Am 2008;90(01):78–84
21 Howard JL, Kudera J, Lewallen DG, Hanssen AD. Early results of the use of tantalum femoral cones for revision total knee arthroplasty. J Bone Joint Surg Am 2011;93(05):478–484

 © 2022. Sociedade Brasileira de Ortopedia e Traumatologia. All rights reserved.

22 Radnay CS, Scuderi GR. Management of bone loss: augments, cones, offset stems. Clin Orthop Relat Res 2006;446(446):83–92
23 Villanueva-Martínez M, De la Torre-Escudero B, Rojo-Manaute JM, Ríos-Luna A, Chana-Rodriguez F. Tantalum cones in revision total knee arthroplasty. A promising short-term result with 29 cones in 21 patients. J Arthroplasty 2013;28(06):988–993
24 Potter GD III, Abdel MP, Lewallen DG, Hanssen AD. Midterm Results of Porous Tantalum Femoral Cones in Revision Total Knee Arthroplasty. J Bone Joint Surg Am 2016;98(15):1286–1291
25 Kamath AF, Lewallen DG, Hanssen AD. Porous tantalum metaphyseal cones for severe tibial bone loss in revision knee arthroplasty: a five to nine-year follow-up. J Bone Joint Surg Am 2015;97(03):216–223
26 De Martino I, De Santis V, Sculco PK, D'Apolito R, Assini JB, Gasparini G. Tantalum Cones Provide Durable Mid-term Fixation in Revision TKA. Clin Orthop Relat Res 2015;473(10):3176–3182
27 Bobyn JD, Stackpool GJ, Hacking SA, Tanzer M, Krygier JJ. Characteristics of bone ingrowth and interface mechanics of a new porous tantalum biomaterial. J Bone Joint Surg Br 1999;81(05):907–914
28 Bonanzinga T, Gehrke T, Zahar A, Zaffagnini S, Marcacci M, Haasper C. Are trabecular metal cones a valid option to treat metaphyseal bone defects in complex primary and revision knee arthroplasty? Joints 2017;6(01):58–64
29 Liu Y, Bao C, Wismeijer D, Wu G. The physicochemical/biological properties of porous tantalum and the potential surface modification techniques to improve its clinical application in dental implantology. Mater Sci Eng C Mater Biol Appl 2015;49:323–329
30 Divano S, Cavagnaro L, Zanirato A, Basso M, Felli L, Formica M. Porous metal cones: gold standard for massive bone loss in complex revision knee arthroplasty? A systematic review of current literature. Arch Orthop Trauma Surg 2018;138(06):851–863

 © 2022. Sociedade Brasileira de Ortopedia e Traumatologia. All rights reserved.