Case Series

The role of cervical pedicle screw in cervical spine trauma: A single-center retrospective study

ABSTRACT

Placement of pedicle screw in the subaxial cervical spine is a challenging and complex technique but provides significant biomechanical advantages. Despite its potential complications, the role and use of cervical pedicle screw (CPS) are growing. A literature review of the significant articles on applying pedicle screws in the subaxial cervical spine was done (articles between 1994 and 2020). Furthermore, our center´s experience of 15 years related to CPS is also discussed in this study. Transpedicular instrumentation in the subaxial cervical spine requires profound anatomical knowledge and meticulous surgical technique. This technique provides superior biomechanical stability compared to the other cervical fixation techniques. Pull-out strength of CPS is twice as compared to the lateral mass screws. There have been numerous variations in the technique of CPS, varying from open techniques to minimally invasive and the use of biomodels and templates during this procedure. Clinically, CPS can be used in different cervical trauma situations, such as fracture–dislocations, floating lateral mass, and fractures associated with ankylosing spondylitis. Despite the possibility of neurovascular injury due to the proximity of the vertebral artery, spinal cord, and spinal nerves to the cervical pedicles, scientific literature, and our center s experience show low risk, and this technique can be performed safely. CPS placement is a safe procedure, and it has great potential in the management of cervical spine trauma.

Keywords: Cervical pedicle screw, cervical spine trauma, subaxial fractures

INTRODUCTION

Although cervical spine injuries occur in only 3%–5% of blunt trauma, their implications can be catastrophic due to the risk of spinal cord injury. The subaxial region between C3 and C7 encompasses more than half of cervical injuries.[1,2] Surgical treatment is possible through anterior, posterior, or combined approaches, with several fixation techniques present in the literature. In this context, the pedicle screw described by Abumi *et al*.[3] gains importance for its biomechanical strength and ability to spare levels of arthrodesis. Its application, however, involves risk to critical neurovascular structures and presents considerable technical difficulty.

Modern techniques for instrumentation of the cervical spine have brought greater stability, with a decrease in postoperative immobilization time compared to old treatment methods. Roy-Camille, in 1964, described the use of lateral mass screws, with several other techniques having been described since then, varying the angulation and entry point.[4]

The first description of the technique of inserting pedicle screws in the subaxial spine was performed by Abumi *et al*.[3]

Access this article online	
Website: www.jcvjs.com	Quick Response Code
DOI: 10.4103/jcvjs.jcvjs_19_23	

Igor Ebert Cechin[1], Alderico Girão Campos De Barros[1], Ahsan Ali Khan[1,2], Luis Eduardo Carelli Teixeira Da Silva[1]

[1]Department of Spine Surgery, National Institute of Traumatology and Orthopedics, Rio de Janeiro, Brazil, [2]Section of Neurosurgery, The Aga Khan University, Karachi, Pakistan

Address for correspondence: Dr. Ahsan Ali Khan, Department of Spine Surgery, National Institute of Traumatology and Orthopedics, Rio de Janeiro, Brazil.
E-mail: dr.ahsankhan@hotmail.com

Submitted: 21-Feb-23 **Accepted:** 14-Apr-23
Published: 18-Sep-23

This is an open access journal, and articles are distributed under the terms of the Creative Commons Attribution-NonCommercial-ShareAlike 4.0 License, which allows others to remix, tweak, and build upon the work non-commercially, as long as appropriate credit is given and the new creations are licensed under the identical terms.

For reprints contact: WKHLRPMedknow_reprints@wolterskluwer.com

How to cite this article: Cechin IE, Barros AG, Khan AA, Silva LE. The role of cervical pedicle screw in cervical spine trauma: A single-center retrospective study. J Craniovert Jun Spine 2023;14:299-305.

in 1994 on 13 patients who had suffered traumatic injuries. Subsequently, studies on cadaveric specimens demonstrated greater pullout strength and stability of pedicle screws in relation to lateral mass screws.[5,6]

We currently have several other technical descriptions of subaxial pedicle screws in the literature: pedicle axis view, funnel technique, and percutaneous placement, among others. Each of these variations has pros and cons regarding technical difficulty, execution time, necessary instruments, and risk of neurovascular injury.

METHODS

A review of the main articles on the use of pedicle screws in the subaxial cervical spine was carried out in the Lilacs, NCBI, and SciELO databases, from 1994 to 2020, with an experimental and observational design. We add the experience of 15 years of practice of our service with the surgical technique and clinical cases demonstrating its usefulness.

DISCUSSION

Biomechanics

In an unstable spinal injury, the progression of the deformity can occur through loads considered physiological.[7] From a biomechanical point of view, it is preferable to maintain the integrity of stabilizing structures that have not been compromised.[8] The vertebral fixation device of choice should be able to control instability along the three axes of mobility of the spine, preferably if its stabilizing capacity can be achieved through a short segmental fixation while maintaining as many movable segments as possible.[8]

The literature is not extensive about biomechanical studies of pedicle screws in the subaxial cervical spine, but the results presented are optimistic about their properties. In 1994, Kotani *et al*.[9] evaluated seven methods of cervical spine reconstruction in four distinct injury patterns. Fixation using transpedicular screws was superior to conventional devices in terms of stability in multi-segment fixations, under torsional loads, and in extension.[9]

Subsequently, Jones *et al*.[6] evaluated the pull-out force between lateral mass screws and pedicle screws. Much superior results were found in pedicle fixation, with required mean values of 677N compared to 355N in lateral mass screws. Kowalski *et al*.[10] in 2000 compared, two different techniques of pedicle instrumentation: the Abumi technique and the anatomical technique. Pull-out forces were evaluated in both, and there was no significant difference.

Kothe *et al*.[11] published an *in vitro* biomechanical analysis comparing multisegmental fixations with lateral mass screws and pedicle screws. There was greater stability in the initial transpedicular fixation only under lateral tilt loads, with no difference in flexion extension or axial rotation, but with less stability loss in all directions after cyclic loads.[11]

Johnston *et al*.[11] performed a study evaluating the initial torque and pull-out force after uniplanar cyclic loads, both in lateral mass and pedicle screws. There was no initial difference in stability, but the lateral mass screws showed rapid loosening. The pull-out force was significantly higher in pedicle screws (1214N vs. 332N).[12]

APPLICATION IN TRAUMATIC INJURIES

The approach to unstable traumatic injuries of the cervical spine remains controversial about its realization: anterior, posterior, or combined. To this end, the neurological status, location of fracture traces, injury mechanism, previous osteoarticular changes, and injury time should be considered.[13]

Fractures of the adjacent pedicle and lamina are known as a floating lateral mass, accounting for 7%–16% of subaxial fractures. Lesions involving two segments are considered, with a surgical approach to maintaining physiological alignment.[14] To preserve movement, we used transpedicular fixation in lateral mass fractures without subluxation, approaching only the side of the lesion, promoting interfragmentary compression, in agreement with the study published by Jeanneret *et al*.[15] [Figure 1]. In cases of a floating lateral mass with subluxation and unilateral or bilateral

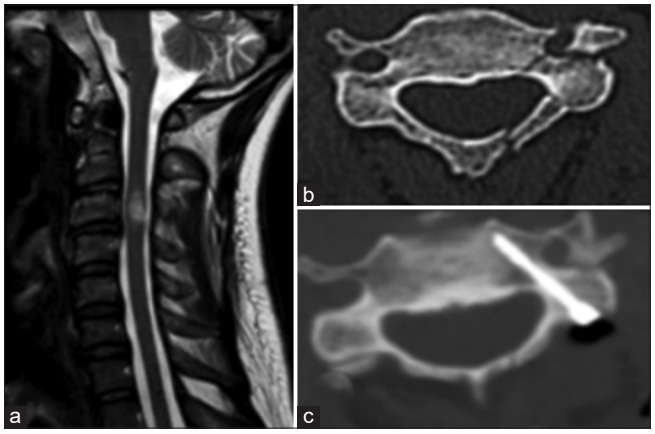

Figure 1: Male, 47-year-old. Fall from height. AO Spine C3: A0; F3; N3; M1 Frankel C. MRI showing medullary signal changes without apparent compression; without subluxation (a), Axial CT scan showing a floating lateral mass on the left in C3 (b), We opted for osteosynthesis of the lateral mass using the transpedicular technique with a 2.7 mm cannulated screw (c). MRI: Magnetic resonance imaging, CT: Computed tomography

facet dislocations, we perform monosegmental fixation with pedicle screws associated with interfragmentary compression at the site of the floating lateral mass[13,16] [Figure 2].

As described in Allen's classification, flexion-distraction injuries can result in posterior ligament rupture, unilateral or bilateral facet dislocation, with complete anterior displacement of the spine. There is biomechanical superiority of posterior fixations with pedicle screws in relation to anterior ones.[17] By combining excellent correction capacity to restore physiological sagittal alignment with a single access route for fixation, reduction, and decompression, we prefer the transpedicular instrumentation technique in these cases[17,18] [Figure 3].

Pediatric cervical spine injuries are infrequent, more common in the upper cervical region. Nevertheless, as reported by Li *et al*.,[19] subaxial pedicle instrumentation is feasible in this population and is even effective as an isolated method of stabilization in severe fracture-dislocation.[19] According to Rajasekaran *et al*.,[20] the only prerequisite for this technique in pediatric patients is a minimum pedicle width of 4 mm, which was absent in only 6.7% of the population studied.

Cervical fractures at multiple levels are usually approached by a combined approach, with stabilization through an intersomatic cage and an anterior plate reinforced by posterior fixation with lateral mass screws. However, according to a biomechanical study by Duff *et al*.,[21] cervical reconstruction with pedicle screws demonstrated more consistent stability after cyclic loads in relation to 360° mounting, being a promising alternative in these injuries.

In 2008, Hostin *et al*.[22] evaluated three rescue strategies for fixation failures with a 3.5 mm screw using the Magerl technique: Insertion of a 4.0 mm screw in the same trajectory; use of the Roy-Camille technique; a transpedicular fixation. The pedicle screw proved biomechanically superior, proving its usefulness as a salvage method in cervical instrumentation.[22]

Cervical spine fractures in patients with ankylosing spondylitis are objects of study and redoubled concern for specialists. The development of a rigid spine, associated with osteoporosis as the disease progresses, generates a more fragile bone structure with little capacity to resist loads, susceptible to fractures even after light trauma.[23,24] Due to the large lever arm and poor bone quality, short assemblies tend to fail.[23] While isolated anterior fixations have a failure rate of around 50%, posterior fixation is considered sufficient by several authors,[25] with a classic recommendation to involve 3–4 cranial and caudal segments in the fracture.[24] However, due to the biomechanical advantage of the subaxial pedicle screw, we agree with Chon and Park and Park *et al*. we have performed fixation of only two segments above and below the fracture[24,25] [Figure 4].

INSTRUMENTATION TECHNIQUES

Proper insertion of screws involves precise identification of the entry point by the trajectory angle. If one of the two fails, the positioning will be compromised.[26] Subaxial pedicular instrumentation is a surgical procedure with a long learning curve, with insertion accuracy ranging in the literature from 16.8% to 97%.[27] Several techniques have been published since

Figure 2: Male, 28-year-old. Dive in shallow water. AO Spine C5-C6 C F4 N1. Frankel E, paresthesia in C6 territory on the right. Tomography showing fracture-dislocation C5-C6 (a) with a floating lateral mass at C5 on the right (c). Bilateral C5-C6 pedicle fixation was performed with reduced dislocation. The axial CT section demonstrates the path of the pedicle screws at the level of C5, with compression of the interfragmentary on the right (d) promoting stability, associated with monosegmental arthrodesis (b). CT: Computed tomography

the original description in 1994,[3] several techniques have been published.[26] The senior author (L.E.C.T.S.) has 15 years of experience with subaxial pedicle screws, having started his series in 2005 using monoaxial screws and plates [Figure 5]. Currently, polyaxial screws and modular systems are the first choices for performing this procedure.

The manual procedure with the aid of lateral fluoroscopy reported by Abumi *et al*.[8] is considered the conventional technique for subaxial pedicle screw insertion.[13] After the dissection exposes the lateral margins of the facets, the entry point is identified slightly lateral to the lateral mass, close to the posterior margin of the superior articular surface. The cortex at the entry point is ground with a high-speed drill, and the hole is enlarged to accommodate the screw, allowing direct visualization of the pedicle entry. Both screw depth and direction are confirmed by lateral fluoroscopic imaging.[3]

Yukawa *et al*.[28] described a method in 2006 for determining the entry point and trajectory of the screw, known as the "pedicle axis-view technique." A perfect lateral image of the cervical spine is obtained through fluoroscopy. After that, the C-arm rotates until it presents a circular image of the cortical wall of the pedicle in the transverse plane, ranging from 30° to 55° of inclination in the mid-sagittal plane. The entry point is at the center of the cortical circle, and entry point is initiated through a perforator and then a guidewire is introduced, and its position is confirmed by the pedicle's lateral image and axial view. Milling is performed before inserting the screw [Figure 6].

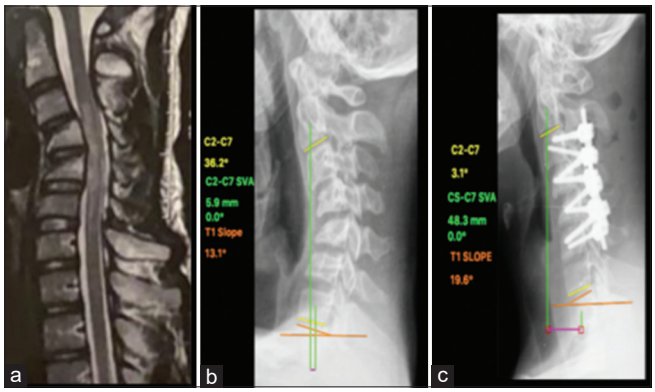

Figure 3: Male, 16-year-old. Motorcycle accident. AO Spine: C4-C5 B2 (C4:A1; C5:A1; F4; N3)/C5-C6 B2 (N3). Frankel C. 30 days of evolution. Injury by a flexion-distraction mechanism at C4-C5. MRI is demonstrating spinal cord contusion and posterior ligament injury (a), Radiograph showing regional kyphosis and C4-C5 facet subluxation (b), C3-C6 bilateral pedicle instrumentation was performed with correction of sagittal alignment (c)

Karaikovic *et al*.,[29] in a cadaveric study, developed an instrumentation technique known as the "funnel technique." In this technique, the outer cortex of the lamina was removed over the entrance of the pedicle, the authors identified the medial arch of the pedicle and its cancellous nucleus with the aid of a curette. By assuming that the pedicle has a funnel shape with a broad posterior base, the medial cortical wall is used as a guide.[29] A technical modification described in 2017 suggests that, after a small laminoforaminotomy and identification of the cancellous nucleus of the pedicle, the path should be carried out in such a way as to expose the screw thread discreetly. This change is intended to provide greater security regarding the nonviolation of the lateral wall.[30]

Schaefer *et al*.[31] published a percutaneous cervical pedicle instrumentation procedure. After positioning, an anteroposterior, lateral, oblique, and axial view of the pedicles are fluoroscopically obtained. The skin entry point is made by placing needles at 40 degrees of convergence with the lateral edge of the estimated entry point on the pedicle. After skin incision, fascia, and muscle dissection, insertion of a trocar with fluoroscopic control is performed. After an initial drill, a drill is used again to make the path, followed by milling and inserting the screw. Images are performed at each step to ensure correct positioning.[31]

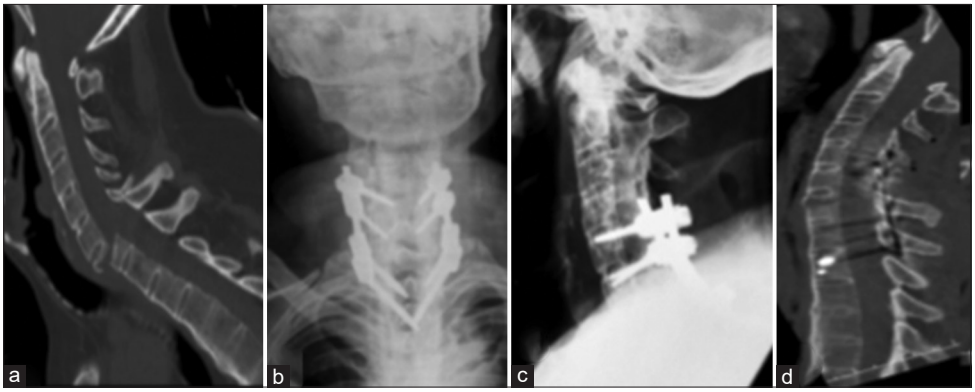

Figure 4: Male, 50-year-old, ankylosing spondylitis. Fall from height. AO Spine C6-C7: C (C7 B3; F4 bl; N0; M3). Frankel E. CT showing a fracture with translation at the level of C7 (a), We opted for reduction and posterior fixation with C5-T2 pedicle fixation, including two levels above and below the lesion (b and c), Control tomography demonstrates adequate reduction (d). CT: Computed tomography

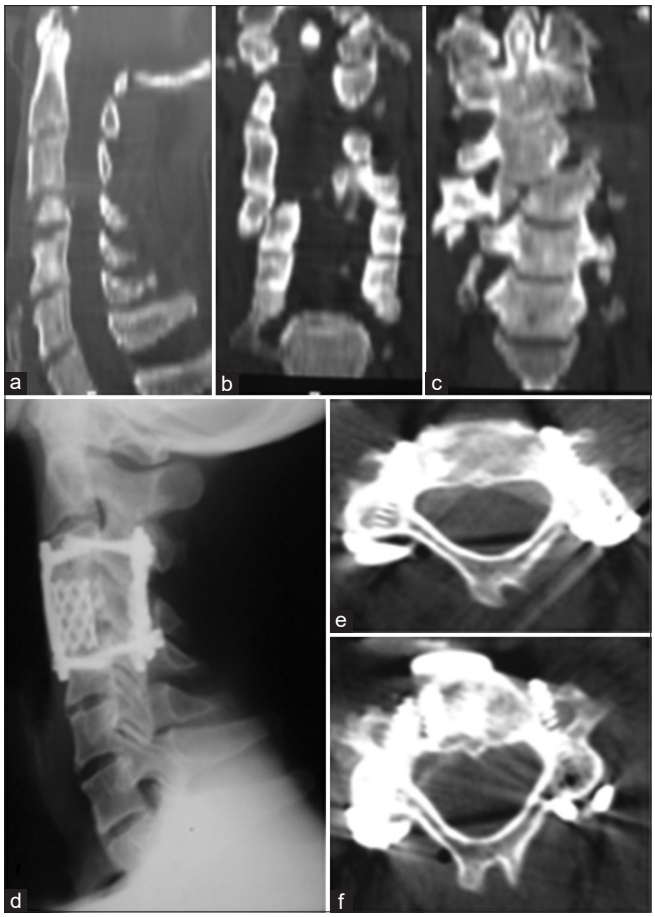

Figure 5: Male, 47-year-old. Car accident. AO Spine C3-C4: C (C4 A4; F4; N3). Frankel C. CT showing fracture of the body of C4 (a) with the lateral translation of the cervical spine (b and c), C4 corpectomy was performed via an anterior approach and fixation with a cervical plate, complemented by segmental posterior fixation using a fixed-angle pedicle screw and plate (d), Control tomography shows an adequate course of screws at C3 (e), and violation of the lateral cortex of the pedicle on the left at C5 (f), without clinical repercussions. CT: Computed tomography

In 2012, Lee *et al*.[32] presented a modification of the original Abumi technique called the "key slot technique." This procedure considers the entry point as perpendicular to the pedicle axis. A keyhole-like hole is made in the medial half of the lateral mass. The shape is a rectangle in the coronal plane and a right triangle in the axial plane. In the sagittal plane, the depth is two-thirds the thickness of the lateral mass. A curved probe with is used to complete the technique.[32]

The "freehand" technique was developed by Park *et al*.,[33] with an accuracy of 94.1%. The entry point is determined by analyzing axial, and sagittal computed tomography scans: at the level of the notch in the sagittal plane and medial to the lateral edge of the superior articular process for a distance equivalent to a quarter of its width in the axial plane. An initial hole is made with a drill, after which a specially designed curved probe is carefully inserted. Its trajectory seeks contact with the medial wall, which is hardly perforated due to

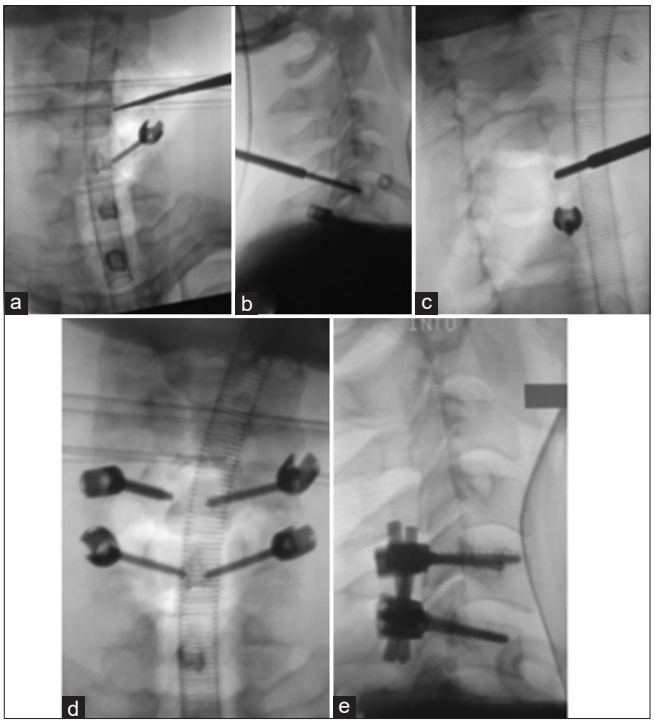

Figure 6: "Pedicle Axis View" instrumentation technique. (a) Anteroposterior fluoroscopic image of the cervical spine, with a probe positioned in the medial cortex of the pedicle, (b) Lateral fluoroscopic image demonstrating probe positioning at the junction of the pedicle with the vertebral body, in agreement with the previous image, (c) True anteroposterior fluoroscopic view of the pedicle, obtained at a 30°–55° angle of the device. It is observed that there is no violation of the medial cortex of the pedicle, (d) Anteroposterior fluoroscopic image with the 4 screws properly positioned, (e) Lateral radioscopy image performed after placement of nails and blockers

its thickness. After making the path, it is palpated– if the tactile feedback is suggestive of malposition, the procedure is abandoned and converted to a lateral mass screw. This situation was described in 7.8% of cases.[33]

Currently, there are systems for pedicle instrumentation navigated by three-dimensional images, which provide greater accuracy in positioning and less surgical time and bleeding. However, the high cost does not allow its availability in most hospitals.[34] Another technological advancement is the three-dimensional template and the use of biomodels, designed according to the individual characteristics of each patient.[34,35] Its use is an alternative to navigation, and it increases surgical precision.

COMPLICATIONS

Due to the proximity of the subaxial cervical pedicles with critical neurovascular structures including the spinal cord, nerve roots, and vertebral artery, catastrophic events can result from improper positioning of screws. Complications related to the procedure involve perforation of the pedicle

with neurovascular injury (most common), indirect nerve root injury from foraminal stenosis, loosening or avulsion, loss of reduction, pseudarthrosis, and infection.[27] Kast *et al*.[36] classified the placement of screws as correctly positioned (cortical perforation up to 1 mm), minor perforations (lateral, ventral, or in the recess without contact with the dural sac), and major perforations (vertebral foramen stenosis >25%, caudal perforation with potential risk or injury to the root).[33] Uehara *et al*.[37] evaluated complications as grade I (no perforation), grade II (<50% of the screw diameter), and grade III (>50% of the screw diameter).[34] Similarly, Neo *et al*.[38] established a classification in 4°, both for lateral and medial deviation: Grade 0, no deviation; screw contained in the pedicle. Grade 1 deviation <2 mm. Grade 2 deviation between 2 and 4 mm. Grade 3 deviation >4 mm, is considered complete.[38]

Most perforations occur in a lateral direction, which can cause injury to the vertebral artery, with consequent hemorrhage and ischemia[34] however, arterial injuries are rare.[13,37] This can be explained by the fact that the vertebral artery does not occupy the entire area of the transverse foramen,[39] and most perforations are of a lesser degree.[36,37] An anomalous vertebral artery has a greater chance of injury,[27] and preoperative studies with magnetic resonance angiography/tomography are indicated.[13] An alternative technique should be considered if any anomaly is detected, such as a lateral mass screw.[13] In our experience, we did not have any case of serious injury to the vertebral artery with clinical repercussions.

Dural sac and spinal cord injuries are potential complications, although medial cortical perforations are less frequent. Root involvement can occur due to cranial or caudal malposition of a screw, with a more significant risk when directed cranially. Iatrogenic foraminal stenosis is also indirectly possible by an excessive reduction of spondylolisthesis or an increase in cord and root tension after spinal alignment correction.[34]

CONCLUSION

Pedicle fixation of the subaxial cervical spine is a beneficial method in cases of traumatic injuries, through its biomechanical superiority, shorter fixations, and a single access route, in addition to being an option as a salvage screw. Several techniques are described for their application, and it is up to the surgeon to judge which one best fits his experience and may even perform an overlap between these techniques. The most feared complication is an injury to the vertebral artery, which is a rare event even when the lateral wall is perforated. Improved navigated techniques or three-dimensional biomodels and templates should increase positioning accuracy, reducing complications and operative time.

Declaration of patient consent

The authors certify that they have obtained all appropriate patient consent forms. In the form the patient (s) has/have given his/her/their consent for his/her/their images and other clinical information to be reported in the journal. The patients understand that their names and initial s will not be published and due efforts will be made to conceal their identity, but anonymity cannot be guaranteed.

Financial support and sponsorship

Nil.

Conflicts of interest

There are no conflicts of interest.

REFERENCES

1. Kwon BK, Vaccaro AR, Grauer JN, Fisher CG, Dvorak MF. Subaxial cervical spine trauma. J Am Acad Orthop Surg 2006;14:78-89.
2. Feuchtbaum E, Buchowski J, Zebala L. Subaxial cervical spine trauma. Curr Rev Musculoskelet Med 2016;9:496-504.
3. Abumi K, Itoh H, Taneichi H, Kaneda K. Transpedicular screw fixation for traumatic lesions of the middle and lower cervical spine: Description of the techniques and preliminary report. J Spinal Disord 1994;7:19-28.
4. Joaquim AF, Mudo ML, Tan LA, Riew KD. Posterior subaxial cervical spine screw fixation. Rev Tech Glob Spine J 2018;8:751-60.
5. Schmidt R, Wilke HJ, Claes L, Puhl W, Richter M. Pedicle screws enhance primary stability in multilevel cervical corpectomies: biomechanical *in vitro* comparison of different implants including constrained and nonconstrained posterior instumentations. Spine (Phila Pa 1976) 2003;28:1821-8.
6. Jones EL, Heller JG, Silcox DH, Hutton WC. Cervical pedicle screws versus lateral mass screws. Anatomic feasibility and biomechanical comparison. Spine (Phila Pa 1976) 1997;22:977-82.
7. White III, AA, Johnson RM, Panjabi MM, Southwick WO. Biomechanical analysis of clinical stability in the cervical spine. Clinical Orthopaedics and Related Research® 1975;109:85-96.
8. Ludwig SC, Kramer DL, Vaccaro AR, Albert TJ. Transpedicle screw fixation of the cervical spine. Clinical Orthopaedics and Related Research (1976-2007) 1999;359:77-88.
9. Kotani Y, Cunningham BW, Abumi K, McAfee PC. Biomechanical analysis of cervical stabilization systems. An assessment of transpedicular screw fixation in the cervical spine. Spine (Phila Pa 1976) 1994;19:2529-39.
10. Kowalski JM, Ludwig SC, Hutton WC, Heller JG. Cervical spine pedicle screws. Spine 2000;25:2865-7.
11. Kothe R, Rüther W, Schneider E, Linke B. Biomechanical analysis of transpedicular screw fixation in the subaxial cervical spine. Spine (Phila Pa 1976) 2004;29:1869-75.
12. Johnston TL, Karaikovic EE, Lautenschlager EP, Marcu D. Cervical pedicle screws versus lateral mass screws: Uniplanar fatigue analysis and residual pullout strengths. Spine J 2006;6:667-72.
13. Jung YG, Lee S, Jeong SK, Kim M, Park JH. Subaxial cervical pedicle screw in traumatic spinal surgery. Korean J Neurotrauma 2020;16:18-27.
14. Manoso MW, Moore TA, Agel J, Bellabarba C, Bransford RJ. Floating

lateral mass fractures of the cervical spine. Spine (Phila Pa 1976) 2016;41:1421-7.
15. Jeanneret B, Gebhard JS, Magerl F. Transpedicular screw fixation of articular mass fracture-separation: Results of an anatomical study and operative technique. J Spinal Disord 1994;7:222-9.
16. Park JH, Roh SW, Rhim SC. A single-stage posterior approach with open reduction and pedicle screw fixation in subaxial cervical facet dislocations. J Neurosurg Spine 2015;23:35-41.
17. Tofuku K, Koga H, Yone K, Komiya S. Distractive flexion injuries of the subaxial cervical spine treated with a posterior procedure using cervical pedicle screws or a combined anterior and posterior procedure. J Clin Neurosci 2013;20:697-701.
18. Abumi K, Ito M, Sudo H. Reconstruction of the subaxial cervical spine using pedicle screw instrumentation. Spine (Phila Pa 1976) 2012;37:E349-56.
19. Li C, Li L, Duan J, Zhang L, Liu Z. Surgical treatment for old subaxial cervical dislocation with bilateral locked facets in a 3-year-old girl: A case report. Medicine (Baltimore) 2018;97:e0553.
20. Rajasekaran S, Kanna PR, Shetty AP. Safety of cervical pedicle screw insertion in children: A clinicoradiological evaluation of computer-assisted insertion of 51 cervical pedicle screws including 28 subaxial pedicle screws in 16 children. Spine (Phila Pa 1976) 2012;37:E216-23.
21. Duff J, Hussain MM, Klocke N, Harris JA, Yandamuri SS, Bobinski L, *et al.* Does pedicle screw fixation of the subaxial cervical spine provide adequate stabilization in a multilevel vertebral body fracture model? An *in vitro* biomechanical study. Clin Biomech (Bristol, Avon) 2018;53:72-8.
22. Hostin RA, Wu C, Perra JH, Polly DW, Akesen B, Wroblewski JM. A biomechanical evaluation of three revision screw strategies for failed lateral mass fixation. Spine (Phila Pa 1976) 2008;33:2415-21.
23. Cornefjord M, Alemany M, Olerud C. Posterior fixation of subaxial cervical spine fractures in patients with ankylosing spondylitis. Eur Spine J 2005;14:401-8.
24. Chon H, Park JH. Cervical vertebral body fracture with ankylosing spondylitis treated with cervical pedicle screw: A fracture body overlapping reduction technique. J Clin Neurosci 2017;41:150-3.
25. Yan L, Luo Z, He B, Liu J, Hao D. Posterior pedicle screw fixation to treat lower cervical fractures associated with ankylosing spondylitis: A retrospective study of 35 cases. BMC Musculoskelet Disord 2017;18:81.
26. Koller H, Robinson Y. (Eds.). Cervical Spine Surgery: Standard and Advanced Techniques: Cervical Spine Research Society-Europe Instructional Surgical Atlas. Springer. 2019. p. 449-54.
27. Tukkapuram VR, Kuniyoshi A, Ito M. A review of the historical evolution, biomechanical advantage, clinical applications, and safe insertion techniques of cervical pedicle screw fixation. Spine Surg Relat Res 2019;3:126-35.
28. Yukawa Y, Kato F, Yoshihara H, Yanase M, Ito K. Cervical pedicle screw fixation in 100 cases of unstable cervical injuries: Pedicle axis views obtained using fluoroscopy. J Neurosurg Spine 2006;5:488-93.
29. Karaikovic EE, Yingsakmongkol W, Gaines RW Jr. Accuracy of cervical pedicle screw placement using the funnel technique. Spine (Phila Pa 1976) 2001;26:2456-62.
30. Lee JH, Choi BK, Han IH, Choi WG, Nam KH, Kim HS. Cervical pedicle screw placement using medial funnel technique. Korean J Spine 2017;14:84-8.
31. Schaefer C, Begemann P, Fuhrhop I, Schroeder M, Viezens L, Wiesner L, *et al.* Percutaneous instrumentation of the cervical and cervico-thoracic spine using pedicle screws: Preliminary clinical results and analysis of accuracy. Eur Spine J 2011;20:977-85.
32. Lee SH, Kim KT, Abumi K, Suk KS, Lee JH, Park KJ. Cervical pedicle screw placement using the "key slot technique": The feasibility and learning curve. J Spinal Disord Tech 2012;25:415-21.
33. Park JH, Jeon SR, Roh SW, Kim JH, Rhim SC. The safety and accuracy of freehand pedicle screw placement in the subaxial cervical spine: A series of 45 consecutive patients. Spine (Phila Pa 1976) 2014;39:280-5.
34. Jung YG, Jung SK, Lee BJ, Lee S, Jeong SK, Kim M, *et al.* The subaxial cervical pedicle screw for cervical spine diseases: The review of technical developments and complication avoidance. Neurol Med Chir (Tokyo) 2020;60:231-43.
35. Texeira da Silva LE, Cuéllar DJ, Campos de Barros AG, Khan AA. Three-dimensional biomodel use in the surgical management of basilar invagination with congenital cervical scoliosis; correction by unilateral C1-C2 facet distraction. J Craniovertebr Junction Spine 2020;11:347-50.
36. Kast E, Mohr K, Richter HP, Börm W. Complications of transpedicular screw fixation in the cervical spine. Eur Spine J 2006;15:327-34.
37. Uehara M, Takahashi J, Ikegami S, Mukaiyama K, Kuraishi S, Shimizu M, *et al.* Screw perforation features in 129 consecutive patients performed computer-guided cervical pedicle screw insertion. Eur Spine J 2014;23:2189-95.
38. Neo M, Sakamoto T, Fujibayashi S, Nakamura T. The clinical risk of vertebral artery injury from cervical pedicle screws inserted in degenerative vertebrae. Spine (Phila Pa 1976) 2005;30:2800-5.
39. Abumi K, Shono Y, Ito M, Taneichi H, Kotani Y, Kaneda K. Complications of pedicle screw fixation in reconstructive surgery of the cervical spine. Spine (Phila Pa 1976) 2000;25:962-9.