REV BRAS ORTOP. 2015;50(6):743–746

RBO REVISTA BRASILEIRA DE ORTOPEDIA

www.rbo.org.br

Case report

Avulsion fracture of the posterior cruciate ligament in an uncommon location associated with distal injury to the patellar ligament☆

Rodrigo Pires e Albuquerque, Idemar Monteiro da Palma, Hugo Cobra, Alan de Paula Mozella, Victor Vaques*

Centro de Cirurgia do Joelho, Instituto Nacional de Traumatologia e Ortopedia (Into), Rio de Janeiro, RJ, Brazil

ARTICLE INFO

Article history:
Received 4 October 2014
Accepted 26 November 2014
Available online 18 October 2015

Keywords:
Knee
Posterior cruciate ligament
Bone fractures

ABSTRACT

Avulsion fractures of the posterior cruciate ligament in unusual locations are rare injuries. We report the first case in the literature of an avulsion fracture of the posterior cruciate ligament associated with distal injury to the patellar ligament. The aim of this study was to present a novel case, the therapy used and the clinical follow-up.

© 2015 Sociedade Brasileira de Ortopedia e Traumatologia. Published by Elsevier Editora Ltda. All rights reserved.

Fratura avulsão do ligamento cruzado posterior em uma localização incomum associada a lesão distal do ligamento patelar

Palavras-chave:
Joelho
Ligamento cruzado posterior
Fraturas ósseas

RESUMO

A fratura avulsão do ligamento cruzado posterior em localização não usual é uma lesão rara. Relatamos o primeiro caso da literatura de uma fratura avulsão do ligamento cruzado posterior associada a lesão distal do ligamento patelar. O objetivo deste estudo foi apresentar um caso inédito, a terapêutica adotada e o seguimento clínico.

© 2015 Sociedade Brasileira de Ortopedia e Traumatologia. Publicado por Elsevier Editora Ltda. Todos os direitos reservados.

☆ Study carried out at Centro de Cirurgia do Joelho, Instituto Nacional de Traumatologia e Ortopedia (Into), Rio de Janeiro, RJ, Brazil.

* *Corresponding author.*
E-mail: rodalbuquerque19@gmail.com (R.P. e Albuquerque).

http://dx.doi.org/10.1016/j.rboe.2015.10.004

2255-4971/© 2015 Sociedade Brasileira de Ortopedia e Traumatologia. Published by Elsevier Editora Ltda. All rights reserved.

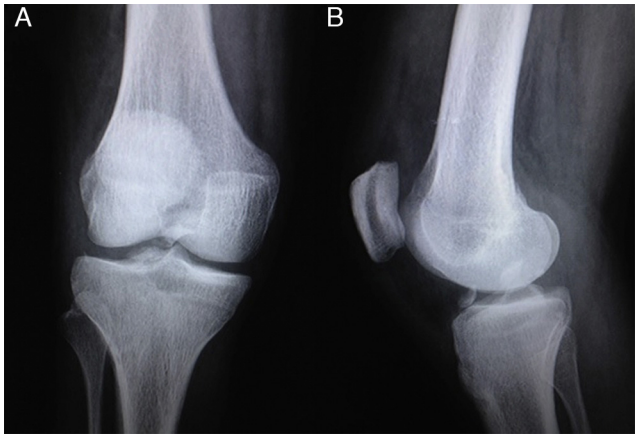

Fig. 1 – Preoperative radiography of the right knee (A) AP view and (B) profile view.

Introduction

The avulsion fracture of the posterior cruciate ligament (PCL) is considered a rare injury.[1] The unusual location of this lesion, as well as the fact that it occurred simultaneously with the distal avulsion of the ipsilateral patellar ligament, makes this case even more unusual.

The objective of this research was to present the first case of the avulsion fracture of PCL in an unusual location, associated with distal rupture of the ipsilateral patellar ligament.

Case report

A 17-year-old male, healthy individual, who suffered trauma due to a motorcycle accident, immediately developed pain, hemarthrosis and inability to walk. The patient was taken to the emergency room and was transferred to our institute one week after suffering the injury. Physical examination disclosed ++/++++ edema in his right knee and range of motion of 30–70°.

The right knee radiography showed a tibial bone fragment located in the intercondyle with preserved patellar height (Fig. 1). Magnetic resonance imaging (MRI) of the right knee was performed to better clarify the lesion and plan the surgical approach, considering that clinical examination was hindered by the presence of hemarthrosis and joint limitation. The right knee MRI showed distal patellar ligament rupture, and an avulsion fracture of the PCL with a bone fragment located in the intercondyle (Fig. 2).

The surgical procedure took place two days after admission, with the patient in the supine position. A tourniquet was used and an anterior straight incision was made in the knee to reach the patellar ligament, whereas another posteromedial incision was made with the knee bent to reach the avulsion fracture of the PCL. The surgical technique employed was the open reduction and osteosynthesis, with a 3.5 mm cannulated screw with a full screw thread bolt for the avulsion fracture of PLC (Fig. 3). Osteosynthesis was tested by careful bending the knee joint. Regarding the patellar ligament, a distal rupture

Fig. 2 – Preoperative MRI of the right knee.

was observed, which was sutured with transosseous holes and 2.0 ethibond wire.

A long knee immobilizer was used for six weeks of the postoperative period, which was removed to perform active rehabilitation exercises to prevent quadriceps atrophy. The range of motion went from 0 to 120° and total knee function was attained within six months.

The patient was reevaluated after one week, 15 days, one month, 45 days, two months and after that, monthly until the sixth month of evolution, when the consultations occurred quarterly. Patient follow-up was carried out for one year by clinical and radiographic control and he returned to his usual activities. These regular activities were walking without pain complaints and recreational soccer twice a week. In the functional knee evaluation, we used the modified Lysholm

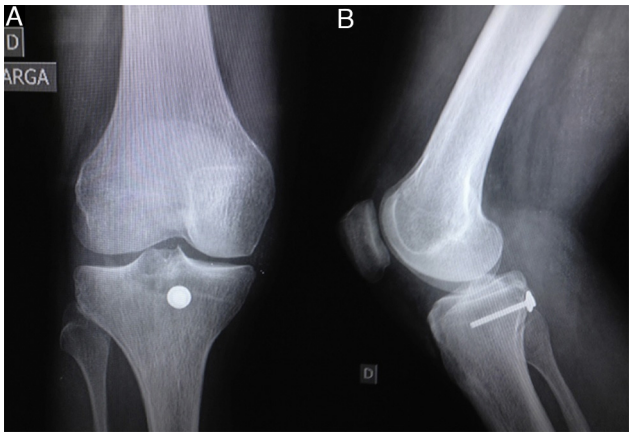

Fig. 3 – Postoperative radiography of the right knee (A) AP view and (B) profile view.

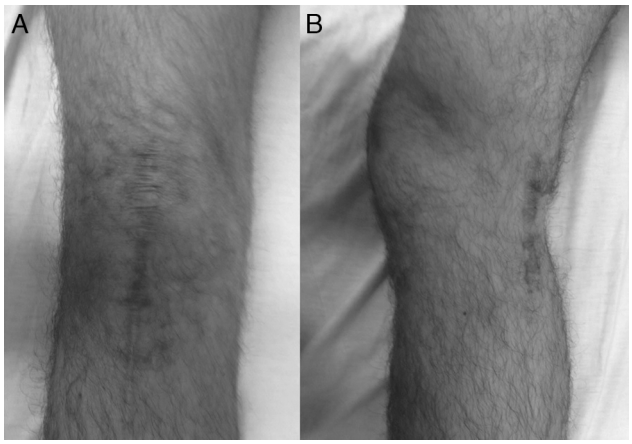

Fig. 4 – Surgical access routes in the late postoperative period of the right knee (A) anterior and (B) posteromedial.

system,[2] which had shown poor results in the preoperative analysis. In contrast, in postoperative analysis, an average of 95 points was obtained, which is considered an excellent average according to the same evaluation system (Figs. 4 and 5A, B).

Discussion

Among the isolated lesions of the PLC, the one caused by tibial bone avulsion is the one with the greatest consensus in the literature regarding the surgical indication and early intervention,[3] a concept we agree with and support.

The isolated lesion by avulsion of the tibial insertion of the PCL is more frequent in young individuals and its nature is essentially traumatic.[4] Motorcycle accidents are the major cause of such lesions.[4] Our case report corroborates these claims. According to Trickey,[5] the usual mechanism of the avulsion fracture of the PCL is an anterior tibial trauma with the knee flexed. We believe this was the mechanism of injury suffered by our patient. The literature showed only one article that mentioned the unusual location of the avulsed PCL fragment in the intercondyle.[6] As a result, we observed the rarity of this case and the relevance of its publication.

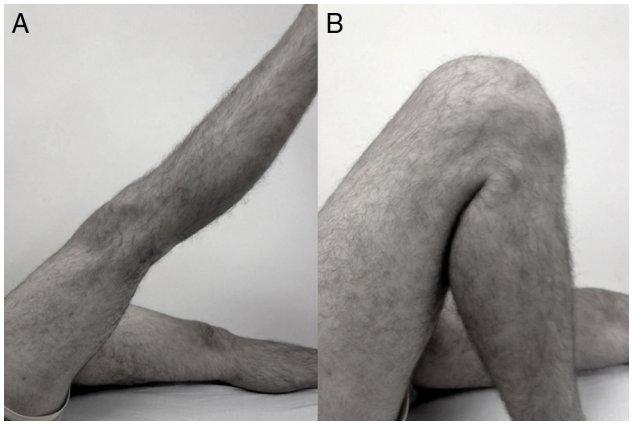

Fig. 5 – Postoperative clinical evaluation. (A) Knee extension and (B) knee flexion.

The controversy regarding the treatment of the avulsion fracture of the PCL lies in the chosen access route. As a result, we chose the posteromedial surgical approach of the knee.[7] We chose the approach with two incisions due to the simultaneous presence of the distal insertion lesion of the patellar ligament and avulsion fracture of the PCL. Furthermore, the posteromedial access avoids positioning the patient in the prone position, and there is no need for general anesthesia.

Clinical evaluation is essential, but imaging assessment is complementary and of utmost importance in assessing the size and location of the fragment. Knee radiographies are the first complementary tests to be ordered. Radiographic examination showed the patella in its normal height. It is noteworthy that an isolated PCL lesion is rare and the MRI can disclose the presence of associated lesions. In our case report, the knee MRI confirmed the avulsed fragment of PCL in the intercondyle and the distal patellar ligament injury. MRI was essential to prevent the patellar ligament lesion from being neglected.

Another controversy is the type of fixation in the avulsed fragment of PLC.[7] As a result, we always chose to use imaging tests with improved detailing of the bone fragment when compared to conventional radiographies. We think that the MRI or CT help in surgical planning. It is not unusual to use two types of devices in the intraoperative period and during surgery, we choose between screws or anchors.

Postoperatively, there is a controversy between keeping the knee immobilized or not, due to the associated lesions. One must remember that this lesion occurred in an adolescent. In patients in this age group, medical recommendations are more likely to be disregarded.[8] The immature skeleton has a lower risk of joint stiffness when compared to that of the adult population.[8] As a result, we support the use of a brace for six weeks, with daily removal to perform range of motion exercises and muscle strengthening.

The main objectives of a good treatment are the correct diagnosis and early repair of the lesions to achieve a better functional outcome.

Conflicts of interest

The authors declare no conflicts of interest.

REFERENCES

1. Bali K, Prabhakar S, Saini U, Dhillon MS. Open reduction and internal fixation of isolated PCL fossa avulsion fractures. Knee Surg Sports Traumatol Arthrosc. 2012;20(2):315–21.
2. Tegner Y, Lysholm J. Rating systems in the evaluation of knee ligament injuries. Clin Orthop Relat Res. 1985;198: 43–9.
3. Chiu FY, Wu JJ, Hsu HC, Lin L, Lo WH. Management of avulsion injury of the PCL with reattachment. Injury. 1994;25(5): 293–5.
4. Hughston JC, Bowden JA, Andrews JR, Norwood LA. Acute tears of the posterior cruciate ligament. Results of operative treatment. J Bone Joint Surg Am. 1980;62(3):438–50.
5. Trickey EL. Injuries to the posterior cruciate ligament: diagnosis and treatment of early injuries and reconstruction of late instability. Clin Orthop Relat Res. 1980;147:76–81.

6. Nizlan MN, Suhail A, Samsudin OC, Masbah O. An unusual radiographic presentation of posterior cruciate ligament avulsion fracture. Med J Malays. 2004;59 Suppl. F: 65–8.
7. Zhang X, Cai G, Xu J, Wang K. A minimally invasive postero-medial approach with suture anchors for isolated tibial avulsion fracture of the posterior cruciate ligament. Knee. 2013;20(2):96–9.
8. Albuquerque RP, Giordano V, Carvalho ACP, Puell T, Albuquerque MP, Amaral NP. Fratura avulsão bilateral e simultânea da tuberosidade tibial em uma adolescente: relato de caso e terapêutica adotada. Rev Bras Ortop. 2012;47(3):381–3.