Article published online: 2023-10-30

MRI is a Reliable Method for Measurement of Critical Shoulder Angle and Acromial Index

A ressonância magnética é um método confiável para medida do ângulo crítico do ombro e do índice acromial

Márcio Schiefer[1,2] Erika Naliato[1] Roberto Oliveira[3] Leonardo Tadeu do Carmo[3]
César Rubens da Costa Fontenelle[1] Geraldo da Rocha Motta Filho[2]

[1] Adjunct professor, Department of Orthopaedics, Medicine School, Universidade Federal do Rio de Janeiro (UFRJ), Rio de Janeiro, RJ, Brazil
[2] Orthopedic surgeon, National Institute of Trauma and Orthopedics Rio de Janeiro, RJ, Brazil
[3] Orthopedic surgeon, former Shoulder and Elbow fellow at National Institute of Trauma and Orthopedics, Rio de Janeiro, RJ, Brazil

Address for correspondence Márcio Schiefer, MD, MSc, PhD, Av. Ataulfo de Paiva, 1120 - SALA 513 - Leblon, 22440-035, Rio de Janeiro, RJ, Brazil (e-mail: marcioschiefer@hotmail.com).

Rev Bras Ortop 2023;58(5):e719–e726.

Abstract

Objective The objectives of this study are to compare absolute values of acromial index (AI) and critical shoulder angle (CSA) obtained in both radiographs and magnetic resonance image (MRI) of the shoulder; and to compare the interobserver and intra-observer agreement for AI and CSA values measured in these image modalities.

Methods Patients who had medical indication of investigating shoulders conditions through radiographs and MRI were included. Images were taken to two fellowship-trained shoulder surgeons, which conducted measurements of AI and CSA in radiographs and in MRI. Twelve weeks after the first evaluation, a second evaluation was conducted. Inter- and intra-observer reliability was presented as an Intraclass Correlation Coefficient (ICC) and agreement was classified according to Landis & Koch criteria. The differences between two measurements were evaluated using Bland-Altman plots.

Results 134 shoulders in 124 subjects were included. Mean intra-observer ICC for CSA in X-rays and in MRI were 0.936 and 0.940, respectively; for AI, 0.908 and 0.022. Mean inter-observer ICC for CSA were 0.892 and 0.752 in X-rays and MRI respectively; for AI, ICC values were 0.849 and 0.685. All individual analysis reached statistical power ($p < 0.001$). Mean difference for AI values measured in X-rays and in MRI was 0.01 and 0.03 for observers 1 and 2, respectively. Mean difference for CSA values obtained in X-rays and MRI was 0.16 and 0.58 for observers 1 and 2, respectively.

Keywords
- acromion
- magnetic resonance imaging
- shoulder impingement syndrome
- radiography
- rotator cuff tear

Work developed in the National Institute of Trauma and Orthopedics Rio de Janeiro, RJ, Brazil.

received
March 19, 2023
accepted
May 5, 2023

DOI https://doi.org/10.1055/s-0043-1776136.
ISSN 0102-3616.

© 2023. Sociedade Brasileira de Ortopedia e Traumatologia. All rights reserved.
This is an open access article published by Thieme under the terms of the Creative Commons Attribution-NonDerivative-NonCommercial-License, permitting copying and reproduction so long as the original work is given appropriate credit. Contents may not be used for commercial purposes, or adapted, remixed, transformed or built upon. (https://creativecommons.org/licenses/by-nc-nd/4.0/)
Thieme Revinter Publicações Ltda., Rua do Matoso 170, Rio de Janeiro, RJ, CEP 20270-135, Brazil

Conclusion Both MRI and X-rays provided high intra- and interobserver agreement for measurement of AI and CSA. Absolute values found for AI and CSA were highly correlated in both image modalities. These findings suggest that MRI is a suitable method to measure AI and CSA.
Level of Evidence II, Diagnostic Study.

Resumo

Objetivo Os objetivos deste estudo foram comparar os valores absolutos do índice acromial (IA) e do ângulo crítico do ombro (ACO) obtidos em radiografias e ressonâncias magnéticas (RM) do ombro e comparar a concordância interobservador e intraobservador dos valores de IA e ACO medidos nessas modalidades de imagem.
Métodos Pacientes com indicação médica de investigação de doenças dos ombros por meio de radiografias e RM foram incluídos no estudo. As imagens foram levadas para dois cirurgiões de ombro treinados que realizaram medidas de IA e ACO em radiografias e RM. Doze semanas após a primeira avaliação, uma segunda avaliação foi realizada. A confiabilidade inter e intraobservador foi apresentada como coeficiente de correlação intraclasse (CCI) e a concordância foi classificada segundo os critérios de Landis e Koch. As diferenças entre duas medidas foram avaliadas por meio de gráficos de Bland-Altman.
Resultados Cento e trinta e quatro ombros de 124 indivíduos foram incluídos no estudo. O CCI intraobservador médio para ACO em radiografias e RM foi 0,936 e 0,940, respectivamente; para IA, foi 0,908 e 0,022. O CCI interobservador médio para ACO foi 0,892 e 0,752 em radiografias e RM, respectivamente; para IA, os valores de CCI foram 0,849 e 0,685. Todas as análises individuais apresentaram poder estatístico ($p < 0{,}001$). A diferença média dos valores de IA em radiografias e RM foi 0,01 e 0,03 para os observadores 1 e 2, respectivamente. A diferença média dos valores de ACO em radiografias e RM foi 0,16 e 0,58 para os observadores 1 e 2, respectivamente.
Conclusão Tanto a RM quanto as radiografias tiveram alta concordância intra e interobservador para medida de IA e ACO. Os valores absolutos de IA e ACO foram altamente correlacionados em ambas as modalidades de imagem. Esses achados sugerem que a RM é um método adequado para determinação de IA e ACO.
Nível de Evidência II, Estudo Diagnóstico.

Palavras-chave
- acrômio
- imagem por ressonância magnética
- ruptura do manguito rotador
- síndrome de colisão do ombro
- radiografia

Introduction

The etiology of rotator cuff tears (RCT) is still uncertain and it's now believed that it is multifactorial.[1] Factors that may contribute to the occurrence of those tears can be divided into intrinsic or extrinsic. Intrinsic factors include age,[2] tendinous degeneration,[3] genetic aspects,[4–6] smoking,[7,8] diabetes,[9] alcohol abuse.[10] Historically, extrinsic factors are those related to the impingement between acromion process and the rotator cuff, specifically supraspinatus tendon.[1] Since Neer postulated that 95% of RCT were caused by acromial impingement, the influence of scapular morphology in the etiology of those tears has been exhaustively investigated.[11] Following the same reasoning, Bigliani observed that an anterior and inferior acromial inclination could lead to supraspinatus tears.[12] However, subsequent studies contested this finding and suggested that tendon degeneration precedes acromial spur formation, leading to dynamic humeral head superior migration and therefore to secondary acromial impingement.[1]

In 2006, Nyffeler et al.[13] suggested that a large lateral (not anteroinferior) extension of the acromion related to a higher incidence of RCT. Authors postulated that a larger lateral extension of the acromion predisposes to supraspinatus degeneration by means of increasing deltoid shear forces and leading to superior migration of humeral head, consequently causing supraspinatus impingement against the acromion.[13] Authors recommended then that the lateral extension of the acromion should be measured through the acromial index (AI), which is the relation between two distances: from glenoid surface to the lateral acromion extremity and from glenoid surface to the lateral humeral cortex.[13] However, AI may be influenced by humeral anatomy, such as in deformity and malunion cases. To solve this shortcoming, Moor et al.[14] developed the critical shoulder angle (CSA), which depends only on scapular anatomy. This angle is formed between a line running from the superior to the inferior pole of the glenoid and another one running from the latter to the lateral acromial extremity. Authors found

 © 2023. Sociedade Brasileira de Ortopedia e Traumatologia. All rights reserved.

that 84% of their patients with rotator cuff tears had a CSA higher than 35°. Afterwards, the relationship between a high CSA and RCT has been suggested by several authors,[15–25] as well as the higher retear risk after surgical treatment of those tears.[26–30]

Both AI and CSA are measured in true AP view of the shoulder joint and the scapular positioning is critical to the reproducibility of radiographic parameters.[13,14] Positioning errors may lead to inconsistence and heterogeneity of AI and CSA measurements.[24,31–33] Currently, the gold standard imaging modality in the painful shoulder is magnetic resonance image (MRI), due to its high sensibility, specificity and accuracy in diagnosing RCT.[34] Once standardizing images acquisition is easier and more reliable in MRI than in radiographs,[34] one may infer that measurements of AI and CSA in MRI are more accurate than in radiographs. However, results of papers on this subject are conflicting.[35,36]

Therefore, the primary objective of this study is to compare the interobserver and intra-observer agreement for AI and CSA values measured in both radiographs and MRI of the shoulder. Also, we aim to compare absolute values of AI and CSA obtained in these image modalities, assessing whether MRI is a reliable method in determining both anatomical parameters.

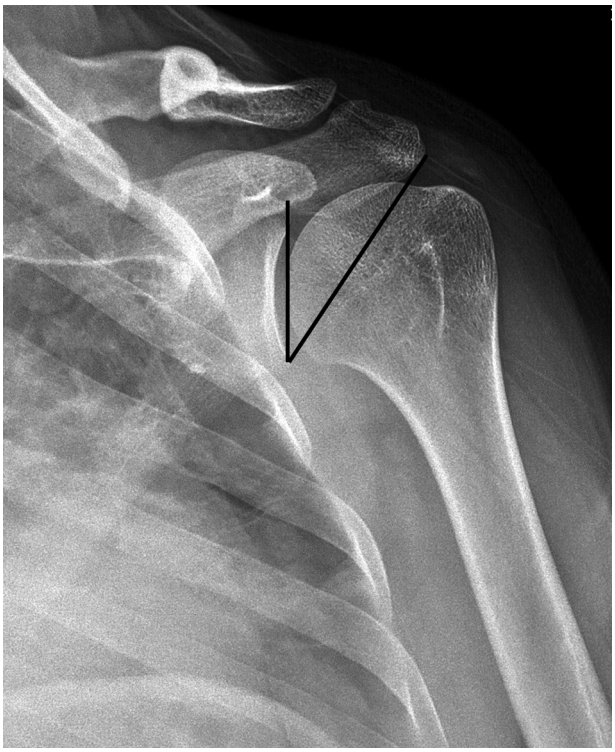

Fig. 1 True AP view radiograph of the shoulder, showing CSA measurement. The angle is formed between two lines: one from the superior to the inferior pole of the glenoid, and other from the latter to the lateral edge of the acromion.

Materials and Methods

Work approved by the ethics committee of our institution (document number: 32689114.7.0000.5257).

Study Design and Subjects Selection

This is a blind prospective longitudinal observational study. Skeletally mature patients who had medical indication of investigating shoulders conditions through radiographs and MRI were included. The exclusion criteria were previous history of shoulder fracture or surgery and those whose image exams revealed humeral or scapular bony deformity.

Imaging

After giving their written consent, patients were referred to radiology department to take both radiographs and MRI in the same day. Radiographs were taken in standing position with the shoulder in neutral rotation. The proper positioning of the patient to obtain a true AP view was made under fluoroscopic control (Axiom Iconos MD; Siemens, Erlangen, Germany). Only A1 images in the Suter-Henninger system[31] were accepted and every radiograph out of this standard was repeated. MRI exams were performed in high filed, closed machines, with a 1,5 T magnet (Magnetom Avanto; Siemens, Erlangen, Germany). The researchers studied T2-wheighted images with fat suppression in the axial, coronal and sagittal planes; T1 and T2-wheighted images without fat suppression in the axial, coronal and sagittal planes.

Images Analysis

Images of both radiographs and MRI exams were recorded in portable media and taken to two examiners, both fellowship trained shoulder surgeons, with different levels of experience (one and 15 years). Images were imported to a DICOM viewer (Radiant DICOM Viewer, Medixant, Poznan, Poland) and analysis of the radiographs were made according to Moor et al.[14] and Nyffeler et al.[13] (►**Figs. 1** and **2**); measurements in MRI were made according to Spiegl et al.[35] description (►**Fig. 3**). The evaluators had access to the complete examination, with the full sets of images.

None of the examiners had access to the names of the patients and only the main searcher knew the identity of subjects. Both evaluators and patients received coded numbers to identify them. Radiographs and MRI were given separate numbers so that evaluators could not relate the exams of a same patient. Twelve weeks after the first evaluation, exams were once more presented to examiners and a second evaluation was conducted.

Statistical Analysis

Statistical analysis was performed using GraphPad Prism version 9.0.0 (121) for Windows 64-bit (GraphPad Software, LLC), Stata/MP 16.1 for Windows (64-bit x86–64–StataCorp, LLC), and StatMate 2 for Windows (GraphPad Software, LLC). Continuous variables were given as a mean ± standard deviation. The normality distribution of the continuous variables was tested by the Kolmogorov-Smirnov test. Inter- and intra-observer reliability was presented as an Intraclass Correlation Coefficient (ICC) and agreement was classified according to Landis and Koch[37] criteria: a value inferior to 0.01 describes a poor agreement; a value between 0.01 and 0.20 describes a slight agreement; 0.21 to 0.40, a fair; 0.41

 © 2023. Sociedade Brasileira de Ortopedia e Traumatologia. All rights reserved.

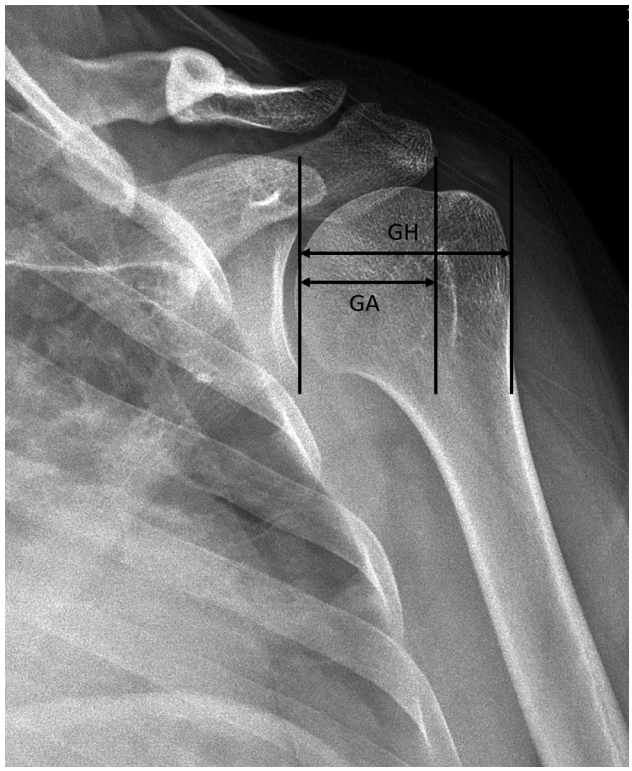

Fig. 2 True AP view radiograph of the shoulder, showing anatomical parameters required to measurement of the AI. This index is obtained dividing the distance from the glenoid surface to the most lateral edge of the acromion (GA) by the distance from the glenoid surface to the lateral cortex of the proximal humerus (GH). AI = GA/GH.

to 0.60, a moderate; 0.61 to 0.80, a substantial; and 0.81 to 1.00, an almost perfect agreement. The differences between two measurements were evaluated using Bland-Altman plots. The study had a 90% power to detect a smallest average difference between pairs of 0.09 in the CSA and 0.002 in the IA results with a significance level (α) of 0.05 (two-tailed). The significance level for all tests was set at $p < 0.05$.

Table 1 General data

124 subjects - 134 shoulders	
Mean age (years)	52 (18–85)
Gender (n)	
Female	68
Male	56
Affected side (n)	
Dominant	89
Bilateral	10
Main complaint	
Pain	116
Instability	9
Stiffness	8
Weakness	1
Duration of symptoms (months)	23,4 (0,1–400)

Results

Demographics and general characteristics of the sample are depicted in ►**Table 1**. We evaluated 134 shoulders in 124 subjects, with a mean age of 52 years old (ranging 18 to 85); there were 68 females and 56 males. Dominant side was affected in 89 subjects and 10 patients had bilateral complaints. Isolated pain was the main complain in 116 shoulders and pain associated to stiffness were reported in 8 shoulders. Isolated weakness was seen in one shoulder and

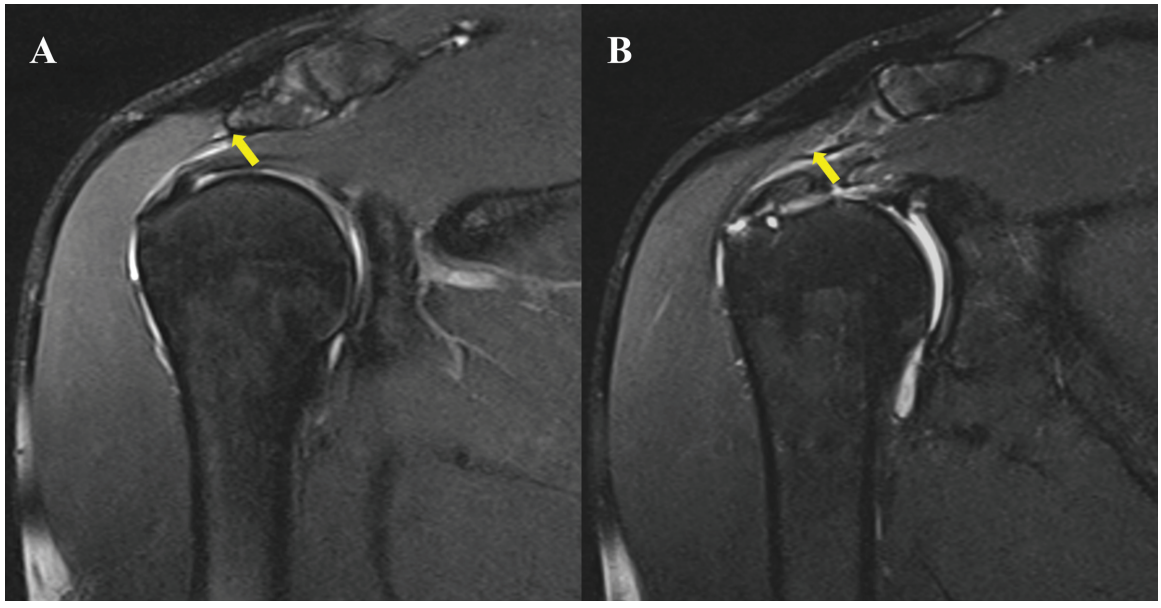

Fig. 3 Frequently, in MRI the most lateral edge of the acromion is not in the same plane of the glenoid midline. Thus, we used the cursor to mark the lateral acromion (3A) and then scroll the images until the glenoid midline (3B), where the measurements are made.

 © 2023. Sociedade Brasileira de Ortopedia e Traumatologia. All rights reserved.

Table 2 Condition of rotator cuff tendons among patients

	Normal	Tendinosis	Partial tear	Full thickness tear
Supraspinatus (n)	34	33	31	36
Infraspinatus (n)	79	39	4	12
Subscapularis (n)	107	19	5	3

Table 3 Intraobserver reliability

	Interclass correlation coefficient		
	Observer 1	Observer 2	Mean
CSA			
X-ray	0.979*	0.893*	0.936
MRI	0.975*	0.905*	0.940
AI			
X-ray	0.916*	0.900*	0.908
MRI	0.929*	0.915*	0.922

Abbreviations: AI, acromial index; CSA, critical shoulder angle; MRI, magnetic resonance image.
*$p < 0.001$

instability was the main complaint in nine shoulders. The mean length of symptoms was 23 months (ranging 0,1 to 400). Full thickness and partial thickness RCT were found in 36 and 33 patients, respectively. Supraspinatus tendon was the most committed one, followed by infraspinatus and subscapularis; there was no teres minor tendon tear in this sample (►**Table 2**).

High ICC values were observed for intra-observer reliability, regarding both CSA and IA measured either in MRI or radiographs (►**Table 3**). Therefore, there was an excellent, almost perfect intra-observer agreement for both CSA and AI measurements made in MRI and radiographs. There was an almost perfect interobserver agreement for both CSA and AI measured in radiographs and a substantial interobserver agreement for measurements made in MRI (►**Table 4**). Absolute values found for AI and CSA were also correlated in both image modalities used in this study. ICC values for AI and CSA found in radiographs and MRI for both observers were 0.86 and 0.87, respectively. Bland-Altman plots show high inter-method correlation for both observers regarding either radiographs and MRI (►**Fig. 4**). Mean difference for AI values measured in X-rays and in MRI was 0.01 and 0.03 for observers 1 and 2, respectively. Mean difference for CSA values obtained in X-rays and MRI was 0.16 and 0.58 for observers 1 and 2, respectively.

Table 4 Interobserver reliability

	Interclass correlation coefficient		
	T1	T2	Mean
CSA			
X-ray	0.910*	0.875*	0.892
MRI	0.737*	0.768*	0.752
AI			
X-ray	0.836*	0.863*	0.849
MRI	0.737*	0.634*	0.685

Abbreviations: AI, acromial index; CSA, critical shoulder angle; MRI, magnetic resonance image; T1, first evaluation; T2, second evaluation.
*$p < 0.001$.

Discussion

This study found high inter and intra-observer agreement for AI and CSA measured in both radiographs and MRI exams. ICC values for intra-observer agreement were even higher than those for inter-observer agreement, reflecting that observers tend to agree more with themselves than with each other. Although quite similar, intra-observer agreement was slightly higher in MRI than in radiographs, for both AI and CSA. However, inter-observer agreement was higher in radiographs than in MRI exams; even so, ICC values for inter-observer agreement in MRI were still considered high and a substantial agreement was found. Not only observers agreed with themselves and with each other, we also had a high inter-method correlation – absolute AI and CSA values observed in radiographs and in MRI were very similar and high ICC values were observed on this analysis. These findings may suggest that either MRI and radiographs are equally suitable for measurements of both AI and CSA.

In fact, MRI has long become the main diagnostic tool in investigating shoulder pain,[34] due to its high accuracy in detecting ligamentous, tendinous and bony injuries. Besides that, the acquisition of the proper scapular plane is easier in MRI than in routine radiographs, since it's done by the radiology technician immediately before the exam begins. Fortunately, the radiography system we used in this study allowed for adequate patient positioning under fluoroscopic control, assuring a true AP view of the shoulder. Nonetheless, this may not be available for routine use in most of the orthopedics services around the world. Also, one must note that even when using standard protocols and fluoroscopic control, obtaining a true AP view can be complicated by many individual factors, such as medical comorbidities, variations in scapular version and shape, age, body habitus, etc. True AP views might be identified by ruling out exams showing double contoured glenoids and also those exams showing flexion or extension malpositioning of the scapula, which is assessed by coracoid position regarding its overlap with

 © 2023. Sociedade Brasileira de Ortopedia e Traumatologia. All rights reserved.

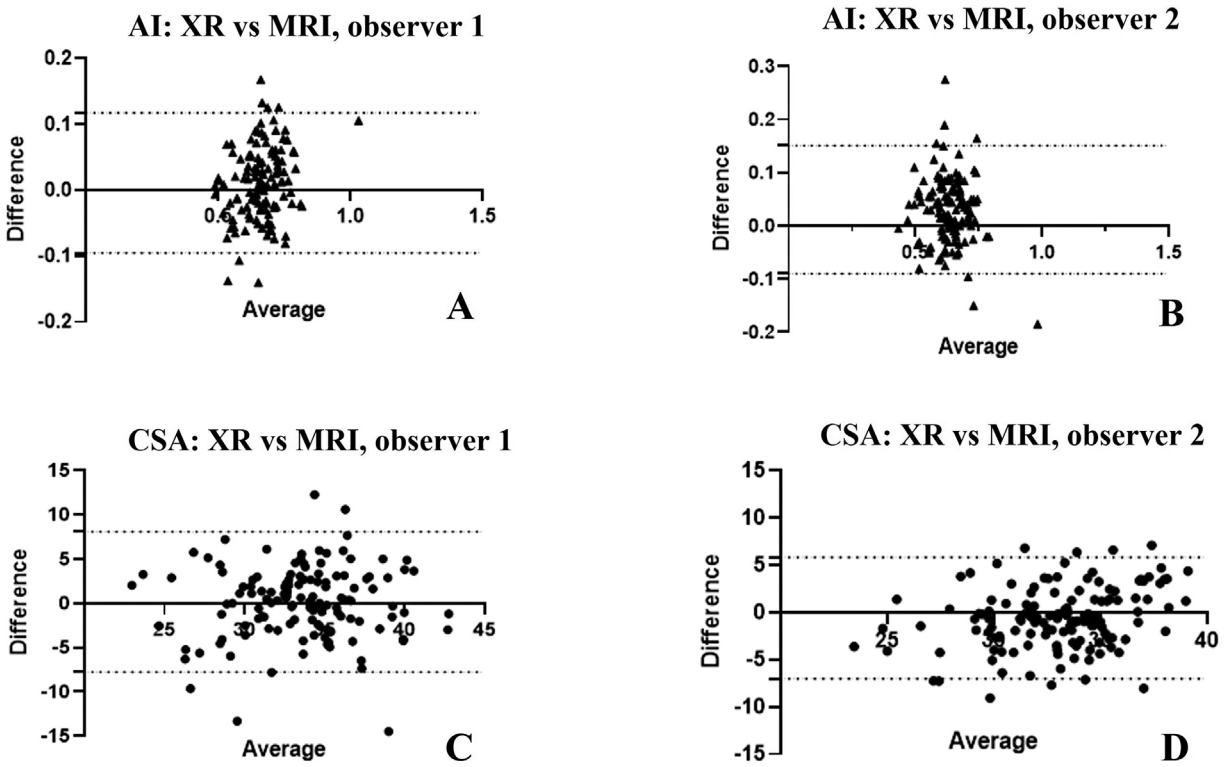

Fig. 4 Bland-Altman plots showing difference *vs*. average distribution of AI (**A, B**) and CSA (**C, D**) indexes measured in X-rays and in MRI for observers 1 and 2, respectively.

glenoid. In this way, we found Sutter-Henninger classification[31] useful to exclude radiographs made with malpositioned scapula. Authors noted that when doing so, 89% of CSA measurements were within less than 2° of accuracy. Even respecting a standard radiography protocol, Chalmers et al.[38] retrospectively observed that only 19% of radiographs in their study were suitable to measure CSA, according to Sutter-Henninger classification. However, authors did not used fluoroscopic positioning of the patient. As our study had a prospective design, we could guarantee that only X-rays defined as A1 in Sutter-Henninger classification were included.

When measuring both CSA and AI in MRI, one must consider that acromial most lateral edge is not at the same plane of glenoid surface and it's generally slightly posterior to it.[39] This is even more concerning for AI, which relies also on the localization of lateral humeral cortex besides the glenoid surface and lateral acromial edge, i.e., there are three anatomic variables instead of two. To overcome this, we used a simple, previously described technique[35,36]: first, the most lateral part of the acromion was identified and marked with a cursor; then the MRI slice which passes through the glenoid midline was selected and the measurements were made. Although CSA and AI depend on the same anatomic references regardless the diagnostic method used, one could expect disparate values measured in X-rays and in MRI due to inherent differences between each of these imaging modalities. And even we have observed high agreement values for both imaging modalities separated, this could not necessarily mean that values found in radiographs were similar to those found in MRI. For this reason, we used Bland-Altman plots to compare those values and found that mean values for both AI and CSA obtained either in MRI or in radiographs were almost identical. This finding may support the clinical use of MRI in measuring AI and CSA as well it's use in future studies.

Our findings are in contrast with those reported by Spiegl et al.[35] They found high interobserver and intra-observer agreement for CSA measurements made in X-rays, but lower agreement (moderate for interobserver and poor for intra-observer) for measurements made in MRI. Curiously, authors also found a significant difference in mean CSA values measured in radiographs versus MRI, only in osteoarthritis patients, but not in those with RCT. They speculate that this discrepancy may be due to the difficulty of defining glenoid borders in osteoarthritis patients. Although our sample is much bigger, we had fewer patients with osteoarthritis in this series (seven versus ten in Spiegl et al. study) and didn't notice this difference. Besides having a smaller sample, they didn't give details on radiographic technique used in their study, which may be a potential reason for the dissimilarity between our results and theirs.

Conversely, Incesoy et al.[36] measured CSA and AI in 870 subjects and found high inter- and intra-observer agreement. They also reported that both AI and CSA were significantly related to full-thickness RCT. Although authors stated that patients had also radiographs, only MRI data were included in their paper; thus, a comparison between absolute AI and CSA values in X-rays and in MRI was not made. Recently, Garcia et al.,[27] in a rather small series, found similar values in CSA measured both in radiographs and in MRI. In their prospective, randomized, blind study, they also observed

 © 2023. Sociedade Brasileira de Ortopedia e Traumatologia. All rights reserved.

more experienced evaluators to achieve higher agreement between those imaging modalities.

Our study has some strengths. First, we could use a solid standardized method for radiographic exams, in which patients were positioned under fluoroscopic control. As a prospective study, we could repeat every radiograph that didn't meet the criteria for a true AP view of the shoulder. Also, both evaluators were fellowship-trained shoulder surgeons, which may have contributed to the high agreement values obtained. Besides, we had a high number of exams, which allowed for powerful statistical analysis. By the other hand, this study also had some weaknesses. Although it's advisable that strict true AP views of the shoulder should be used when investigating shoulder pain, we acknowledge that this might be difficult in some patients and under certain conditions. Therefore, the findings of our study may not be applicable to less than perfect true AP radiographs. Also, the main indication for MRI in our series was to investigate shoulder pain, mostly caused by rotator cuff tears. Roughly, two-thirds of our patients had partial and full-thickness rotator cuff tears and we had few patients with other diagnosis, such as instability, frozen shoulder, and osteoarthritis. So, our results may not be reproductible in cases other than rotator cuff tendinopathy.

Conclusion

Both MRI and X-rays provided high intra- and interobserver agreement for measurement of AI and CSA. Absolute values found for AI and CSA were highly correlated in both image modalities. These findings suggest that MRI is a suitable method to measure AI and CSA.

Financial Support
The present survey has not received any specific funding from public, commercial, or not-for-profit funding agencies.

Conflict of Interests
The authors have no conflict of interests to declare.

References

1 Maffulli N, Longo UG, Berton A, Loppini M, Denaro V. Biological factors in the pathogenesis of rotator cuff tears. Sports Med Arthrosc Rev 2011;19(03):194–201
2 Sayampanathan AA, Andrew THC. Systematic review on risk factors of rotator cuff tears. J Orthop Surg (Hong Kong) 2017;25 (01):2309499016684318
3 Morikawa D, Itoigawa Y, Nojiri H, et al. Contribution of oxidative stress to the degeneration of rotator cuff entheses. J Shoulder Elbow Surg 2014;23(05):628–635
4 Figueiredo EA, Loyola LC, Belangero PS, et al. Rotator cuff tear susceptibility is associated with variants in genes involved in tendon extracellular matrix homeostasis. J Orthop Res 2020;38 (01):192–201
5 Assunção JH, Godoy-Santos AL, Dos Santos MCLG, Malavolta EA, Gracitelli MEC, Ferreira Neto AA. Matrix metalloproteases 1 and 3 promoter gene polymorphism is associated with rotator cuff tear. Clin Orthop Relat Res 2017;475(07):1904–1910
6 Tashjian RZ, Kim SK, Roche MD, Jones KB, Teerlink CC. Genetic variants associated with rotator cuff tearing utilizing multiple population-based genetic resources. J Shoulder Elbow Surg 2021; 30(03):520–531
7 Bishop JY, Santiago-Torres JE, Rimmke N, Flanigan DC. Smoking Predisposes to rotator cuff pathology and shoulder dysfunction: A systematic review. Arthroscopy 2015;31(08):1598–1605
8 Lundgreen K, Lian OB, Scott A, Nassab P, Fearon A, Engebretsen L. Rotator cuff tear degeneration and cell apoptosis in smokers versus nonsmokers. Arthroscopy 2014;30(08):936–941
9 Huang SW, Wang WT, Chou LC, Liou TH, Chen YW, Lin HW. Diabetes mellitus increases the risk of rotator cuff tear repair surgery: A population-based cohort study. J Diabetes Complications 2016;30(08):1473–1477
10 Passaretti D, Candela V, Venditto T, Giannicola G, Gumina S. Association between alcohol consumption and rotator cuff tear. Acta Orthop 2016;87(02):165–168
11 Neer CS II. Anterior acromioplasty for the chronic impingement syndrome in the shoulder: a preliminary report. J Bone Joint Surg Am 1972;54(01):41–50
12 Bigliani LU, Morrison DSAE. The morphology of the acromion and its relationship to rotator cuff tears. Orthop Trans 1986;10:216
13 Nyffeler RW, Werner CM, Sukthankar A, Schmid MR, Gerber C. Association of a large lateral extension of the acromion with rotator cuff tears. J Bone Joint Surg Am 2006;88(04):800–805
14 Moor BK, Bouaicha S, Rothenfluh DA, Sukthankar A, Gerber C. Is there an association between the individual anatomy of the scapula and the development of rotator cuff tears or osteoarthritis of the glenohumeral joint?: A radiological study of the critical shoulder angle Bone Joint J 2013;95-B(07):935–941
15 Li X, Olszewski N, Abdul-Rassoul H, Curry EJ, Galvin JW, Eichinger JK. Relationship Between the Critical Shoulder Angle and Shoulder Disease. JBJS Rev 2018;6(08):e1
16 Balke M, Schmidt C, Dedy N, Banerjee M, Bouillon B, Liem D. Correlation of acromial morphology with impingement syndrome and rotator cuff tears. Acta Orthop 2013;84(02):178–183
17 Blonna D, Giani A, Bellato E, et al. Predominance of the critical shoulder angle in the pathogenesis of degenerative diseases of the shoulder. J Shoulder Elbow Surg 2016;25(08):1328–1336
18 Gomide LC, Carmo TCD, Bergo GHM, Oliveira GA, Macedo IS. Relationship between the critical shoulder angle and the development of rotator cuff lesions: a retrospective epidemiological study. Rev Bras Ortop 2017;52(04):423–427
19 Heuberer PR, Plachel F, Willinger L, et al. Critical shoulder angle combined with age predict five shoulder pathologies: a retrospective analysis of 1000 cases. BMC Musculoskelet Disord 2017; 18(01):259
20 Kaur R, Dahuja A, Garg S, Bansal K, Garg RS, Singh P. Correlation of acromial morphology in association with rotator cuff tear: a retrospective study. Pol J Radiol 2019;84:e459–e463
21 Moor BK, Röthlisberger M, Müller DA, et al. Age, trauma and the critical shoulder angle accurately predict supraspinatus tendon tears. Orthop Traumatol Surg Res 2014;100(05):489–494
22 Park HB, Gwark JY, Kwack BH, Na JB. Are any radiologic parameters independently associated with degenerative postero-superior rotator cuff tears? J Shoulder Elbow Surg 2021;30(08): 1856–1865
23 Seo J, Heo K, Kwon S, Yoo J. Critical shoulder angle and greater tuberosity angle according to the partial thickness rotator cuff tear patterns. Orthop Traumatol Surg Res 2019;105(08): 1543–1548
24 Smith GCS, Liu V, Lam PH. The critical shoulder angle shows a reciprocal change in magnitude when evaluating symptomatic full-thickness rotator cuff tears versus primary glenohumeral osteoarthritis as compared with control subjects: A systematic review and meta-analysis. Arthroscopy 2020;36(02):566–575
25 Stamiris D, Stamiris S, Papavasiliou K, Potoupnis M, Tsiridis E, Sarris I. Critical shoulder angle is intrinsically associated with the development of degenerative shoulder diseases: A systematic review. Orthop Rev (Pavia) 2020;12(01):8457

 © 2023. Sociedade Brasileira de Ortopedia e Traumatologia. All rights reserved.

26 Docter S, Khan M, Ekhtiari S, et al. The relationship between the critical shoulder angle and the incidence of chronic, full-thickness rotator cuff tears and outcomes after rotator cuff repair: A systematic review. Arthroscopy 2019;35(11):3135–3143.e4
27 Garcia GH, Liu JN, Degen RM, et al. Higher critical shoulder angle increases the risk of retear after rotator cuff repair. [published correction appears in J Shoulder Elbow Surg. 2017;26(4):732]J Shoulder Elbow Surg 2017;26(02):241–245
28 Li H, Chen Y, Chen J, Hua Y, Chen S. Large critical shoulder angle has higher risk of tendon retear after arthroscopic rotator cuff repair. Am J Sports Med 2018;46(08):1892–1900
29 Scheiderer B, Imhoff FB, Johnson JD, et al. Higher critical shoulder angle and acromion index are associated with increased retear risk after isolated supraspinatus tendon repair at short-term follow up. Arthroscopy 2018;34(10):2748–2754
30 Sheean AJ, Sa D, Woolnough T, Cognetti DJ, Kay J, Burkhart SS. Does an increased critical shoulder angle affect re-tear rates and clinical outcomes following primary rotator cuff repair? A systematic review. Arthroscopy 2019;35(10):2938–2947.e1
31 Suter T, Gerber Popp A, Zhang Y, Zhang C, Tashjian RZ, Henninger HB. The influence of radiographic viewing perspective and demographics on the critical shoulder angle. J Shoulder Elbow Surg 2015;24(06):e149–e158
32 Tang Y, Hou J, Li Q, et al. The effectiveness of using the critical shoulder angle and acromion index for predicting rotator cuff tears: accurate diagnosis based on standard and nonstandard anteroposterior radiographs. Arthroscopy 2019;35(09):2553–2561
33 Kim JH, Gwak HC, Kim CW, Lee CR, Kwon YU, Seo HW. Difference of Critical Shoulder Angle (CSA) according to minimal rotation: Can minimal rotation of the scapula be allowed in the evaluation of CSA? Clin Orthop Surg 2019;11(03):309–315
34 Iannotti JP, Zlatkin MB, Esterhai JL, Kressel HY, Dalinka MK, Spindler KP. Magnetic resonance imaging of the shoulder. Sensitivity, specificity, and predictive value. J Bone Joint Surg Am 1991; 73(01):17–29
35 Spiegl UJ, Horan MP, Smith SW, Ho CP, Millett PJ. The critical shoulder angle is associated with rotator cuff tears and shoulder osteoarthritis and is better assessed with radiographs over MRI. Knee Surg Sports Traumatol Arthrosc 2016;24(07):2244–2251
36 İncesoy MA, Yıldız KI, Türk ÖI, et al. The critical shoulder angle, the acromial index, the glenoid version angle and the acromial angulation are associated with rotator cuff tears. Knee Surg Sports Traumatol Arthrosc 2021;29(07):2257–2263
37 Landis JR, Koch GG. An application of hierarchical kappa-type statistics in the assessment of majority agreement among multiple observers. Biometrics 1977;33(02):363–374
38 Chalmers PN, Salazar D, Steger-May K, Chamberlain AM, Yamaguchi K, Keener JD. Does the critical shoulder angle correlate with rotator cuff tear progression? Clin Orthop Relat Res 2017;475 (06):1608–1617
39 Karns MR, Jacxsens M, Uffmann WJ, Todd DC, Henninger HB, Burks RT. The critical acromial point: the anatomic location of the lateral acromion in the critical shoulder angle. J Shoulder Elbow Surg 2018;27(01):151–159

 © 2023. Sociedade Brasileira de Ortopedia e Traumatologia. All rights reserved.