Published online: 2020-09-25

Bone Defects in Revision Total Knee Arthroplasty

Falhas ósseas nas revisões de artroplastia total do joelho

Alan de Paula Mozella[1,2] Hugo Alexandre de Araújo Barros Cobra[1]

[1] Knee Surgery Center, National Institute of Traumatology and Orthopedics (INTO), Rio de Janeiro, RJ, Brazil
[2] Faculty of Medical Sciences, Universidade do Estado do Rio de Janeiro (UERJ), Rio de Janeiro, RJ, Brazil

Address for correspondence Alan de Paula Mozella, M.D., M.Sc., Centro de Cirurgia do Joelho, Instituto Nacional de Traumatologia e Ortopedia (INTO), Av. Brasil, 500, Caju, Rio de Janeiro, RJ, 20940-070, Brazil (e-mail: apmozella@terra.com.br).

Rev Bras Ortop 2021;56(2):138–146.

Abstract

The increase in the number of revision total knee arthroplasty surgeries has been observed in recent years, worldwide, for several causes. In the United States, a 601% increase in the number of total knee arthroplasties, between 2005 and 2030, is estimated. Among the enormous challenges of this complex surgery, the adequate treatment of bone defects is essential to obtain satisfactory and lasting results. The adequate treatment of bone defects aims to build a stable and lasting support platform for the implantation of the definitive prosthetic components and, if possible, with the reconstruction of bone stock. Concomitantly, it allows the correct alignment of the prosthetic and limb components, as well as restoring the height of the joint interline and, thus, restoring the tension of soft parts and load distribution to the host bone, generating a joint reconstruction with good function, stable, and painless. There are several options for the management of these bone defects, among them: bone cement with or without reinforcement with screws, modular metallic augmentations, impacted bone graft, structural homologous graft and, more recently, metal metaphyseal cones, and metaphyseal sleeves. The objective of the present article was to gather classic information and innovations about the main aspects related to the treatment of bone defects during revision surgeries for total knee arthroplasty.

Keywords
- arthroplasty, replacement, knee
- bone defects
- homologous grafts
- review

Resumo

O aumento do número de cirurgias de revisão de artroplastia total do joelho tem sido observado nos últimos anos, em todo o mundo, por diversas causas. Nos Estados Unidos, é estimado um aumento de 601% no número de artroplastias totais do joelho entre 2005 e 2030. Dentre os enormes desafios dessa cirurgia complexa, o adequado tratamento dos defeitos ósseos é essencial para a obtenção de resultados satisfatórios e duradouros. O adequado tratamento dos defeitos ósseos objetiva construir uma plataforma de suporte estável e duradoura para a implantação dos componentes protéticos definitivos e, se possível, com recomposição do estoque ósseo. Concomitantemente, possibilita o correto alinhamento dos componentes protéticos e do membro, assim como permite restabelecer a altura da interlinha articular e, dessa

received
January 5, 2020
accepted
April 15, 2020
published online
March 29, 2021

DOI https://doi.org/10.1055/s-0040-1713392.
ISSN 0102-3616.

© 2021. Sociedade Brasileira de Ortopedia e Traumatologia. All rights reserved.
This is an open access article published by Thieme under the terms of the Creative Commons Attribution-NonDerivative-NonCommercial-License, permitting copying and reproduction so long as the original work is given appropriate credit. Contents may not be used for commercial purposes, or adapted, remixed, transformed or built upon. (https://creativecommons.org/licenses/by-nc-nd/4.0/)
Thieme Revinter Publicações Ltda., Rua do Matoso 170, Rio de Janeiro, RJ, CEP 20270-135, Brazil

Palavras-chave
- artroplastia do joelho
- defeitos ósseos
- enxertos homólogos
- revisão

forma, restaurar a tensão de partes moles e distribuição de carga ao osso hospedeiro, gerando uma reconstrução articular com boa função, estável e indolor. Diversas são as opções para manejo dessas falhas ósseas, entre elas: cimento ósseo com ou sem reforço com parafusos, aumentos metálicos modulares, enxerto ósseo impactado, enxerto estrutural homólogo e, mais recentemente, cones metafisários de metal trabecular e *sleeve* metafisário. O objetivo do presente artigo foi reunir informações clássicas e inovações dos principais aspectos relativos ao tratamento das falhas ósseas durante as cirurgias de revisão de artroplastia total do joelho.

Introduction

The increase in the number of revision total knee arthroplasty (rTKA) surgeries can be related not only to the increase in the absolute number of primary surgeries performed, but also to several other factors such as the expansion of primary implant indications, including younger and more active patients, as well as factors related to surgical technique and implant durability.[1–5] In the United States, a 601% increase in the number of rTKAs is estimated between 2005 and 2030.[1] In Brazil, there is a lack of reliable data on the increase in the number of rTKAs.

Among the enormous challenges of this complex surgery, the adequate treatment of bone defects is essential to obtain satisfactory and lasting results.[6–8] The cause of bone deficiency is usually multifactorial; however, aspects such as previous pathology, the design of primary implants, the occurrence of osteolysis, possible technical errors in the realization of the primary prosthesis or during the removal of fixed implants and, also, the failure mechanism are frequently identified.[9–12]

Assessment of Bone Defects

Anteroposterior (AP) and lateral radiographs of the knee make it possible to assess the design and size of prosthetic components, to analyze the type and quality of implant-host fixation, to infer possible causes of failure, and to estimate the extent of bone loss. Axial radiography of the patella allows the assessment of patellar alignment, as well as the presence or absence of patellar component and/or bone defect.[13] Oblique radiographs can be useful in showing osteolysis, especially in implants with a posterior-stabilized box. Panoramic views allow to analyze the limb alignment, the presence of extra articular bone deformities, and the presence of possible synthesis materials as well as the condition of the other joints.[12–14]

However, standard radiographs of the knee often underestimate, especially in the femur,[9,13] the extent of the bone defect identified intraoperatively after removal of implants and debridement of fibrosis and necrotic tissues.[11,15] Computed tomography (CT) images show greater sensitivity and specificity in diagnosing bone defects and osteolytic lesions that are difficult to observe on radiographs due to the overlap of images of metallic components; however, due to the increased cost and exposure to ionizing radiation, the routine use of CT is not recommended.[11–13,16]

The adequate treatment of bone defects aims to build a stable and lasting support platform for implantation of the definitive prosthetic components and, if possible, the restoration of bone stock. Concomitantly, it allows the correct alignment of the prosthetic and limb components, as well as reestablishing the height of the joint interline, thus restoring the tension of soft parts and load distribution to the host bone and generating a joint reconstruction with good and stable function, and painless too.[6,7,9,11]

Classification and Management Options for Bone Defects

Several distinct bone defect classification systems have been proposed to assist in decision making. However, subjectivity and, therefore, low interobserver agreement and limited accuracy in correctly estimating the size of bone defect are the main criticisms of most classifications.[11,12,17]

The most widely used classification is that of the Anderson Orthopedic Research Institute (AORI),[18] which describes the defects according to size, location, and impairment of soft-tissue structures after the removal of components and debridement of devitalized tissues. Defects in the femur and tibia are analyzed separately in three categories:

Type 1: it includes contained defects limited to the cancellous bone, without compromise or cortical bone failure. It presents intact metaphyseal bone and, therefore, does not compromise the stability of the revision components. In selected cases, revisions can be effectively performed with primary implants,[19] although standard revision implants associated with the use of intramedullary nails are the recommendation of most authors. Thus, this type of defect can be effectively treated by filling with bone cement, sometimes associated with reinforcement with screws. Bone grafting may represent a management option in this type of bone failure. Metallic augmentations can also be an option to restore the joint interline.[6,10–12,15,19]

Type 2: it is characterized by considerable loss of metaphyseal bone, which will need to be filled in during revision surgery. Defects can occur in only one femoral condyle or tibial plateau and are referred to as type 2A. These defects are most often managed with bone cement reinforced with a screw or non-porous metallic augmentations (wedge or

 © 2021. Sociedade Brasileira de Ortopedia e Traumatologia. All rights reserved.

block) or, still, bone grafting and standard revision components with intramedullary nails.[20] However, bone defects that affect both condyles or plateaus are classified as type 2B. In these more severe defects, more complex treatment and fixation options are recommended. Thus, options with metaphyseal fixation, such as highly porous metal cones (tantalum cones), or metaphyseal sleeves, or even homologous structural bone grafting, are the most recommended options.[6–8,10–12,19–22]

Type 3: it has completely deficient metaphyseal bone, characterized by severe bone loss that compromises the largest portion of the femoral condyle or tibial plateau. These defects are often associated with detachments of the epicondyles and, consequently, collateral ligaments, or even the patellar ligament. Normally, for appropriate treatment, these defects require prosthetic implants with long intramedullary nail with diaphyseal fixation, and options for defect management with metaphyseal fixation, such as trabecular metal cones, or metaphyseal sleeve or, still, structural homologous graft. In cases with detachment of the epicondyle and ligament insufficiency, blocked implants are normally necessary. Customized implants, non-conventional or tumor prostheses can be indicated for the management of large defects in which reconstruction is not possible.[6–8,10–12,19,21–23]

Thus, for an adequate treatment of bone defects during the performance of rTKA, the accurate analysis of the quality of the host bone, the configuration (whether contained or not contained), the size and location of the bone defect must be carefully analyzed. However, currently, there is no option for managing bone failure that is ideal in all circumstances. Therefore, several other factors, such as functional demand, presence of comorbidities, life expectancy and experience of the surgeon must be evaluated in the decision-making process and in the individual choice of the option employed. However, restoration of bone stock is preferable in patients with the possibility of future revisions.[24]

Bone Cement with or without Reinforcement with Screws

Bone defects involving less than 50% of the cancellous bone surface (ideally, less than 10% of peripheral deficiency) and with a depth of less than 5 mm are traditionally managed with methyl methacrylate. In short, this technique is best suited for small bone defects, mainly, those contained.[17]

The use of bone cement is also advocated for the handling of defects with a depth between 5 and 10 mm; however, the use one or more screws from 4.5 to 6.5 mm is recommended to reinforce the construction, aiming to provide greater mechanical resistance to the cement column and improve the load distribution to the host bone. In this case, attention must be paid so that the screws do not remain in direct contact with the definitive implant. Therefore, this technique can be indicated in the management of AORI type-1 defects and, eventually, in selected cases AORI type 2A.[6,11,12,15,17]

Satisfactory results, in medium-term follow-up, in the treatment of bone defects in the tibia, using cement reinforced with screws, were demonstrated by Ritter et al.,[25] although with a high incidence of non-progressive radiolucent lines. Therefore, this technique was more often indicated for older patients with less functional demand, due to the questioning regarding the long-term conservation of the biomechanical properties.[6,11,24] Posteriorly, Berend et al.[26] demonstrated high implant survival in patients with 20 years of surgery who underwent primary arthroplasty with significant bone defects managed with methyl methacrylate reinforced with screws. Additionally, the same authors evaluated patients who underwent rTKA surgeries and demonstrated that the use of bone cement reinforced with screws as well as the use of revision implants had the ability to restore knee biomechanics and a 98.5% survival rate after 15 years. Thus, the authors guide the possibility of using this technique to reduce costs without compromising the survival of the prosthesis.[27]

Modular Metallic Augmentation (Blocks and Wedges)

Modular metallic augmentations is indicated in the management of uncontrolled bone defects, compromising more than 25% of the cortical contour and with a depth between 5 and 20 mm, or even when more than 40% of the implant surface is not supported by the host bone.[11,12,15,28] In summary, modular metallic augmentations are most often indicated in the management of AORI type 2 bone defects[11] and also employed in selected AORI type 3 cases in elderly patients with low physical demand.[15,17]

The various revision implant systems present metallic augmentations of varying thicknesses, sizes and shapes. They can be added to both the femoral and tibial components to fill the bone defect in one or both tibial condyles or plateaus.

The metallic augmentations for the management of tibial defects are presented in wedge or block form. In both options, it is usually necessary to prepare and remove additional host bone for correct adaptation of the metal augmentation. Although there is a lesser removal of additional bone with the use of metal wedges, the sheer force at the implant-bone interface is greater and, consequently, more susceptible to mechanical failure. When using block augmentation, bone removal is usually greater; however, it presents a better load distribution to the host bone.[11,24,29] The possible bone loss after the use of modular augmentations must be filled in with methyl methacrylate or by bone grafting.[15]

The use of symmetric metallic augmentation extensions in both the distal femur and the proximal tibia frequently contribute to the restoration of the height of the joint interline and, consequently, soft-tissue tensioning and equilibrium of the flexion-extension balance. Posterior femoral augments are particularly useful in restoring the anteroposterior dimension of the component and, consequently, in the stability of the flexion space; however, the use of asymmetric posterior femoral augments may be necessary to ensure proper external rotation of the component.[6,11]

The main advantages of using metallic extensions are the immediate load-bearing capacity, it helps the rotational

 © 2021. Sociedade Brasileira de Ortopedia e Traumatologia. All rights reserved.

stability of the component, the reduction of surgical time and presents less complications. The disadvantages, however, refer to the increased costs with the implant, sometimes the need for additional resection of the host bone and the fact of not restoring the bone stock. Other potential disadvantages refer to the possibility of corrosion and the formation of wear debris at the modular augmentation interface and prosthetic component, in addition to the possibility of the occurrence of the stress shielding phenomenon due to the difference between the elasticity modules of the metal and the host bone.[10,15,24,30,31]

Failures of metallic augmentations in performing adequate treatment of defects, most often, occur when the surgeon underestimates the severity of bone deficiency and does not identify the need to use defect treatment options with metaphyseal fixation.[11] Therefore, the tendency of modern modular augmentations is to use metals in highly porous configuration, between 70 and 80%, given the benefits of having an elasticity module closer to the host bone, greater friction and fixation capacity, in addition to enabling bone growth and biological fixation.

Good or excellent results with the use of metallic augmentations to treat bone deficiencies during the revision have been reported to vary from 84 to 98%,[15,31] although the effectiveness and durability of the technique is contested.

In a prospective medium to long follow-up of 79 patients with AORI defects, two treated with metallic augmentations, although Patel et al.[31] have observed incidence of non-progressive radiolucent lines in 14% of cases, they found durability of 92% after 11 years. Favorable results, with no complications or loosening in 3 years, were also reported by Werle et al.,[32] with the use of 30 mm femoral metallic augmentation to treat femoral defects AORI 3. Contrarily, Hockman et al.[33] identified that even using modular augmentations in 89% of rTKA cases, structural grafts were necessary in 48% of cases to effectively treat bone deficiency. They also observed a greater number of failures in patients treated only with metallic augmentations, resulting in a 79.4% durability in 8 years.

Impaction Bone Graft

The use of impaction bone graft is an effective option for the management and restoration of bone stock in defects of various sizes and shapes, especially for those contained, although good and durable results have also been demonstrated for not contained defects.[30,34,35] Autologous graft has osteoinduction, osteoconduction, and osteogenic capacity and can be used, above all, in small disabilities due to limited availability and risk of pain and complications at donor sites. Due to greater quantitative availability, the homologous graft is the most frequently used, although it presents a potential risk of disease transmission, fracture of the host bone during impaction and, also the possibility of graft absorption with loss of support capacity.[12,17,30,34,35] Increased risk for infection and concern about immunological reaction are also related to the homologous graft.[17]

The surgical technique requires careful debridement of the bone defect with the use of a burr drill to remove the sclerotic bone from the periphery of the defect, thus forming a viable bed for osteointegration. The initial stability of components with the use of impacted bone graft is worrisome and is also influenced by the integrity of the cortex, the size of the defect and the type of implanted intramedullary nail. Contained defects can be treated without major difficulties; however, for non-contained defects, a shaped plate or metal mesh should be used to avoid graft leakage and to increase the stability of the construction.[17,30,34] The intramedullary nail test must be properly positioned before the impaction of bone particles between 3 and 5 mm in size to provide greater initial stability.[17,30,34] The test implants are removed, and the final intramedullary nail must be inserted. The use of long press-fit nails can add initial stability to the system; however, it can over-protect the load transmission graft and, consequently, there is a concern to inhibit early incorporation. Therefore, many authors recommend the preferential use of a cemented nail.[30,34]

In a study of 42 rTKAs, with an average follow-up of 3.8 years, treated with impacted homologous graft, Lotke et al.[34] identified graft incorporation in all cases without failure of the implants. Similar results were found by Naim et al.[36] by treating large tibial bone losses with impacted graft and short cemented nail and demonstrating favorable clinical results and durability in the short-term. Conversely, poor results with long-term follow-up (10 years) are demonstrated by Hilgen et al.[37] In this study, of the 29 patients treated with impacted graft and constricted implants, 14 required revision due to mechanical failure at a mean time of 5 years, and in all these cases a lack of graft incorporation and reabsorption was observed during the operation.

Structural Homologous Bone Graft

Structural bone graft from a tissue bank represents a cost-effective option for the treatment of types 2 and 3 AORI bone defects, of varying shapes and sizes, in patients with greater physical demand and future possibility of a new rTKA.[17]

The advantages of using the homologous graft consists of the capacity to restore bone stock and provides adequate initial support to the implants, allows the reinsertion of the epicondyles and avoids additional removal of the host bone.[17] However, in addition to the limited availability in our midst, this technique presents the risk of non-union, resorption and graft fracture, long surgical time, as well as the risk of disease transmission.[12]

The femoral head is the most widely used homologous graft, possibly because of its ability to adapt to various formats of bone defects; however, segmental parts of the distal femur and proximal tibia are also widely used. All the cartilaginous tissue of the graft must be removed, as well as the cortical bone, with preference being given to the use of cancellous bone. The part must be prepared with abundant irrigation to remove the bone marrow components. Acetabular milling cutter is used to remove sclerotic bone in order to potentiate graft-bone host contact and promote its

 © 2021. Sociedade Brasileira de Ortopedia e Traumatologia. All rights reserved.

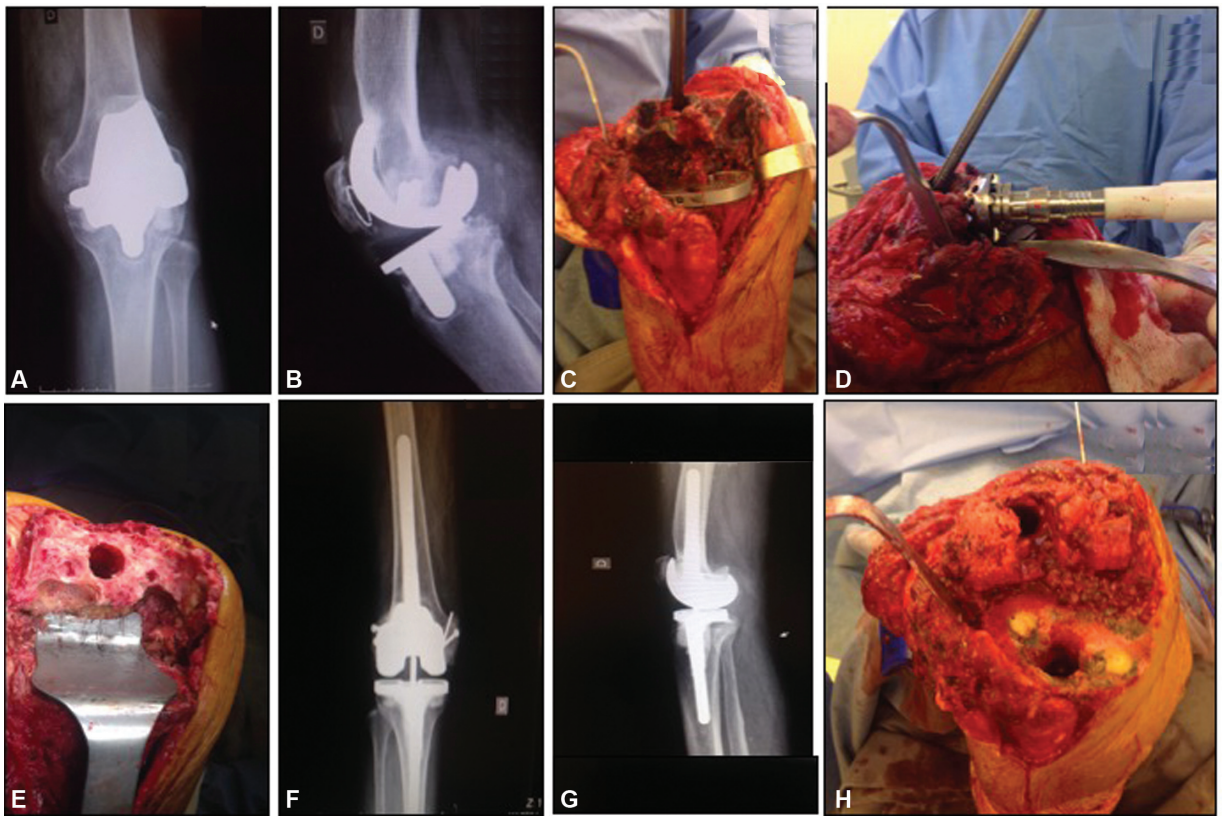

Fig. 1 (A) and (B) anteroposterior radiographs and aseptic loosening profile of total knee prosthesis with marked osteolysis in the distal femur; (C) Intraoperative aspect of the femoral bone defect; (D) Preparation of the graft with an acetabular cutter; (E) Intraoperative appearance after debridement; (F) and (G) Postoperative radiographs of the structural homologous graft fixed with screws in both condyles of the distal femur and revision semi-constricted implants; (H) Intraoperative appearance after using homologous bone graft.

incorporation. Provisional fixation is performed with Kirschner wires to continue making bone cuts with an oscillatory saw. The structural graft is customized to the bone defect. The final fixation, if necessary, can be carried out with screws. The definitive implants are cemented on the homologous graft[12,38] (►**Figure 1**).

In 46 rTKAs using homologous structural graft, Engh and Ammem[38] reported 91% of 10-year survival. Of these patients, four required a new surgical approach. In two of them the graft was incorporated and in two others the graft was removed due to infection. Similarly, Wang et al.[39] studied 30 reviews in which an average of 1.7 homologous femoral heads were used, with an average follow-up of 76 months, and they did not observe graft failure at the end of the evaluation. Conclusions favorable to the capacity of the homologous graft as an adequate option for durable support were obtained by Chun et al.[40] when evaluating the clinical and radiographic results, with an 8-year follow-up of 27 patients, 26 of whom showed no fractures or graft collapses or disease transmission. Similarly, we did not observe fracture or collapse of the homologous graft in a short-term assessment of 26 rTKAs with AORI types 2B and 3 defects; however, in three cases we noticed mild-to-moderate graft absorption without compromising the support function or implant failure, and one patient observed a non-union of segmental graft from the distal femur, but without loss of structural function.[23]

However, doubts and concerns about the durability and maintenance of the structural function of the graft in the long term are not completely clarified. Several studies report the 10-year survival rate of revisions with a structural graft with a mean of 74%.[6,41,42] Unsatisfactory results, however, have been reported by Bauman et al.[41] When evaluating 70 rTKAs, they found survival of 80.7% and 75.9% at, respectively, 5 and 10 years after surgery. Of the 16 cases of failure described, 8 cases were attributed to graft failure, which occurred on average 42 months after surgery. In a systematic review, evaluating 551 rTKAs with homologous graft and mean follow-up of 5.9 years, the reported incidence of any type of graft failure was 6.5%. Deep infection occurred in 5.5% of cases and aseptic loosening in 3.4%.[8]

Trabecular Metal Metaphyseal Cones and Metaphyseal Sleeves

Metaphyseal cones and sleeves represent a modern option for the management of large bone defects, providing immediate structural support and potential biological fixation. Metaphyseal cones come in a variety of sizes and models, allowing the treatment of lesions of varying sizes and configurations. In short, they are indicated for the treatment of AORI types 2 and 3 defects.[6,17,22] The lack of restoration of the bone stock, the need for additional removal of the host bone for correct accommodation of the cones or sleeves and, if necessary, the

 © 2021. Sociedade Brasileira de Ortopedia e Traumatologia. All rights reserved.

difficulty of removal due to biological fixation are the main disadvantages attributed to this option.[6,11,22,43,44]

Proper implantation of both the tantalum cone and the sleeve require the preparation of the host bone. Initially, the metaphysical cones were symmetrical and did not have side specificity; however, with the evolution of the designs, the current cones are asymmetric and can be metaphyseal or diaphyseal. A variety of implant systems can be used with metaphyseal cones, but sleeves are specific implants.[6,7,12,17,45]

It is recommended that the intramedullary test nail be used to obtain correct alignment and direction of the specific cutters to prepare the bed and better adaptation of the cone or sleeve. A burr drill may also be necessary in this debridement. After positioning the metaphyseal cone and repairing the defect, reconstruction proceeds with the placement of prosthetic components. It is noteworthy that the rotation of the cones should favor the better filling of defects and greater contact with the host bone and, thus, they are independent of the rotation of the implants. Eventual non-contact areas from the metaphyseal cone to the host bone should be grafted to favor biological integration. The inner portion of the cones allows cementation of the definitive prosthetic components. However, care should be taken with the use of an offset stem for some systems, given the possibility of difficulties in fitting to the metaphyseal cone (►**Figures 2** e **3**).

The metaphyseal sleeve fits the revision component, and the construction allows limited internal or external rotation to adjust the rotation of the tibial tray and the metaphyseal component. The definitive components are implanted with cement on the surface of the tibial tray, leaving the spinal canal free of cement for biological integration. Eventual removal of these porous devices can be quite difficult.[7,12,43,45,46]

Several clinical studies using tantalum cones for the management of bone defects during rTKA have shown favorable initial results in a short follow-up, with the need for reoperation in only about 1.1%.[43,44,47–51]

In a meta-analysis, evaluating 8 studies with 196 revision surgeries using 233 tantalum cones, with a follow-up of up to 40 months, the authors identified only two cases of aseptic

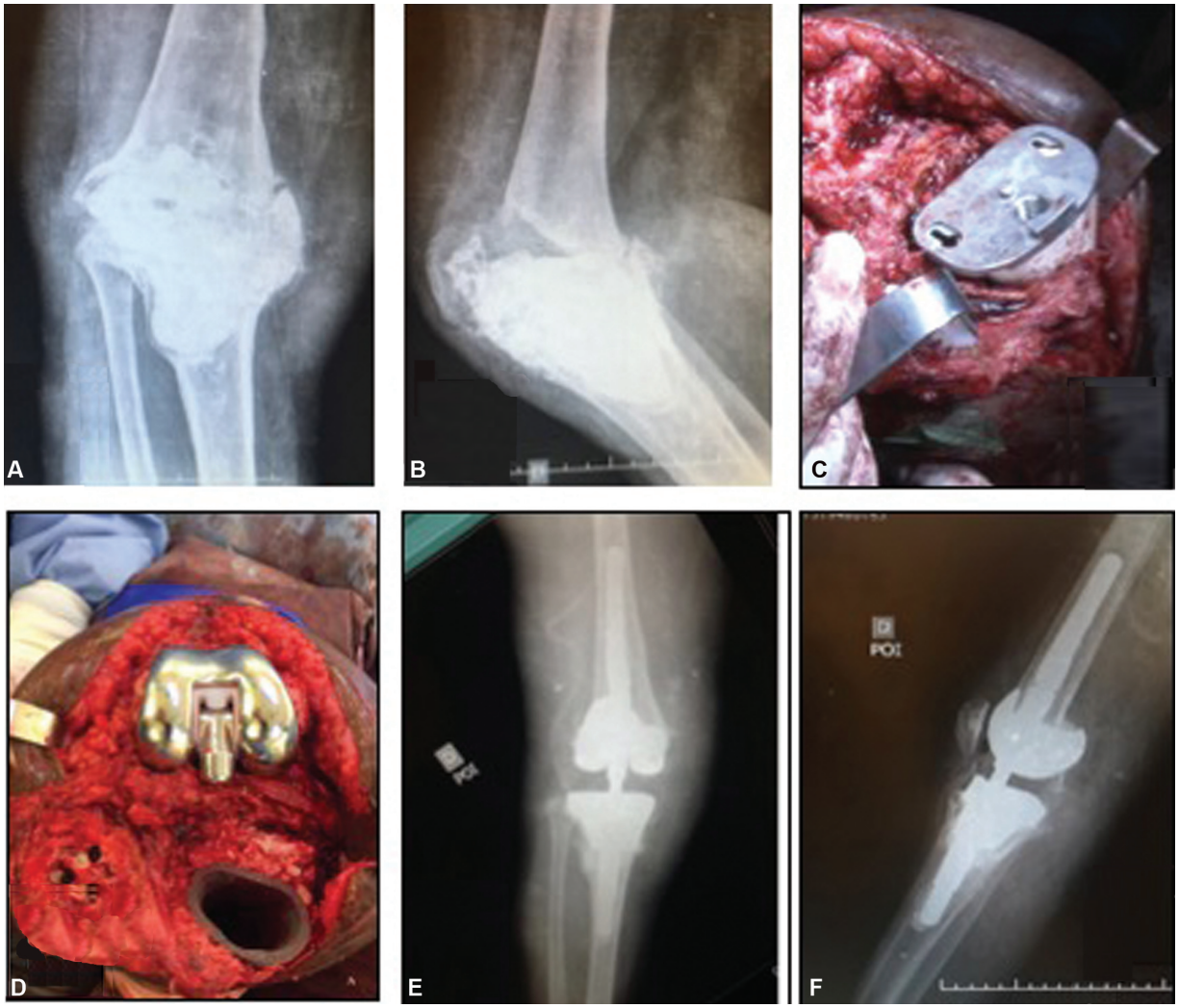

Fig. 2 (A) and (B) Preoperative radiographs of the 2nd revision total knee arthroplasty due to septic failure, with severe bone defect, especially in the proximal tibia; (C) Intraoperative appearance with the test components of the metaphyseal cone and tibial tray; (D) Intraoperative appearance with the tantalum cone implanted in the tibia and with maximum contact with the host bone; (E) and (F) Postoperative radiographs of the revision with contrite implants and metaphyseal cone in proximal tibia.

 © 2021. Sociedade Brasileira de Ortopedia e Traumatologia. All rights reserved.

loosening. The recurrence of infection after a two-stage exchange was the main cause of reoperation.[20]

Systematic review of 20 studies including 812 metaphyseal cones was performed by Divano et al.,[21] showing 94.55% survival in the short-to-medium-term follow-up. The incidence of infection was 7.1%, while the rates of reoperation and revision were, respectively, 16.19% and 8.19%.

Kamath et al.[52] studied 66 reviews using tantalum cones in types 2 and 3 AORI defects, with minimum follow-up between 5 and 9 years, and identified that 23% of the cones had incomplete and non-progressive radiolucent lines and that 3% (two cones) had aseptic loosening. Therefore, the revision-free survival was over 96%, thus demonstrating the maintenance of favorable results in the medium and long terms.[52] Favorable medium-term results were also corroborated by Potter et al.[53]

These favorable results, however, were contested by Bohl et al.,[22] who compared reviews with the use of tantalum cones with the results of rTKA with conventional implants without the use of cones, and concluded that there was no evidence of superiority with the use of metaphyseal cones.

Similarly, Beckmann et al.[8] conducted a systematic review that compared 10 studies with 233 revisions managed using tantalum cones with 17 studies involving 476 revisions that performed large structural grafts. The authors pointed out that, although the results should not be considered conclusive, there are strong indications of better results favorable to the use of trabecular metal.

Short-term assessments of cementless metaphyseal sleeves have been studied by Alexander et al.;[54] these proved to be a promising option for the treatment of types 2B and 3 bone defects, being able to provide stable construction for fixation of implants.

In a prospective study, with a short-term follow-up of 83 rTKA, using 36 femoral and 83 tibial sleeves, 2 patients (2.7%) required revision for aseptic loosening on the tibial side.[46] Satisfactory results, with osteointegration of all sleeves in

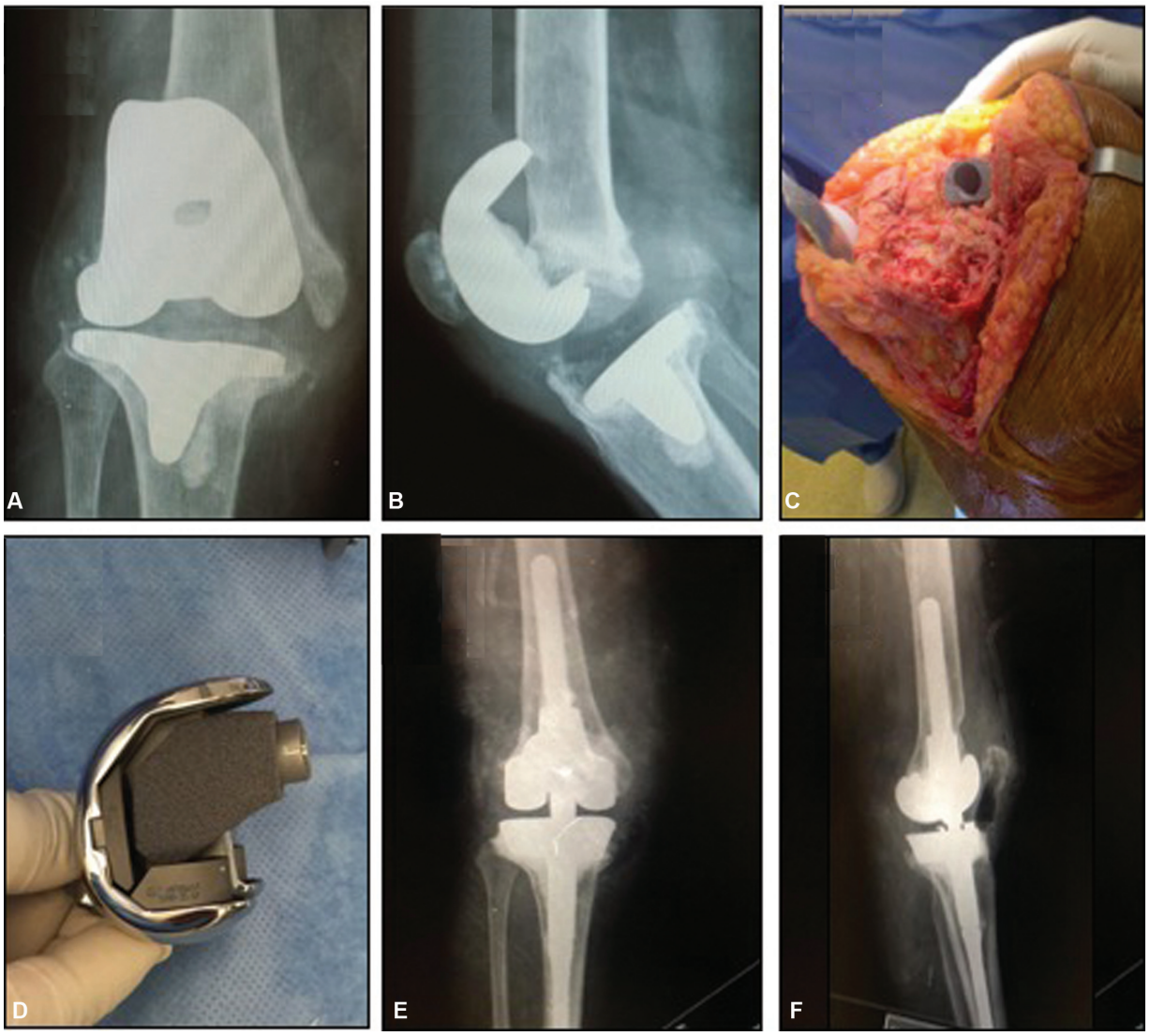

Fig. 3 (A) and (B) Preoperative radiographs of aseptic total knee arthroplasty failure with severe distal femoral defect; (C) metaphyseal tantalum cone positioned to treat bone defect; (D) Profile image of the definitive femoral component plus a tantalum cone and distal and posterior femoral wedges; (E) and (F) Postoperative radiographs.

 © 2021. Sociedade Brasileira de Ortopedia e Traumatologia. All rights reserved.

the short term, were also identified on the tibial side by Barnett et al.[45]

Non-Conventional Prostheses and Customized Mega Prostheses

Unconventional or tumoral prostheses and customized megaprostheses are generally used to replace the entire distal femur or the entire proximal tibia. Thus, they are usually used in oncology, or to treat severe bone loss that is typically found in chronic infection, or after multiple joint reconstruction surgeries, so they are usually atypical indications.[12,17]

Customized implants are usually expensive, require a long time to produce, and often have a high risk of infectious and mechanical complications.[17]

Fraser et al.[55] studied 247 patients treated with hinged megaprostheses for the treatment of severe bone defects, demonstrating revision-free survival, after 8 years, of only 58%. Similarly, Holl et al.[56] identified a high incidence of complications in 11 out of 20 patients who underwent the placement of this type of implant, however without the need for amputation. These results were corroborated by Barry et al.,[57] who demonstrated a high number of complications and reoperations with this treatment, although, according to the authors, it is a viable option for salvage of the limb.

Final Considerations

Proper treatment of bone defects during TKA revisions is a fundamental principle for obtaining satisfactory and long-lasting results. There are several management options with their respective advantages and disadvantages, and there is no option for treating bone failure that is ideal in all circumstances. Therefore, decision making and choice of the method employed is individualized; however, the procedure should focus on the objective of restoring bone stock in patients with the possibility of future revisions.

Conflict of Interests
The authors declare that there is no conflict of interests.

References

1 Kurtz S, Ong K, Lau E, Mowat F, Halpern M. Projections of primary and revision hip and knee arthroplasty in the United States from 2005 to 2030. J Bone Joint Surg Am 2007;89(04):780–785
2 Bozic KJ, Kurtz SM, Lau E, et al. The epidemiology of revision total knee arthroplasty in the United States. Clin Orthop Relat Res 2010;468(01):45–51
3 Bozic KJ, Kamath AF, Ong K, et al. Comparative Epidemiology of Revision Arthroplasty: Failed THA Poses Greater Clinical and Economic Burdens Than Failed TKA. Clin Orthop Relat Res 2015;473(06):2131–2138
4 Delanois RE, Mistry JB, Gwam CU, Mohamed NS, Choksi US, Mont MA. Current Epidemiology of Revision Total Knee Arthroplasty in the United States. J Arthroplasty 2017;32(09):2663–2668
5 Chalmers BP, Pallante GD, Sierra RJ, Lewallen DG, Pagnano MW, Trousdale RT. Contemporary Revision Total Knee Arthroplasty in Patients Younger Than 50 Years: 1 in 3 Risk of Re-Revision by 10 Years. J Arthroplasty 2019;34(7S):S266–S270
6 Sculco PK, Abdel MP, Hanssen AD, Lewallen DG. The management of bone loss in revision total knee arthroplasty: rebuild, reinforce, and augment. Bone Joint J 2016;98-B(1, Suppl A)120–124
7 Chalmers BP, Desy NM, Pagnano MW, Trousdale RT, Taunton MJ. Survivorship of Metaphyseal Sleeves in Revision Total Knee Arthroplasty. J Arthroplasty 2017;32(05):1565–1570
8 Beckmann NA, Mueller S, Gondan M, Jaeger S, Reiner T, Bitsch RG. Treatment of severe bone defects during revision total knee arthroplasty with structural allografts and porous metal cones-a systematic review. J Arthroplasty 2015;30(02):249–253
9 Huten D. Femorotibial bone loss during revision total knee arthroplasty. Orthop Traumatol Surg Res 2013;99(1, Suppl)S22–S33
10 Vasso M, Beaufils P, Cerciello S, Schiavone Panni A. Bone loss following knee arthroplasty: potential treatment options. Arch Orthop Trauma Surg 2014;134(04):543–553
11 Mancuso F, Beltrame A, Colombo E, Miani E, Bassini F. Management of metaphyseal bone loss in revision knee arthroplasty. Acta Biomed 2017;88(2S):98–111
12 Sheth NP, Bonadio MB, Demange MK. Bone Loss in Revision Total Knee Arthroplasty: Evaluation and Management. J Am Acad Orthop Surg 2017;25(05):348–357
13 Dalling JG, Math K, Scuderi GR. Evaluating the progression of osteolysis after total knee arthroplasty. J Am Acad Orthop Surg 2015;23(03):173–180
14 Nadaud MC, Fehring TK, Fehring K. Underestimation of osteolysis in posterior stabilized total knee arthroplasty. J Arthroplasty 2004;19(01):110–115
15 Panegrossi G, Ceretti M, Papalia M, Casella F, Favetti F, Falez F. Bone loss management in total knee revision surgery. Int Orthop 2014; 38(02):419–427
16 Minoda Y, Yoshida T, Sugimoto K, Baba S, Ikebuchi M, Nakamura H. Detection of small periprosthetic bone defects after total knee arthroplasty. J Arthroplasty 2014;29(12):2280–2284
17 Lei PF, Hu RY, Hu YH. Bone Defects in Revision Total Knee Arthroplasty and Management. Orthop Surg 2019;11(01):15–24
18 Engh GA, Parks NL. The management of bone defects in revision total knee arthroplasty. Instr Course Lect 1997;46:227–236
19 Burastero G, Cavagnaro L, Chiarlone F, Alessio-Mazzola M, Carrega G, Felli L. The Use of Tantalum Metaphyseal Cones for the Management of Severe Bone Defects in Septic Knee Revision. J Arthroplasty 2018;33(12):3739–3745
20 Lachiewicz PF, Watters TS. Porous metal metaphyseal cones for severe bone loss: when only metal will do. Bone Joint J 2014;96-B (11, Supple A)118–121
21 Divano S, Cavagnaro L, Zanirato A, Basso M, Felli L, Formica M. Porous metal cones: gold standard for massive bone loss in complex revision knee arthroplasty? A systematic review of current literature. Arch Orthop Trauma Surg 2018;138(06):851–863
22 Bohl DD, Brown NM, McDowell MA, et al. Do Porous Tantalum Metaphyseal Cones Improve Outcomes in Revision Total Knee Arthroplasty? J Arthroplasty 2018;33(01):171–177
23 Cobra HAAB, Junior MCNP, Mozella AP. Homologous structural graft for treatment of bone defect during knee revision arthroplasty. Rev Bras Ortop 2013;48(04):341–347
24 Whittaker JP, Dharmarajan R, Toms AD. The management of bone loss in revision total knee replacement. J Bone Joint Surg Br 2008; 90(08):981–987
25 Ritter MA, Keating EM, Faris PM. Screw and cement fixation of large defects in total knee arthroplasty. A sequel. J Arthroplasty 1993;8(01):63–65
26 Berend ME, Ritter MA, Keating EM, Jackson MD, Davis KE. Use of screws and cement in primary TKA with up to 20 years follow-up. J Arthroplasty 2014;29(06):1207–1210
27 Berend ME, Ritter MA, Keating EM, Jackson MD, Davis KE, Malinzak RA. Use of screws and cement in revision TKA with primary or revision specific prosthesis with up to 17 years followup. J Arthroplasty 2015;30(01):86–89

 © 2021. Sociedade Brasileira de Ortopedia e Traumatologia. All rights reserved.

28 Backstein D, Safir O, Gross A. Management of bone loss: structural grafts in revision total knee arthroplasty. Clin Orthop Relat Res 2006;446(446):104–112
29 Chen F, Krackow KA. Management of tibial defects in total knee arthroplasty. A biomechanical study. Clin Orthop Relat Res 1994;(305):249–257
30 Qiu YY, Yan CH, Chiu KY, Ng FY. Review article: Treatments for bone loss in revision total knee arthroplasty. J Orthop Surg (Hong Kong) 2012;20(01):78–86
31 Patel JV, Masonis JL, Guerin J, Bourne RB, Rorabeck CH. The fate of augments to treat type-2 bone defects in revision knee arthroplasty. J Bone Joint Surg Br 2004;86(02):195–199
32 Werle JR, Goodman SB, Imrie SN. Revision total knee arthroplasty using large distal femoral augments for severe metaphyseal bone deficiency: a preliminary study. Orthopedics 2002;25(03):325–327
33 Hockman DE, Ammeen D, Engh GA. Augments and allografts in revision total knee arthroplasty: usage and outcome using one modular revision prosthesis. J Arthroplasty 2005;20(01):35–41
34 Lotke PA, Carolan GF, Puri N. Technique for impaction bone grafting of large bone defects in revision total knee arthroplasty. J Arthroplasty 2006;21(04, Suppl 1):57–60
35 Lotke PAP, Carolan GF, Puri N. Impaction grafting for bone defects in revision total knee arthroplasty. Clin Orthop Relat Res 2006;446(446):99–103
36 Naim S, Toms AD. Impaction bone grafting for tibial defects in knee replacement surgery. Results at two years. Acta Orthop Belg 2013;79(02):205–210
37 Hilgen V, Citak M, Vettorazzi E, et al. 10-year results following impaction bone grafting of major bone defects in 29 rotational and hinged knee revision arthroplasties: a follow-up of a previous report. Acta Orthop 2013;84(04):387–391
38 Engh GA, Ammeen DJ. Use of structural allograft in revision total knee arthroplasty in knees with severe tibial bone loss. J Bone Joint Surg Am 2007;89(12):2640–2647
39 Wang JW, Hsu CH, Huang CC, Lin PC, Chen WS. Reconstruction using femoral head allograft in revision total knee replacement: an experience in Asian patients. Bone Joint J 2013;95-B(05):643–648
40 Chun CH, Kim JW, Kim SH, Kim BG, Chun KC, Kim KM. Clinical and radiological results of femoral head structural allograft for severe bone defects in revision TKA–a minimum 8-year follow-up. Knee 2014;21(02):420–423
41 Bauman RD, Lewallen DG, Hanssen AD. Limitations of structural allograft in revision total knee arthroplasty. Clin Orthop Relat Res 2009;467(03):818–824
42 Clatworthy MG, Ballance J, Brick GW, Chandler HP, Gross AE. The use of structural allograft for uncontained defects in revision total knee arthroplasty. A minimum five-year review. J Bone Joint Surg Am 2001;83(03):404–411
43 Meneghini RM, Lewallen DG, Hanssen AD. Use of porous tantalum metaphyseal cones for severe tibial bone loss during revision total knee replacement. Surgical technique. J Bone Joint Surg Am 2009;91(Suppl 2 Pt 1):131–138
44 Howard JL, Kudera J, Lewallen DG, Hanssen AD. Early results of the use of tantalum femoral cones for revision total knee arthroplasty. J Bone Joint Surg Am 2011;93(05):478–484
45 Barnett SL, Mayer RR, Gondusky JS, Choi L, Patel JJ, Gorab RS. Use of stepped porous titanium metaphyseal sleeves for tibial defects in revision total knee arthroplasty: short term results. J Arthroplasty 2014;29(06):1219–1224
46 Huang R, Barrazueta G, Ong A, et al. Revision total knee arthroplasty using metaphyseal sleeves at short-term follow-up. Orthopedics 2014;37(09):e804–e809
47 Schmitz HC, Klauser W, Citak M, Al-Khateeb H, Gehrke T, Kendoff D. Three-year follow up utilizing tantal cones in revision total knee arthroplasty. J Arthroplasty 2013;28(09):1556–1560
48 Rao BM, Kamal TT, Vafaye J, Moss M. Tantalum cones for major osteolysis in revision knee replacement. Bone Joint J 2013;95-B(08):1069–1074
49 Mozella AdeP, Olivero RR, Alexandre H, Cobra AB. Use of a trabecular metal cone made of tantalum, to treat bone defects during revision knee arthroplasty. Rev Bras Ortop 2014;49(03):245–251
50 Girerd D, Parratte S, Lunebourg A, et al. Total knee arthroplasty revision with trabecular tantalum cones: Preliminary retrospective study of 51 patients from two centres with a minimal 2-year follow-up. Orthop Traumatol Surg Res 2016;102(04):429–433
51 Villanueva-Martínez M, De la Torre-Escudero B, Rojo-Manaute JM, Ríos-Luna A, Chana-Rodriguez F. Tantalum cones in revision total knee arthroplasty. A promising short-term result with 29 cones in 21 patients. J Arthroplasty 2013;28(06):988–993
52 Kamath AF, Lewallen DG, Hanssen AD. Porous tantalum metaphyseal cones for severe tibial bone loss in revision knee arthroplasty: a five to nine-year follow-up. J Bone Joint Surg Am 2015;97(03):216–223
53 Potter GD III, Abdel MP, Lewallen DG, Hanssen AD. Midterm Results of Porous Tantalum Femoral Cones in Revision Total Knee Arthroplasty. J Bone Joint Surg Am 2016;98(15):1286–1291
54 Alexander GE, Bernasek TL, Crank RL, Haidukewych GJ. Cementless metaphyseal sleeves used for large tibial defects in revision total knee arthroplasty. J Arthroplasty 2013;28(04):604–607
55 Fraser JF, Werner S, Jacofsky DJ. Wear and loosening in total knee arthroplasty: a quick review. J Knee Surg 2015;28(02):139–144
56 Höll S, Schlomberg A, Gosheger G, et al. Distal femur and proximal tibia replacement with megaprosthesis in revision knee arthroplasty: a limb-saving procedure. Knee Surg Sports Traumatol Arthrosc 2012;20(12):2513–2518
57 Barry JJ, Thielen Z, Sing DC, Yi PH, Hansen EN, Ries M. Length of Endoprosthetic Reconstruction in Revision Knee Arthroplasty Is Associated With Complications and Reoperations. Clin Orthop Relat Res 2017;475(01):72–79

 © 2021. Sociedade Brasileira de Ortopedia e Traumatologia. All rights reserved.