Skeletal Radiol (2014) 43:1085–1092
DOI 10.1007/s00256-014-1894-6

SCIENTIFIC ARTICLE

Recurrent anterior glenohumeral instability: the quantification of glenoid bone loss using magnetic resonance imaging

Patrícia Martins e Souza · Bruno Lobo Brandão · Eduardo Brown · Geraldo Motta · Martim Monteiro · Edson Marchiori

Received: 4 February 2014 / Revised: 3 March 2014 / Accepted: 8 April 2014 / Published online: 8 May 2014
© ISS 2014

Abstract
Objective To investigate the accuracy of conventional magnetic resonance imaging (MRI) in determining the severity of glenoid bone loss in patients with anterior shoulder dislocation by comparing the results with arthroscopic measurements.
Subjects and methods Institutional review board approval and written consent from all patients were obtained. Thirty-six consecutive patients (29 men, seven women; mean age, 34.5 [range, 18–55] years) with recurrent anterior shoulder dislocation (≥3 dislocations; mean, 37.9; range, 3–200) and suspected glenoid bone loss underwent shoulder MRI before arthroscopy (mean interval, 28.5 [range, 9–73] days). Assessments of glenoid bone loss by MRI (using the best-fit circle area method) and arthroscopy were compared. Inter- and intrareader reproducibility of MRI-derived measurements was evaluated using arthroscopy as a comparative standard.
Results Glenoid bone loss was evident on MRI and during arthroscopy in all patients. Inter- and intrareader correlations of MRI-derived measurements were excellent (intraclass correlation coefficient=0.80–0.82; r=0.81–0.86). The first and second observers' measurements showed strong (r=0.76) and moderate (r=0.69) interreader correlation, respectively, with arthroscopic measurements.
Conclusions Conventional MRI can be used to measure glenoid bone loss, particularly when employed by an experienced musculoskeletal radiologist.

Keywords Shoulder · Magnetic resonance · Glenoid bone loss · Anterior shoulder instability

P. M. e Souza (✉)
Fleury Medicina e Saúde and Instituto Nacional de Traumatologia e Ortopedia, Rua Soriano de Souza 98, Rio de Janeiro, RJ, Brazil 20.511-180
e-mail: pat_martins@ig.com.br

B. L. Brandão · G. Motta · M. Monteiro
Instituto Nacional de Traumatologia e Ortopedia, Avenida Brasil 500, Rio de Janeiro, RJ, Brazil 20940-070

B. L. Brandão
e-mail: brunolobobrandao@yahoo.com.br

G. Motta
e-mail: gmotta@into.saude.gov.br

M. Monteiro
e-mail: martimtmonteiro@gmail.com

E. Brown
Grupo Fleury Medicina Diagnóstica, Rua Soriano de Souza 98, Rio de Janeiro, RJ, Brazil 20.511-180
e-mail: eduardo.brown@gmail.com

E. Marchiori
Universidade Federal do Rio de Janeiro, Rua Thomaz Cameron, 438, Petrópolis, RJ, Brazil 25685.120
e-mail: edmarchiori@gmail.com

Introduction

Glenoid-rim bone loss is frequently seen in glenohumeral joints with anterior instability, particularly in cases of recurrent shoulder dislocation [1–6]. These bony lesions shorten the glenoid arc, compromising the stability of the joint by reducing the total glenoid contact surface and its concavity [7]. Bone augmentation procedures have been advocated for patients with advanced glenoid bone loss because capsulolabral repair alone may not be sufficient to prevent further dislocation [7–10].

The severity of glenoid bone loss cannot be predicted accurately on the basis of the number of dislocations alone, as it is correlated only modestly with the frequency of these events [2, 11]. The identification and quantification of glenoid bone loss are useful because such information helps to predict the likelihood of further dislocation and to determine the need for bone augmentation surgery to restore shoulder stability [5, 8, 12, 13].

Glenoid bone loss can be quantified with radiography [1, 14, 15], computed tomography (CT) [2, 3, 5, 11, 16–18], magnetic resonance imaging (MRI) [4, 19–22], and arthroscopy [8, 23, 24]. MRI is frequently used to evaluate the glenoid labrum and periarticular soft tissues in patients with anterior shoulder instability. The direct measurement of glenoid bone loss by MRI would provide a more efficient diagnostic pathway than MRI followed by CT [4, 21]. However, few published studies have investigated the role of MRI in the measurement of this parameter [4, 20–22]. The aim of this study was to investigate the accuracy of MRI in determining the severity of glenoid bone loss in patients with anterior shoulder recurrent dislocation by comparing the results with arthroscopic measurements.

Materials and methods

Our institutional ethics committee approved this prospective study and all patients provided informed consent. Between March 2011 and April 2013, we evaluated 36 consecutive patients with posttraumatic recurrent anterior glenohumeral instability and suspected glenoid bone loss. The criteria for patient selection were: at least one documented shoulder dislocation, positive findings of a bony apprehension test, or suspicion of glenoid bone loss based on plain films. The bony apprehension test, a maneuver performed in our physical examination routine, has been demonstrated to be a good screening method for the preoperative assessment of glenoid bone loss [25]. All patients underwent arthroscopy by the same surgeon, which was used as the standard of reference, and shoulder MRI was performed before arthroscopy at an interval of no more than 90 days. Patients who had undergone previous surgery for glenohumeral instability, MRI and arthroscopy at an interval of more than 90 days, or arthroscopic evaluation by another shoulder surgeon, and those in whom glenoid bone loss was not measured at the time of arthroscopy, were excluded. No control group was used.

All MRI examinations were performed at our institution using a scanner with a 1.5-T magnet (Achieva; Philips Medical Systems, Best, Netherlands) with a dedicated shoulder coil. Our routine conventional shoulder MRI protocol consists of the acquisition of axial fat-suppressed fast spin-echo proton density images (repetition time/echo time [TR/TE], 3,300/30 ms; matrix, 208×173; number of excitations [NEX], 3), oblique coronal (parallel to the long axis of the supraspinatus tendon) fat-suppressed fast spin-echo T2-weighted images (TR/TE, 2,100/40–60; matrix, 216×164; NEX, 4), oblique coronal fast spin-echo T2-weighted images without fat suppression (TR/TE, 2,770/80; matrix, 216×180; NEX, 3), oblique sagittal (parallel to the glenohumeral joint) fat-suppressed fast spin-echo T2-weighted images (TR/TE, 2,200/40; matrix, 216×164; NEX, 4), and oblique sagittal T1-weighted images without fat suppression (TR/TE, 440/10; matrix, 216×198; NEX, 2). Sagittal oblique images are planned using oblique coronal and axial images (Fig. 1). A 13-cm field of view was used for all images. Slice thickness was 4 mm with a 10 % interslice gap on all sequences except the fast spin-echo proton density axial sequence, which had a 3-mm slice thickness. For image analysis, which was performed on a Digital Imaging and Communications in Medicine viewer (OsiriX, version 3.5, Pixmeo, Geneva, Switzerland), we used the oblique sagittal T1-weighted image without fat suppression that best included most of the glenoid rim where the inferior two-thirds of the glenoid were most spherical in shape. This best image lies just medial to the first appearance of the glenoid head [4]. The normal glenoid surface is pear shaped, with the inferior two-thirds of the glenoid contour approximately circular [4, 5, 26]. Glenoid bone loss is normally characterized by a relatively smooth and straight anterior edge or smooth anterior glenoid concavity.

We used the circle method proposed by Sugaya et al. [13] for the quantification of glenoid bone defects. Two radiologists with 9 and 3 years of experience in musculoskeletal imaging, respectively, performed all measurements twice at a≥4-week interval. During all analytical procedures, the readers were blinded to each other's results and the arthroscopic findings, but not to the previous occurrence of dislocation in the shoulder being examined. Starting from the geometric assumption that all glenoids can be inscribed in a circle [4, 13, 17, 26–28], the inferior glenoid circle was reconstructed for each patient based on the preserved posteroinferior rim to obtain the "normal glenoid area", expressed in millimeters squared as a reference value. The bone defect was considered to be the missing part of the circle. The size of the osseous defect as a percentage of the glenoid rim was calculated as the ratio of the area of the best-fit circle not occupied by bone (D) to the overall area of the best-fit circle (A) using the equation $D/A \times 100$ (Fig. 2).

A single orthopedic surgeon with 11 years of experience in shoulder surgery performed all arthroscopic examinations and quantified the amount of glenoid bone loss using a validated methodology [23]. A previous study [23] showed that the bare spot on the glenoid is equidistant between the anterior and posterior glenoid margins, and thus can be used as a central reference point, allowing objective measurement of bone loss arthroscopically.

General anesthetic was used for all arthroscopies. Three arthroscopic portals (posterior, anterosuperior, and anteroinferior) were made, and diagnostic arthroscopy was performed using a 4-mm arthroscope (Stryker Endoscopy, San Jose, CA, USA). Under visualization through the anterosuperior portal, a graduated probe with 1-mm calibrated laser marks was introduced through the posterior portal and

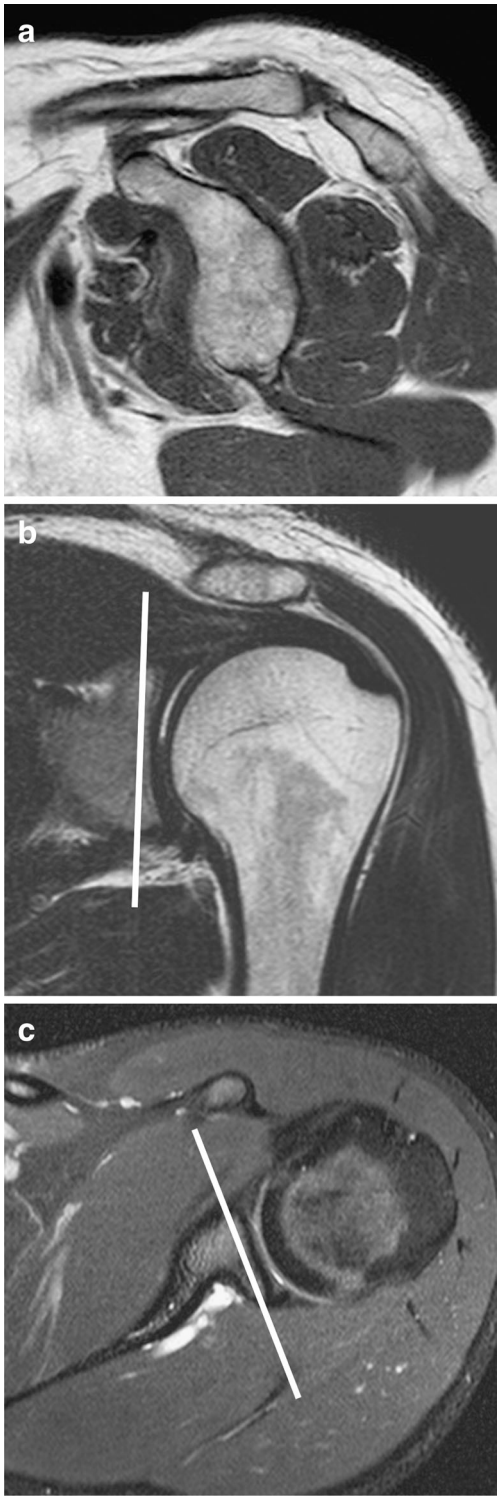

Fig. 1 A 25-year-old man with recurrent shoulder dislocation. **a** Oblique sagittal T1-weighted MR image. This sequence is planned using oblique coronal and axial images. **b** Oblique coronal T2-weighted image showing the plane parallel to the glenoid surface (*white line*). **c** Axial intermediate-weighted fat-suppressed image showing the plane parallel to the glenoid surface (*white line*). This sequence could also be planned using analogous or scout views

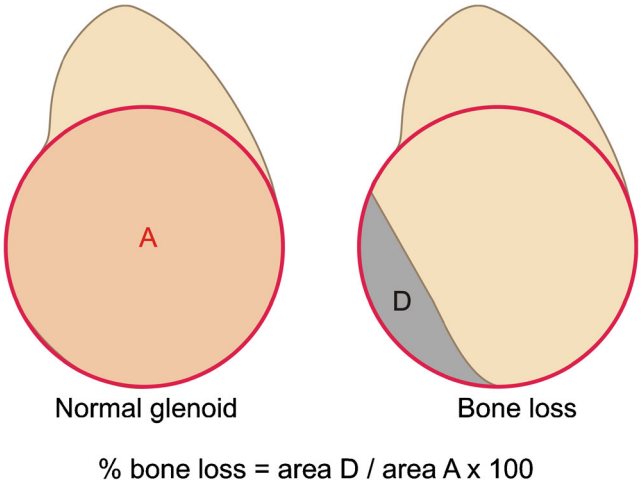

Fig. 2 Schematic representation of an *en face* view of the glenoid showing the measurement of glenoid bone loss. The inferior portion of the glenoid contour can be approximated to a true circle (*in red*). In glenoids with anterior deficiency, the inferior glenoid circle was reconstructed based on the preserved posteroinferior rim. The bone defect was considered to be the missing part of the circle. Areas of the entire circle (A) and bone defect (D) were measured (in millimeters squared) and used to determine the percentage of the missing area. The size of the defect was expressed as a percentage of the entire circle (D/A × 100)

across the glenoid until its tip rested on the bare spot in the center of the inferior half of the glenoid. The distance from the center of the bare spot to the posterior glenoid rim (B) was then measured. The probe was then advanced anteriorly toward the anterior glenoid rim, and the distance from the center of the bare spot to the anterior glenoid rim (A) was measured. The percentage of the area missing was then calculated using the equation 100 × (B–A)/2B (Fig. 3). The arthroscopic finding was considered the reference standard (Fig. 4).

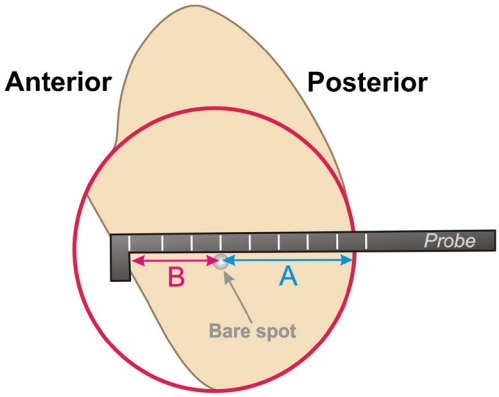

Fig. 3 Schematic representation illustrating the use of an arthroscopic probe (calibrated in 1-mm increments) to quantify the degree of anterior glenoid bone loss with reference to the central bare spot of the glenoid. Assuming that the bare spot lies at the center of the circle formed by the inferior portion of the glenoid, lines A (bare spot to anterior margin) and B (posterior margin to bare spot) must be equal in length in a normal glenoid. Glenoid bone loss is considered to be present when the length of line B exceeds that of line A. Defect size was expressed as a percentage ([B–A] × 100/2B)

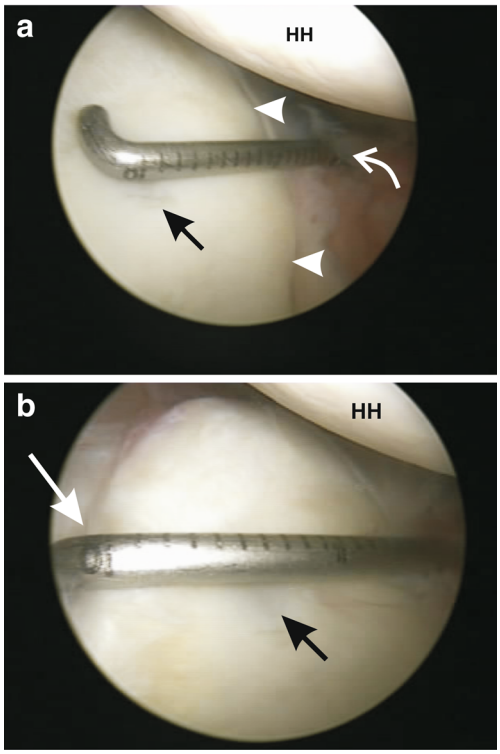

Fig. 4 Arthroscopic view showing the measurement technique. **a** A calibration probe was inserted through the posterior arthroscopic portal (*white curved arrow*) until the tip of the probe reached the bare spot of the glenoid (*black arrow*). *White arrowheads* indicate the posterior margin of the glenoid. **b** The tip of the probe at the anterior margin of the glenoid (*white arrow*). The distance from the posterior margin of the glenoid to the bare spot (*arrow*) is longer than that from the bare spot to the anterior margin of the glenoid, indicating glenoid bone loss (*HH* humeral head)

Statistical analysis

Stata software (version 10.0; StataCorp, College Station, TX, USA) was used for all statistical analyses. Variables were expressed as means and ranges or standard deviations, as appropriate. Pearson's correlation coefficient (r) was used to evaluate the correlation between MRI and arthroscopic quantifications of the percentage of glenoid bone loss, with an r value of 1.0 describing a perfect positive linear correlation, values of 0.2 to 0.4 indicating slight correlation, 0.4–0.7 indicating moderate correlation, and 0.7–1.0 indicating strong correlation. Inter- and intrareader reliability in MRI assessment of glenoid bone loss was determined using the interclass correlation coefficient (ICC). ICC values ranged from 0 to 1 and were interpreted as follows: <0.40, poor agreement; 0.40–0.60, fair agreement; 0.61–0.75, good agreement; and 0.76–1, excellent agreement. Additionally, Bland–Altman analyses were performed to evaluate the agreement between the measurements obtained by both methods and by different observers. For all tests, p <0.05 was considered to indicate statistical significance.

Results

Patient ages ranged from 18 to 55 (mean, 34.5) years. The sample comprised 29 men (mean age, 33 years; range, 18–52 years) and seven women (mean age, 42 years; range, 27–55 years). The number of recurrent dislocations ranged from three to approximately 200 (mean, 37.9). Dislocations were on the right side in 20 of 36 (56 %) patients and on the left side in 16 (44 %) patients. All patients underwent shoulder MRI before arthroscopy. The mean time between MRI examination and arthroscopy was 28.5 (range, 9–73) days.

The application of the best-fit circle area method to MR images demonstrated glenoid bone loss in all 36 (100 %) patients. At the time of first measurement, the first and second observers calculated mean glenoid defect ratios of 21 %± 7.8 % (range, 13–45 %) and 20 %±6.8 % (range, 10–48 %), respectively. Arthroscopy also revealed glenoid bone loss in all 36 patients, with a mean value of 23 %±7.6 % (range, 13–40 %).

Analysis of intra-observer reliability yielded ICC values of 0.93 (95 % confidence interval [CI]=0.88–0.97; p=0.000) for the first observer and 0.81 (95 % CI=0.70–0.92; p=0.000) for the second observer. Analysis of interobserver reliability produced ICC values of 0.80 (95 % CI=0.68–0.92; p=0.000) for the first measurement and 0.82 (95 % CI=0.720–0.918; p= 0.000) for the average measurement.

The first observer's MRI measurements were strongly correlated (r=0.76) and the second observer's were moderately correlated (r=0.69) with arthroscopic findings, considered the gold standard for the measurement of glenoid bone loss. The mean discrepancies between MRI and arthroscopic measurements were 3±4 % (range, 0–17 %) for the first reader and 4± 4 % (range, 0–15 %) for the second reader. The results of Bland–Altman analyses are summarized in Fig. 5.

Discussion

Traumatic shoulder dislocation can be associated with a bony defect of the glenoid rim, which is evident in 80–90 % of individuals with chronic anterior shoulder instability [2, 12, 27]. Glenoid bone loss may arise from glenoid rim fracture or attrition, or impaction fracture by the dislocated humeral head [2]. The likelihood of humeral head dislocation increases with the amount of glenoid bone loss; in turn, dislocation results in even more glenoid bone loss. Depending on defect size, a bone graft may be indicated to avoid shoulder dislocation recurrence [4, 7, 8].

Patients with slight to moderate bone loss are generally treated with arthroscopic soft-tissue stabilization (Bankart repair) alone, whereas those with severe bone loss may require bone graft augmentation [29], but no consensus on the

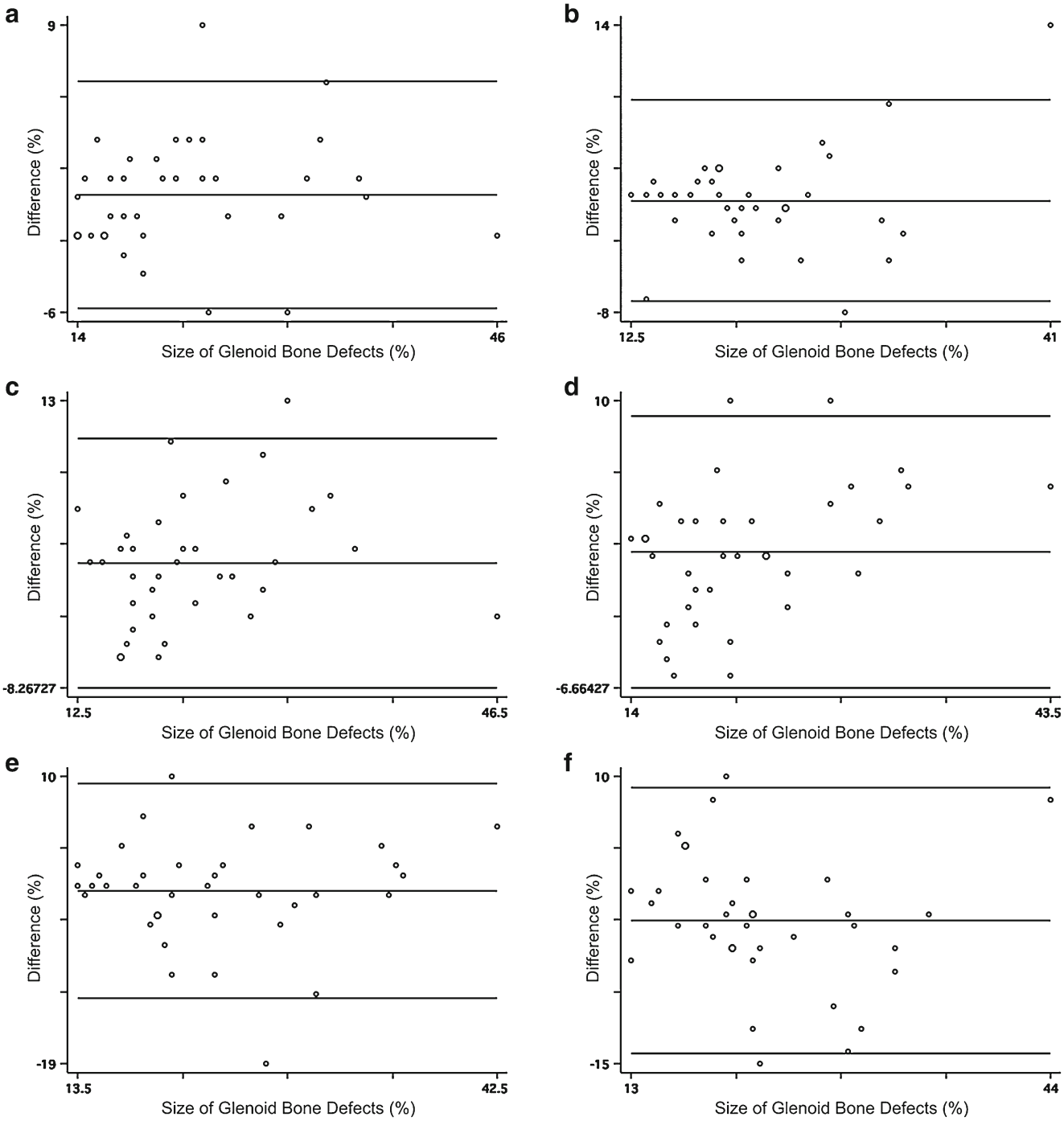

Fig. 5 Bland–Altman analyses. **a**, **b** Differences in measurements (%) of the glenoid defect on magnetic resonance images (MRI) between the two measurements of observer 1 (**a**) and observer 2 (**b**). **c**, **d** Differences in measurements (%) of the glenoid defect on magnetic resonance images (MRI) between the two observers on first measurement (**c**) and average measurements (**d**). **e**, **f** Differences in measurements (%) of the glenoid defect between arthroscopic measurement and magnetic resonance images (MRI) measurements of observer 1 (**e**) and observer 2 (**f**)

definition of severe glenoid bone loss has been reached. Burkhart and DeBeer [7] reported a dislocation recurrence rate of 67 % after arthroscopic Bankart repair in patients with anterior glenohumeral instability and an inverted pear-shaped glenoid, representing>25 % loss, compared with 4 % in patients with no significant bone defect.

Although glenoid bone loss can be quantified during arthroscopy [8, 23, 24], a precise preoperative measurement method has several advantages [28]; it may affect the patient's provision of informed consent based on assessments of prognosis and surgical risk, as well as technical issues such as patient positioning, surgical equipment used, and sterile

preparation for autologous iliac crest bone grafting when coracoid transfer is not selected. Regardless of the diagnostic imaging technique used, the correct preoperative quantification of bony defect size remains challenging [27, 29].

Conventional radiography is used widely to detect osseous abnormalities in patients with glenohumeral instability [13]. A recent radiographic study using the Bernageau view confirmed excellent side-to-side symmetry in normal glenoid width and showed good correlation with CT with regard to the degree of glenoid bone loss [15], but this method does not reliably detect glenoid abnormalities in patients with traumatic glenohumeral instability [13, 14].

CT measurements of glenoid bone loss have shown good correlation with arthroscopic measurements [4, 11], and CT is the modality of choice for the detection of bony abnormalities in patients with glenohumeral instability [2, 3, 5, 11, 13, 16–21]. In cases of unilateral dislocation, simultaneous examination of the dislocated and contralateral normal shoulders allows ready comparison of glenoid dimensions [5, 27]. CT arthrography has the same advantages of CT in evaluation of glenoid bony defects and additionally allows assessment of labroligamentous lesions related to shoulder instability [30]. Acid et al. [31] suggest that multidetector computed tomography arthrography is a method of choice for the preoperative planning of anterior shoulder instability.

Sugaya et al. [13] described a method of preoperative defect measurement on three-dimensional (3D) CT images, which does not require knowledge of original glenoid size because its original contour is indicated by a superimposed circle drawn on inferior aspect of the glenoid. Measurement of glenoid bone defects in patients with anterior shoulder instability can also be assessed with the Pico method, which is based on calculation of the missing area of the glenoid using the circle method on sagittal *en face* images and could be used without comparison with the contralateral shoulder [18]. Huijsmans et al. [19] used the circle method proposed by Sugaya et al. [13] to validate glenoid defect quantification based on 3D CT and 3D MR images in 14 cadaver shoulders. In a similar study, Gyftopoulos et al. accurately measured glenoid bone loss in 18 cadaver shoulders using MRI, CT, and 3D CT [21]. Nevertheless, the use of bare cadaveric glenoids for measurement without adjacent soft-tissue structures does not simulate normal imaging anatomy.

Tian et al. [20] showed excellent correlation in the detection of glenoid bone loss using the best-fit circle width method on multidetector CT images and fat-suppressed 3D volumetric interpolated breath-hold MR arthrography in 41 subjects with recurrent shoulder dislocation. Lee et al. [4] investigated agreement in the measurement of glenoid bone loss among MR arthrography, CT, and arthroscopy, and showed that MRI assessment using the Pico method is almost as accurate as CT assessment. However, they analyzed direct MR arthrographic images, which are used less widely than conventional MRI because this procedure is time consuming, minimally invasive, and although generally safe, associated with some risk. In addition, they used 3D T1-weighted *en face* images of the glenoid with high spatial resolution, 1.5-mm-thick sections, and 0.75-mm overlap. A recent study showed that measurements of glenoid bone loss performed on 3D MR reconstructions of the shoulder using an axial 3D dual echo-time T1-weighted FLASH sequence with Dixon-based water–fat separation can be used to accurately measure glenoid bone loss. However, this sequence is not always available and has a long post-processing time for each shoulder [22].

Our study has compared the accuracy of routine conventional MRI with that of arthroscopy as a standard technique in determining the severity of glenoid bone loss in the clinical setting. Excellent intrareader and interreader correlations of MRI-derived measurements of glenoid bone loss using the best-fit circle method and moderate to strong correlations of these measurements with those obtained by arthroscopy (considered the gold standard) were observed in this study. The moderate correlation can be explained by the second radiologist's lack of experience in the interpretation of glenoid bone loss, suggesting that specific training is advisable to ensure excellent performance. This agrees with the findings of Gyftopoulos et al. [21], showing that accuracy of glenoid bone loss quantification using the circle method depends greatly on the level of familiarity of the interpreting radiologist with this technique.

Previous studies have demonstrated that CT is somewhat more accurate than MRI and should probably still be considered the gold standard for the preoperative evaluation of glenoid bone loss, especially when a normal contralateral shoulder can be used for comparison [4]. However, in conformity with previous findings [4, 19, 20], our results show that routine conventional MRI is also an acceptable method for the quantification of glenoid bone loss. The advantages of MRI over CT include the ability to assess soft-tissue and bone abnormalities in a single examination and the reduction of radiation exposure in this anatomical area, located close to the thyroid and breast. Moreover, independent of the imaging method used, the quantification of glenoid bone defects using the best-fit circle method is not completely accurate, as it depends to some extent on manual work [13]. As commented by previous authors, determining the exact size of the circle is one of the main difficulties [21]. Even subtle differences in circle drawing can cause discrepancies between measurements (Fig. 6). Furthermore, the inferior two-thirds of the glenoid are not always completely circular in shape (Fig. 7).

Considering the practical aspects of MRI, our results suggest that it can be considered a good screening method. In clinical practice, CT will not provide additional information that could modify the surgical decision when MRI shows a very small (<15 %) or very large (>25 %) defect. CT is indicated in cases of moderate (15–25 %) bone loss, given

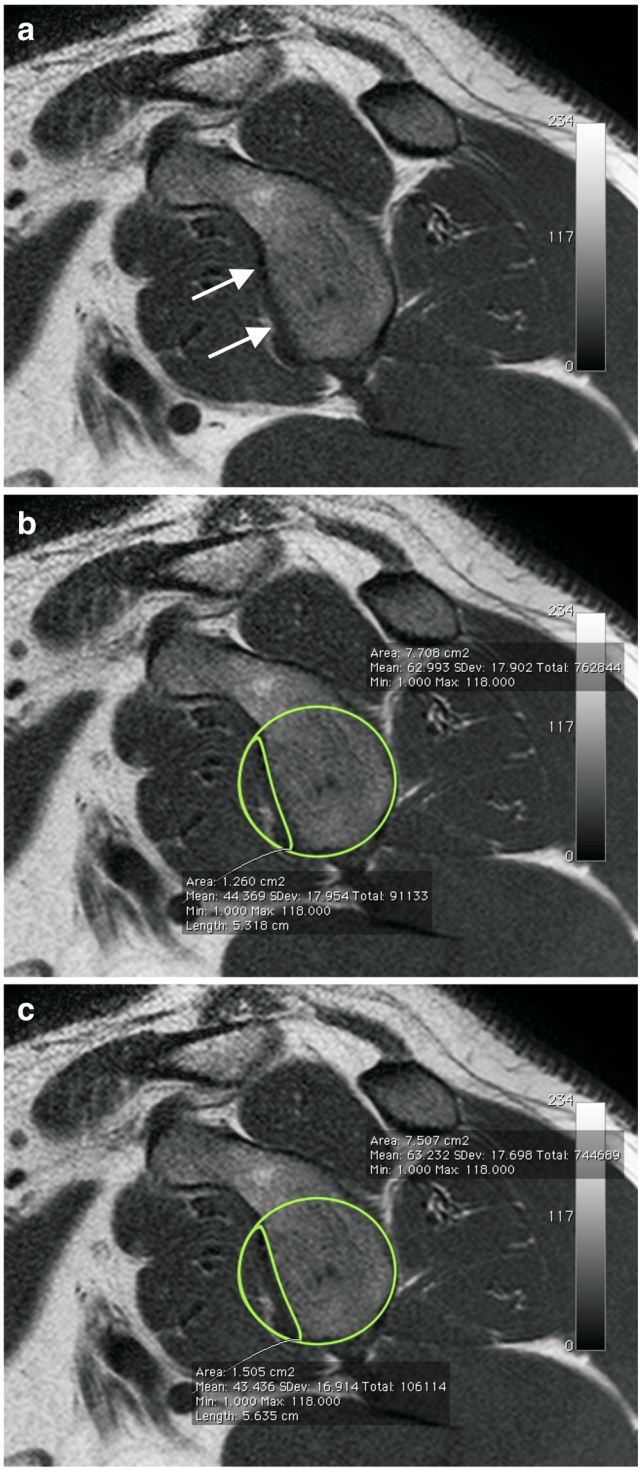

Fig. 6 A 25-year-old man with recurrent shoulder dislocation. **a** Oblique sagittal T1-weighted MR image shows straightening of the normally curved anterior glenoid rim (*white arrows*). Glenoid bone loss was estimated to be 15 % by arthroscopic measurement and was considered to be slight by the surgeon. Arthroscopic labral (Bankart) repair was performed. **b** The area of the osseous glenoid defect was measured manually with the best-fit circle method. The first reader estimated 16 % glenoid bone loss, similar to the arthroscopic finding. **c** Subtle differences in circle drawing can cause significant discrepancies between measurements; the second reader estimated 20 % glenoid bone loss

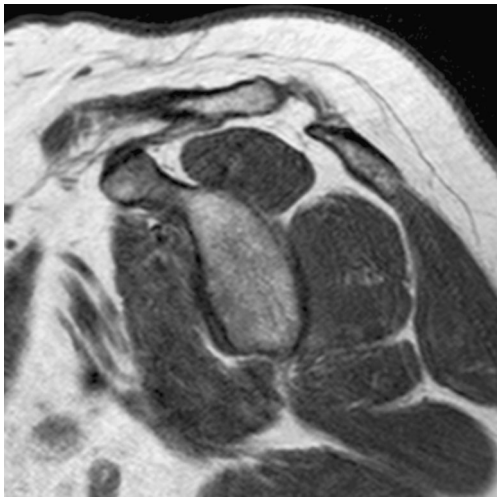

Fig. 7 Oblique sagittal T1-weighted MR image obtained *en face* to the glenoid, showing that the inferior two-thirds of the glenoid do not always conform to a true circle. Significant discrepancies among measurements occurred in this case: 30 % by arthroscopy, 25 % by the first reader, and 16 % by the second reader

the chance of error in this estimate that could affect the surgical technique.

This study has several limitations that can be considered inherent to the materials and methods used. The use of arthroscopy as the gold standard for glenoid bone measurement may be questioned due to several issues with this technique [32]. First, the bare spot may occasionally comprise a bare area, rather than a discrete spot [11]. Second, the boundary between bone and soft tissue is not always clear on the posterior edge of the glenoid [13]. Third, the calibrated probe may not be aligned perpendicular to the long axis of the glenoid. Nevertheless, the arthroscopic quantification of glenoid bone loss using the bare spot as a reference point has been described as an accurate and well-accepted guide for the identification of significant bone loss [23].

All surgical treatment decisions were based on clinical data, arthroscopic findings, and measurements, and the surgeon had access to MR images at the time of surgery, but not to glenoid bone loss values, as such reporting is not usual in clinical practice. In MRI analyses, observers were not blinded to whether the examined shoulder had previously dislocated. This bias is difficult to remove because MRI shows typical findings indicative of dislocation. Although MR images were obtained directly *en face* to the glenoid, such acquisition is operator dependent and could influence the measurement if not properly performed.

In conclusion, conventional MRI is frequently used to evaluate the glenoid labrum and periarticular soft tissues in cases of anterior shoulder dislocation. This tool can be useful for the assessment of glenoid bone loss in the majority of cases, particularly when employed by an experienced musculoskeletal radiologist. For patients on the borderline between requiring soft-tissue repair or a bone block procedure, CT

should be performed following MRI to aid in surgical planning.

Conflict of interest The authors declare that they have no conflicts of interest to disclose.

References

1. Edwards TB, Boulahia A, Walch G. Radiographic analysis of bone defects in chronic anterior shoulder instability. Arthrosc J Arthrosc Relat Surg Off Publ Arthrosc Assoc N Am Int Arthrosc Assoc. 2003;19:732–9.
2. Griffith JF, Antonio GE, Yung PSH, Wong EMC, Yu AB, Ahuja AT, et al. Prevalence, pattern, and spectrum of glenoid bone loss in anterior shoulder dislocation: CT analysis of 218 patients. AJR Am J Roentgenol. 2008;190:1247–54.
3. Barchilon VS, Kotz E, Barchilon Ben-Av M, Glazer E, Nyska M. A simple method for quantitative evaluation of the missing area of the anterior glenoid in anterior instability of the glenohumeral joint. Skeletal Radiol. 2008;37:731–6.
4. Lee RKL, Griffith JF, Tong MMP, Sharma N, Yung P. Glenoid bone loss: assessment with MR imaging. Radiology. 2013;267:496–502.
5. Griffith JF, Antonio GE, Tong CWC, Ming CK. Anterior shoulder dislocation: quantification of glenoid bone loss with CT. AJR Am J Roentgenol. 2003;180:1423–30.
6. Bencardino JT, Gyftopoulos S, Palmer WE. Imaging in anterior glenohumeral instability. Radiology. 2013;269:323–37.
7. Burkhart SS, De Beer JF. Traumatic glenohumeral bone defects and their relationship to failure of arthroscopic Bankart repairs: significance of the inverted-pear glenoid and the humeral engaging Hill-Sachs lesion. Arthrosc J Arthrosc Relat Surg Off Publ Arthrosc Assoc N Am Int Arthrosc Assoc. 2000;16:677–94.
8. Millett PJ, Clavert P, Warner JJP. Open operative treatment for anterior shoulder instability: when and why? J Bone Joint Surg Am. 2005;87:419–32.
9. Boileau P, Villalba M, Héry J-Y, Balg F, Ahrens P, Neyton L. Risk factors for recurrence of shoulder instability after arthroscopic Bankart repair. J Bone Joint Surg Am. 2006;88:1755–63.
10. Lynch JR, Clinton JM, Dewing CB, Warme WJ, Matsen 3rd FA. Treatment of osseous defects associated with anterior shoulder instability. J Shoulder Elb Surg Am Shoulder Elb Surg Al. 2009;18:317–28.
11. Griffith JF, Yung PSH, Antonio GE, Tsang PH, Ahuja AT, Chan KM. CT compared with arthroscopy in quantifying glenoid bone loss. AJR Am J Roentgenol. 2007;189:1490–3.
12. Bigliani LU, Newton PM, Steinmann SP, Connor PM, Mcllveen SJ. Glenoid rim lesions associated with recurrent anterior dislocation of the shoulder. Am J Sports Med. 1998;26:41–5.
13. Sugaya H, Moriishi J, Dohi M, Kon Y, Tsuchiya A. Glenoid rim morphology in recurrent anterior glenohumeral instability. J Bone Joint Surg Am. 2003;85-A:878–84.
14. Itoi E, Lee S-B, Amrami KK, Wenger DE, An K-N. Quantitative assessment of classic anteroinferior bony Bankart lesions by radiography and computed tomography. Am J Sports Med. 2003;31:112–8.
15. Murachovsky J, Bueno RS, Nascimento LGP, Almeida LHO, Strose E, Castiglia MT, et al. Calculating anterior glenoid bone loss using the Bernageau profile view. Skeletal Radiol. 2012;41:1231–7.
16. Chuang T-Y, Adams CR, Burkhart SS. Use of preoperative three-dimensional computed tomography to quantify glenoid bone loss in shoulder instability. Arthrosc J Arthrosc Relat Surg Off Publ Arthrosc Assoc N Am Int Arthrosc Assoc. 2008;24:376–82.
17. D' Elia G, Di Giacomo A, D'Alessandro P, Cirillo LC. Traumatic anterior glenohumeral instability: quantification of glenoid bone loss by spiral CT. Radiol Med (Torino). 2008;113:496–503.
18. Magarelli N, Milano G, Sergio P, Santagada DA, Fabbriciani C, Bonomo L. Intra-observer and interobserver reliability of the "Pico" computed tomography method for quantification of glenoid bone defect in anterior shoulder instability. Skeletal Radiol. 2009;38:1071–5.
19. Huijsmans PE, Haen PS, Kidd M, Dhert WJ, van der Hulst VPM, Willems WJ. Quantification of a glenoid defect with three-dimensional computed tomography and magnetic resonance imaging: a cadaveric study. J Shoulder Elb Surg Am Shoulder Elb Surg Al. 2007;16:803–9.
20. Tian C-Y, Shang Y, Zheng Z-Z. Glenoid bone lesions: comparison between 3D VIBE images in MR arthrography and nonarthrographic MSCT. J Magn Reson Imaging JMRI. 2012;36:231–6.
21. Gyftopoulos S, Hasan S, Bencardino J, Mayo J, Nayyar S, Babb J, et al. Diagnostic accuracy of MRI in the measurement of glenoid bone loss. AJR Am J Roentgenol. 2012;199:873–8.
22. Gyftopoulos S, Beltran LS, Yemin A, Strauss E, Meislin R, Jazrawi L, et al. Use of 3D MR reconstructions in the evaluation of glenoid bone loss: a clinical study. Skeletal Radiol. 2014;43:213–8.
23. Burkhart SS, Debeer JF, Tehrany AM, Parten PM. Quantifying glenoid bone loss arthroscopically in shoulder instability. Arthrosc J Arthrosc Relat Surg Off Publ Arthrosc Assoc N Am Int Arthrosc Assoc. 2002;18:488–91.
24. Provencher MT, Detterline AJ, Ghodadra N, Romeo AA, Bach Jr BR, Cole BJ, et al. Measurement of glenoid bone loss: a comparison of measurement error between 45 degrees and 0 degrees bone loss models and with different posterior arthroscopy portal locations. Am J Sports Med. 2008;36:1132–8.
25. Bushnell BD, Creighton RA, Herring MM. The bony apprehension test for instability of the shoulder: a prospective pilot analysis. Arthrosc J Arthrosc Relat Surg Off Publ Arthrosc Assoc N Am Int Arthrosc Assoc. 2008;24:974–82.
26. De Wilde LF, Berghs BM, Audenaert E, Sys G, Van Maele GO, Barbaix E. About the variability of the shape of the glenoid cavity. Surg Radiol Anat SRA. 2004;26:54–9.
27. Nofsinger C, Browning B, Burkhart SS, Pedowitz RA. Objective preoperative measurement of anterior glenoid bone loss: a pilot study of a computer-based method using unilateral 3-dimensional computed tomography. Arthrosc J Arthrosc Relat Surg Off Publ Arthrosc Assoc N Am Int Arthrosc Assoc. 2011;27:322–9.
28. Huijsmans PE, Witte PB, Villiers RVP, Wolterbeek DW, Warmerdam P, Kruger NR, et al. Recurrent anterior shoulder instability: accuracy of estimations of glenoid bone loss with computed tomography is insufficient for therapeutic decision-making. Skeletal Radiol. 2011;40:1329–34.
29. Diederichs G, Seim H, Meyer H, Issever AS, Link TM, Schröder RJ, et al. CT-based patient-specific modeling of glenoid rim defects: a feasibility study. AJR Am J Roentgenol. 2008;191:1406–11.
30. Lecouvet FE, Simoni P, Koutaïssoff S, Vande Berg BC, Malghem J, Dubuc J-E. Multidetector spiral CT arthrography of the shoulder. Clinical applications and limits, with MR arthrography and arthroscopic correlations. Eur J Radiol. 2008;68:120–36.
31. Acid S, Le Corroller T, Aswad R, Pauly V, Champsaur P. Preoperative imaging of anterior shoulder instability: diagnostic effectiveness of MDCT arthrography and comparison with MR arthrography and arthroscopy. AJR Am J Roentgenol. 2012;198:661–7.
32. Kralinger F, Aigner F, Longato S, Rieger M, Wambacher M. Is the bare spot a consistent landmark for shoulder arthroscopy? A study of 20 embalmed glenoids with 3-dimensional computed tomographic reconstruction. Arthrosc J Arthrosc Relat Surg Off Publ Arthrosc Assoc N Am Int Arthrosc Assoc. 2006;22:428–32.