Article published online: 2023-10-30

Acute Distal Biceps Tendon Injury: Diagnosis and Treatment

Lesões agudas do tendão distal do bíceps: Diagnóstico e tratamento

Luiz Henrique Boraschi Vieira Ribas[1,2] Breno Schor[2] Geraldo da Rocha Motta Filho[3] Paulo Santoro Belangero[4]

[1] Postgraduate programme student, Orthopedics and Traumatology Department, Escola Paulista de Medicina (EPM), Universidade Federal de São Paulo (Unifesp), São Paulo, SP, Brazil.
[2] Orthopaedic doctor specialising in Shoulder and Elbow, Instituto Vita, São Paulo, SP, Brazil.
[3] Orthopaedic doctor specialising in Shoulder and Elbow, Instituto Nacional de Traumatologia e Ortopedia (INTO), Rio de Janeiro, RJ, Brazil.
[4] Orthopaedic Physician, Orthopedics and Traumatology Department, Escola Paulista de Medicina (EPM), Universidade Federal de São Paulo (Unifesp), São Paulo, SP, Brazil.

Address for correspondence Geraldo da Rocha Motta Filho, MD, MSc, Centro de Cirurgia do Ombro e Cotovelo, Instituto Nacional de Traumatologia e Ortopedia Jamil Haddad – INTO – RJ/MS, Avenida Brasil, 500, São Cristóvão, Rio de Janeiro, Rio de Janeiro, 20940-070, Brasil (e-mail: geraldomotta@terra.com.br).

Rev Bras Ortop 2023;58(5):e689–e697.

Abstract

Acute distal biceps injuries clinically present with sudden pain and acute loss of flexion and supination strength. The main injury mechanism occurs during the eccentric load of the biceps. The hook test is the most significant examination test, presenting the highest sensibility and specificity for this lesion. Magnetic resonance imaging, the gold standard imaging test, can provide information regarding integrity and identify partial and/or complete tears. The surgical treatment uses an anterior or double approach and several reattachment techniques. Although there is no clinical evidence to recommend one fixation method over the other, biomechanical studies show that the cortical button resists better to failure. Although surgical treatment led to an 89% rate of return to work in 14 weeks, the recovery of high sports performance occurred in 1 year, with unsustainable outcomes.

Keywords
- elbow joint/injuries
- muscle, skeletal
- rupture
- tendon injuries

Resumo

As lesões agudas do tendão distal do bíceps se apresentam, clinicamente, com uma dor súbita associada a perda aguda de força de flexão e supinação. Seu principal mecanismo de lesão ocorre durante contração excêntrica do bíceps. O “Hook Test” é o principal teste semiológico, sendo o mais sensível e específico. A ressonância magnética, exame padrão ouro para o diagnóstico, pode fornecer informações sobre a integridade, identificando as lesões parciais e/ou completas. O tratamento cirúrgico

received
June 4, 2022
accepted
April 12, 2023

DOI https://doi.org/10.1055/s-0043-1771488.
ISSN 0102-3616.

© 2023. Sociedade Brasileira de Ortopedia e Traumatologia. All rights reserved.
This is an open access article published by Thieme under the terms of the Creative Commons Attribution-NonDerivative-NonCommercial-License, permitting copying and reproduction so long as the original work is given appropriate credit. Contents may not be used for commercial purposes, or adapted, remixed, transformed or built upon. (https://creativecommons.org/licenses/by-nc-nd/4.0/)
Thieme Revinter Publicações Ltda., Rua do Matoso 170, Rio de Janeiro, RJ, CEP 20270-135, Brazil

Palavras-chave
- articulação do cotovelo/lesões
- músculo esquelético
- ruptura
- lesões dos tendões

pode ser realizado por duas vias principais: anterior e por dupla via porém as técnicas de reinserção tendínea são diversas não havendo evidência clínica que recomende um método de fixação em detrimento ao outro; embora o botão cortical apresente maior resistência a falha nos estudos biomecânicos. Com o tratamento cirúrgico o retorno as atividades laborais foi de 89% em 14 semanas (média) porém ao esporte de alto rendimento o prazo foi longo, média de 1 ano, e não duradouro.

Introduction

Injuries to the distal tendon of the biceps brachii are infrequent, accounting for 3% of all bicipital tears.[1,2] Tears most commonly occur due to eccentric loading, such as a fall on an outstretched hand, extended elbow when lifting weight, or even an abrupt elbow extension with the arm in supination.[3]

Idler et al.[4] reported tendon ruptures between 204 N and 222 N,[4] contrasting with Garcia Júnior et al.,[5] who documented injuries under eccentric forces higher than 400 N.[5] The normal tension of the biceps tendon with the elbow at a 90° flexion is approximately 50 N.[6]

The biceps brachii consists of two heads. The long head (LH) originates from the supraglenoid tubercle, whereas the short head (SH) starts at the coracoid process and attaches to the bicipital radial tuberosity (RT).[7]

The tendons can remain distinct throughout their course (in 90% of the specimens)[8] with some interdigitation degree between the heads or form a single tendon.[9] The tendon externally rotates 90° on its axis in an ulnar-to-radial direction until its attachment.[9] LH has an oval shape and attaches at the most proximal portion of the tuberosity, providing greater supination strength. SL attaches distally in a fan shape, generating greater flexion strength.[7] A branch of the musculocutaneous nerve provides innervation.[10]

The incidence of these injuries increased from 1.2 in 2002[1] to 2.55 per 100,000 patients/year in 2015, with a 2.5% annual increment.[11]

Two theories explain ruptures: *1) Vascular:* resulting from a low-irrigation zone between the proximal and distal portions of the biceps tendon (►**Fig. 1**); *2) Mechanic:* in complete supination, the tendon occupies 85% of the area between the radium and the ulna; in contrast, in complete pronation, this space diminishes to 50%.[12]

Risk factors include smoking, which increases the chance of tendon rupture by 7.5-fold,[1] anabolic steroids abuse[13], and overweight and/or obesity (body mass index [BMI] > 30 kg/m^2), associated with a 66.7% tear rate.[3]

Bilateral, non-simultaneous injuries occur in 8% of patients, suggesting that previous changes are risk factors for ruptures on the unaffected side.[14] Simultaneous injuries are rare and described in case reports.[15]

Approximately two-thirds of the traumatic ruptures occurred in patients between 35 and 54 years old (mean, 46.3 years old). Most (95.7%) subjects were male, and injuries showed no preference for the dominant side.[3] In more than

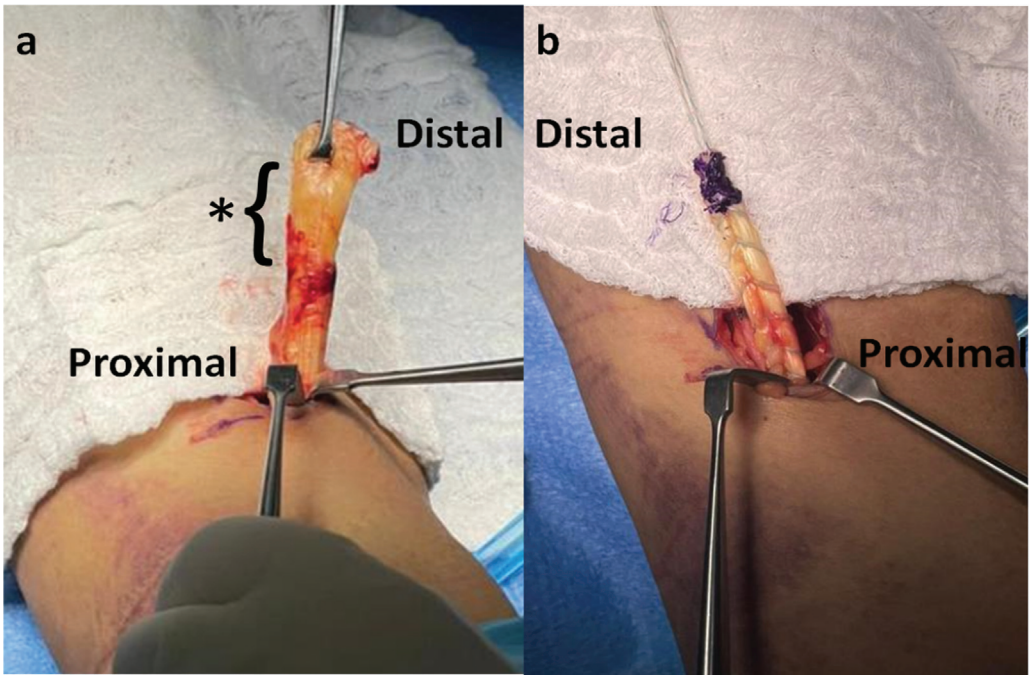

Fig. 1 Macroscopic evaluation of the distal biceps tendon
Note: Macroscopic appearance of the ruptured distal biceps tendon (degeneration and thickening of its distal portion visualized), *Hypovascular zone of the distal biceps tendon measuring approximately 2.14 cm in length; b) Tendinous preparation, Krakow type suture, with high resistance thread.

 © 2023. Sociedade Brasileira de Ortopedia e Traumatologia. All rights reserved.

50% of cases, female patients reported insidious and atraumatic onset of symptoms, and 87% had partial lesions.[16]

Partial lesions are rarer, typically affect the short head, and may even occur at the musculotendinous junction.[3,11]

The clinical picture consists of pain, often associated with physical exertion, with no audible clicking, presenting bicipital belly rise and potentially a reverse "Popeye" sign followed by decreased strength for elbow flexion (30% loss) and forearm supination (40% loss).[1,2,11] In addition, patients report difficulties in carrying out day-to-day activities and greater physical, work, or both demands.[1]

Clinical Assessment

Devereaux and ElMaragh[3] reported that 33% of the cases with painful clicking had complete tendon ruptures. The reverse "Popeye" sign was present in 38% of total injuries and 33% of partial injuries. Edema and ecchymosis were only present in acute injuries, i.e., less than 3 weeks. However, if the bicipital aponeurosis remained intact, the hematoma may not drain and be confined to deeper planes.[3]

The most used examination maneuvers are the hook test, the passive pronation test, and the bicipital gap test. When positive for injury, these tests have 100% sensitivity and specificity[3] (►**Table 1**). These maneuvers also include tests for assessing resisted supination and flexion strength.[2]

Table 1 Sensitivity and specificity of semiologic tests for distal biceps tendon injury

	Sensitivity	*Specificity*
Hook Test[18]	81%	100%
Updated Hook Test[20]	86%	89%
Passive Pronation Test[26]	95%	100%
Bicipital Interval Test[22]	88%	50%

*Positivity of the 3 tests = 100% sensitivity and specificity for injury.
**Complete injuries with tendon retraction (S:92%); no shrinkage (S:78%) and partial lesions (S:30%).

O'Driscoll et al.[18] introduced the hook test, which presents 81% sensitivity and 100% specificity alone. This test occurs with the elbow at a 90° flexion and maximum supination maintained by one of the examiner's hands. The index finger of the examiner's contralateral hand performs the hook movement from lateral to medial. The test is positive if no tendon support limits the excursion of the index finger. Its performance from medial to lateral may cause a false-negative result if the bicipital aponeurosis is intact.[18] However, if there are no criteria for integrity or injury, the resisted hook test is required[19] (►**Fig. 2**). This test consists of performing resistance against the patient's active pronation associated with the hook test; it is positive for injury if painful or if the tendon is absent.[19]

Fig. 2 Resisted "Hook Test"
Note: Test performed with resistance to active pronation of the patient associated with the "Hook Test"; if the tendon is painful or absent the test will be positive for injury.

 © 2023. Sociedade Brasileira de Ortopedia e Traumatologia. All rights reserved.

In 2020, Luokkala et al.[20] updated the sensitivity of the hook test by comparing it with intraoperative findings in 202 patients. The overall sensitivity of the test was 86%, including 92% for complete lesions with stump retraction, 78% for those without retraction, 45% for complete lesions with intact lacertus fibrosus, and 30% for partial lesions.[20]

The passive pronation test alone has 95% sensitivity and 100% specificity. This test consists of a pronation-supination movement of the forearm with an active 90° abduction of the shoulder, and the elbow flexed at 70°. The test is positive due to the inability to actively supinate the injured side (passive pronation).[21]

The bicipital gap test quantifies, in centimeters (cm), the proximal migration of the biceps muscle belly regarding the antecubital line of the affected elbow. It is a comparative assessment to the contralateral side and has 88% sensitivity and 50% specificity for injury.[22]

Resisted supination and flexion strength tests can show 40% and 30% deficits, respectively, compared with the contralateral side.[2]

Supplementary Tests

Radiography

Traditional radiographs (anteroposterior [AP] and profile) may help identify potential bone abnormalities of the bicipital tuberosity of the radius or calcifications suggesting tendinopathy (chronic inflammation). Avulsion fractures are extremely uncommon in distal biceps tendon injuries, even in traumatic cases.[23]

Ultrasound

Ultrasound presents some characteristic findings, including morphological changes (thickening, thinning, tendinous discontinuity), structural changes (hyperechogenicity, hypoechogenicity, and intrasubstantial defects), presence of fluid around the tendon, abnormal fiber elongation, abnormal tendon movement, or absence of fiber elongation during dynamic maneuvers[24,25] (►**Fig. 3a**).

Compared to magnetic resonance imaging, ultrasound has 45.5% and 66.7% accuracy in diagnosing complete and partial lesions, respectively, with 62.5% sensitivity and 20% specificity.[24]

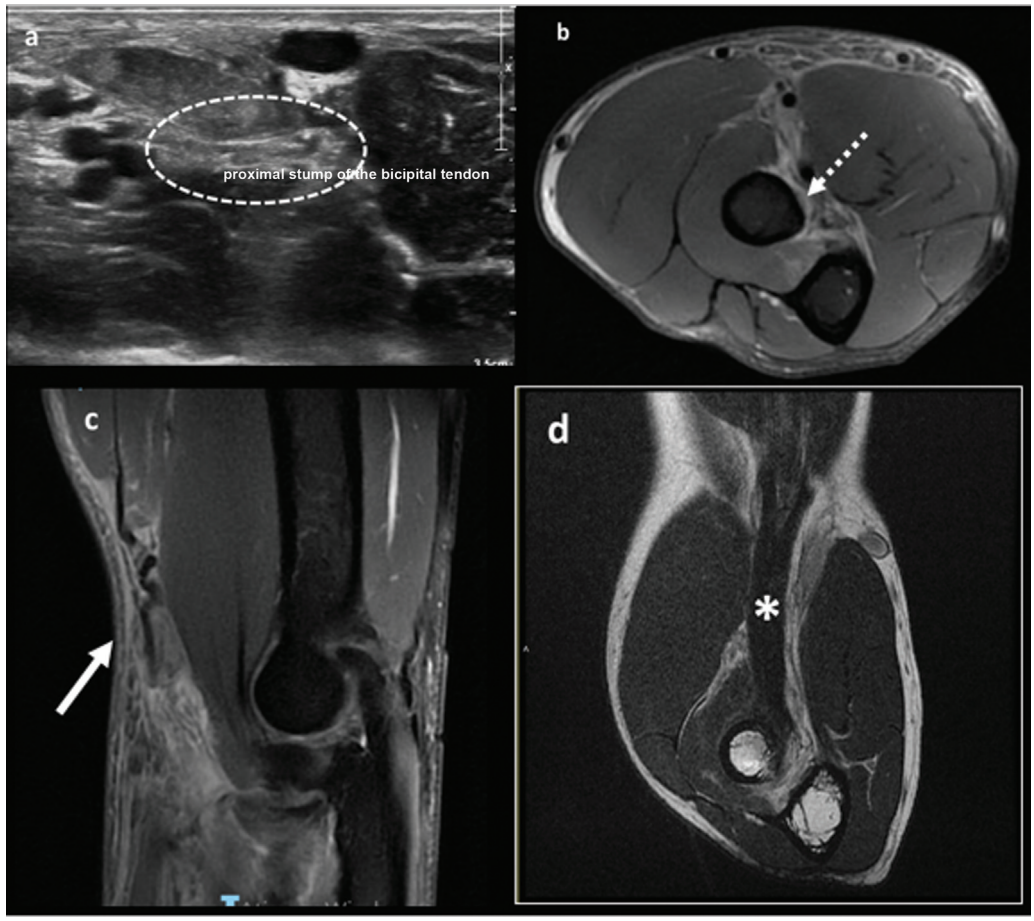

Fig. 3 Imaging assessment of the distal biceps tendon Note: a) T2-weighted sagittal magnetic resonance imaging: complete lesion of the distal biceps tendon and its proximal retraction (arrow); b) T2-weighted axial section: detachment of the biceps tendon from its "footprint" on the radial tuberosity; c) Longitudinal ultrasound section identifying the tendon injury (dotted area) and tendon retraction at the level of the humeroradial joint (asterisk); d) Magnetic Resonance Imaging in FABS view (flexion, abduction and supination) weighted in T1 demonstrating the entire length of the distal biceps tendon (from the distal myotendinous transition to its insertion in the radial tuberosity - arrow) in the post-operative reinsertion
1. proximal stump of the bicipital tendon

 © 2023. Sociedade Brasileira de Ortopedia e Traumatologia. All rights reserved.

Ultrasound has 91% accuracy and 95% sensitivity. Its specificity is 71% for complete lesions and 71.4% for partial lesions to surgical findings.[25]

Magnetic Resonance Imaging

Magnetic resonance imaging (MRI) is the gold standard in the imaging diagnosis of tendon disorders.[26]

MRI has 100% sensitivity and 82.8% specificity, with positive (PPV) and negative (NPV) predictive values of 81.44% and 100%, respectively, for complete distal bicipital tendon injuries.[26] Characteristic findings include tendon discontinuity (100%), increased signal intensity in tissues around the distal tendon of the biceps brachii (75%), and peritendinous fluid signal (74.9%)[19] (►**Fig. 3b, c**).

For partial injuries, MRI has low sensitivity (59.1%) but high PPV (100%), high specificity (100%), and 79.1% NPV.[26]

Due to the low sensitivity of MRI for partial lesions, in 2004, Giuffrèe e Moss[27]suggested the flexion-abduction-supination (FABS) positioning to optimize visualization of the entire length of the biceps brachii tendon from its attachment into the bicipital RT to the myotendinous junction, with 84% sensitivity, 86% specificity, 86% PPV, and 84% NPV[28] (►**Fig. 3d**).

The most frequent findings in partial injuries include increased intratendinous signal intensity (63.7%), peritendinous fluid signal (61.4%), increased signal intensity in the tissues surrounding the biceps brachii tendon (32 %), and RT edema (22.7%).[26]

It is possible to classify these injuries (FABS position, axial cut in T1- and T2-weighted images) per the affected percentage of the tendon close to the radial tuberosity, as proposed by Festa et al.[26]

Low-grade injuries compromise up to 25% of the tendon thickness, whereas *moderate-grade* and *high-grade* injuries affect 26% to 75% and 76% to 99% of the tendon thickness, respectively.[26] MRI (FABS) data correlation with intraoperative findings was 85% to 100% for complete lesions[17,26] and 92% for partial lesions.[29]

Non-surgical Treatment

Partial Injuries

Partial tears, particularly those involving less than 50% of the tendon diameter (low and moderate grades), are typically treated non-surgically for a minimum period of 6 months.[30] They present patterns with variable compromise of the LH and SH tendons.[31] LH tendon involvement was observed in 88.9% of non-traumatic cases, while SH tendon involvement occurred in 77.3% of traumatic cases.[32]

In cases with closed therapy failure, primary repair may be an option. Surgical repair is usually recommended for partial tears greater than 50% (high-grade injuries).[30]

Complete Injuries

Today, clinical treatment is still widely used, especially in patients over 50 years old and elderly subjects with low functional demands (due to the integrity of the brachial and supinator muscles).[23] Patients with severe restriction of the passive range of motion of the elbow and forearm, active infection, comorbidities increasing the surgical risk, and marked involvement of the soft tissue envelope are not eligible for surgical treatment.[30] Comorbidities with high rates of failure and/or risk include diabetes, grade 2 obesity (BMI $> 35\,kg/m^2$), chronic obstructive pulmonary disease (COPD), heart failure, chronic renal failure (requiring dialysis), and coagulation disorders.[33]

Treatment consists of a simple sling for 7 to 14 days, followed by re-establishment of elbow mobility and muscle strengthening as tolerated.[2] It is critical to inform patients about the outcomes of this treatment modality, which include cosmetic deformity, reduced flexion and supination strength, increased fatigability, and cramps.[2]

Surgical Treatment

Approach

Reattachment of the distal biceps tendon may use a single approach (SA, anterior) or a double approach (DA, anterior and posterior). SA requires a single skin incision, either transverse, vertical or in an S shape to RT; the approach may also use two anterior minitracks in cases with significant retraction of the tendon stump.[34]

SA requires maximum supination; in contrast, in DA, the internerve plane lies between the extensor carpi ulnaris (ECU) and the supinator under maximal pronation.[6]

Maximum supination in SA has the two following advantages: (1) it mobilizes the posterior interosseous nerve (PIN) out of the surgical site, and (2) it avoids an anterior reattachment point, which can limit the final supination force and decrease fatigue resistance.[6]

SA creates a reattachment point for the most dorsal biceps tendon in RT, maximizing the final supination strength. On the other hand, DA injures the supinator muscle, which undergoes partial fiber divulsion during tuberosity exposure, resulting in impaired supination strength.[35]

In a meta-analysis including 13 studies (2,622 patients), Castioni et al.[36] compared SA and DA and evaluated the following outcomes: final range of motion (ROM), Disabilities of the Arm, Shoulder, and Hand (DASH) score, and neurological and non-neurological complications. These authors reported that SA led to a greater final ROM for flexion and pronation, lower rates of heterotopic ossification and reoperations, and increased risk of lateral antebrachial cutaneous nerve (LACN) paresthesia, all with statistically significant differences. However, they did not observe differences in DASH scores and PIN injuries.[36]

Surgical Techniques

For SA, the forearm is in maximum supination, and the initial dissection occurs between the brachioradialis and pronator teres muscles.

The basilic vein and LACN are identified and protected. Then, the ruptured tendon is identified and freed from adhesions. The tendon stump is prepared with Krakow sutures (►**Fig. 1**) using ultra-resistant wires. Fixation consists of a cortical button (CB) and two suture anchors or an interference screw (IS) positioned

 © 2023. Sociedade Brasileira de Ortopedia e Traumatologia. All rights reserved.

as ulnar as possible in the tuberosity footprint under maximum supination to decrease the risk of PIN injury.

Saldua et al.[37] analyzed the bone tunnel position in RT using the CB technique and its relationships with the supinator muscle and PIN. These authors identified the best positioning and angle for the tunnel, whose center must lie on the tuberosity at a 30°-angle towards the ulna. Using these parameters, the distance to PIN was 16.4 mm when compared to the perpendicular tunnel (11.1 mm), with statistical significance ($p = 0.001$).[37]

SA reattachments are aligned on RT (one proximal and one distal reattachment), 1 cm apart. Two independent sutures pass through the tendon. Fixation begins at the distal anchor to establish the length, and the proximal anchor maximizes the tendon-bone contact area.[38]

Otto et al.[39] compared bioabsorbable (BIO) and metallic titanium (TEM) anchors for reattachment in 16 specimens, all with a bone mineral density similar to RT. They reported the following results: peak torque to failure, 293.53 ± 122.15 N for BIO and 280.02 ± 69.34 N for MET ($p = 0.834$), and footprint tendon spacing, 19.78 ± 2.95 N/mm for BIO and 19.30 ± 4.98 N/mm for TEM ($p = 0.834$).[39]

At the postoperative follow-up, Maciel et al.[38] reported 100% satisfaction with the aesthetic aspect of the surgery, an unchanged ROM in 95.4% of subjects, excellent Mayo Elbow Performance Scores (MEPS), return to sports (to the same pre-injury level) in all patients, and 27.2% of complications (neuropraxia and loss of ROM).[38] The mean postoperative recovery of supination and flexion strengths were 98% and 94 compared to the unaffected side, respectively.[40]

A transosseous (TO) tunnel requires a second incision (DA) between the ECU and supinator muscles with the forearm in maximum pronation for complete tuberosity exposure.[6] Next, an orifice is drilled with a burr in RT with a diameter similar to the biceps tendon stump.[6] Then, three bone holes are made to allow the passage of the four wires that will be pulled to put the tendon stump in an intraosseous position.[41] It is important to stay away from the ulna to avoid damage to the interosseous membrane, which results in heterotopic ossifications or radio-ulnar synostosis.[6]

In a case series, Miyazaki et al.[42] used the TO tunnel technique, and all patients returned to daily activities with unchanged ROM and no clinical changes in muscle strength or clinical or radiographic evidence of heterotopic ossification, radioulnar synostosis, or both.[42]

Lang et al.[43] reported functional outcomes, complication impact, and the cost-benefit ratio in patients undergoing primary repair of distal bicipital tendon ruptures using CB, TO, or SA. They concluded that the TO fixation and suture technique for total tendon rupture by an experienced surgeon using a double approach is a simple, inexpensive method with satisfactory clinical outcomes.[43]

Barret et al.[44] also concluded that the DA repair technique with immediate postoperative mobilization for acute distal bicipital tendon ruptures is safe and offers good outcomes after 2 years in active patients. The modifications introduced by Morrey to the initial procedure and early mobilization have a low rate of complications and limit the occurrence of synostosis or ossifications with sustainable outcomes.[44]

Mazzocca et al.[41] compared reattachment methods using TO tunnels, suture anchors (AS), IS, and CB in 63 cadaveric specimens. While TO and the adjustable CB showed greater tendon mobility in the footprint, of 3.55 and 3.42 mm, respectively, CB had the highest resistance to failure (440 N) compared to AS (381 N), TO (310 N), and IS (232 N).[41]

Postoperative Rehabilitation

The higher risk of tendon reattachment failure occurs in the first 2 postoperative weeks. In acute repairs, patients remain with upper limb immobilization for this period to avoid maximum elbow extension by using an orthosis with a limitation of the last 40° of extension and progressing to the final extension gain of 10° per week after the initial constraint.[6] Postoperative (PO) rehabilitation has four specific phases. Phase 1 (0 to 6 weeks) aims at achieving a complete gain in elbow ROM respecting the weekly progression of extension previously described. Phase 2 (6 to 12 weeks) maintains the mechanics of the scapulothoracic joint (scapular retraction/protraction exercises) by beginning triceps strengthening (isometric and isotonic) and wrist flexor and extensor stretching exercises. Phase 3 (12 to 16 weeks) consists of biceps isometry and mild isotonic in neutral, supinated, and prone positions, in addition to strengthening external and periscapular rotators in open and closed kinetic chains. Phase 4 (over 16 weeks) sustains and progresses the strengthening of periscapular, external rotators, biceps, and triceps muscles and marks the beginning of specific sports gestures.[45]

Functional Outcome and Return to Sports

Patients can often expect a limitation lower than 5° in extension and flexion and up to 10° loss of forearm rotation.[46–48] The average recovery of flexion and supination strength is 90% compared to the uninjured side.[49]

In a systematic review with a total of 1,270 patients (mean age, 45.38 years old) presenting 1,280 biceps brachii and followed-up for an average of 30 months (range, 6 to 84 months), Rubinger et al.[49] reported that 89% of patients (1,128) returned completely to work with no need for adaptations in a mean time of 14.37 ± 0.52 weeks.[49] Return to high-performance sports is initially encouraging but followed by a progressive deterioration in subsequent years.[50]

Pagani et al.[50] studied 25 professional athletes from the United States National Football League (NFL), reporting that 84% of subjects returned to the sport, all in the following season (mean time to return, 321 ± 45 days). After biceps brachii reattachment, sports-related survival was 76% in 1 year and 56% after 2 years.[50]

Athletes undergoing surgical treatment had a significantly shorter post-injury career and played fewer games per season than their counterparts matched for age and position

 © 2023. Sociedade Brasileira de Ortopedia e Traumatologia. All rights reserved.

Table 2 Complications from distal biceps tendon reattachment

	Amarasooriya et al.[52]	*Ford et al.*[53]	*Dunphy et al.*[54]
Number of patients (n)	3.091	970	784
Major complications (total)	**4.60%**	**7.50%**	**8.16%**
PIN injury	1.60%	1.90%	1.30%
Tendon re-rupture	1.40%	1.50%	1.80%
Radioulnar synostosis	0.10%	1%	Not informed
Minor complications	**20.40%**	**21.50%**	**25.20%**
LCNF injury	9.20%	13%	21%
SRN injury	2.40%	4.90%	4.20%

PIN, Posterior interosseous nerve; LCNF, lateral cutaneous nerve of the forearm; SRN, superficial radial nerve.
Most prevalent complications in patients undergoing surgical treatment for tendon reinsertion.

($p = 0.001$). There was no significant difference in performance scores per position.[50]

In 61 athletes, the return rate to Olympic weightlifting was 93.4% (regardless of the sport level). However, only 65.6% returned to pre-injury level after an average time off of 6 ± 2.8 months. Reattachment using SA and surgery on the dominant side were associated with a lower likelihood of returning to the sport at the same level.[51]

Complications

►**Table 2** shows the comparative assessment of the three published systematic reviews (Amarasooriya et al.[52], Ford et al.,[53] and Dunphy et al.[54]) with the higher number of patients between 2010 and 2020 regarding major and minor complications after distal biceps tendon reattachment.

Surgical timing plays a significant role in complications.[53–55] Several authors, including Cain et al.[55], Bisson et al.,[56] and Kelly et al.,[57] reported case series with complication rates in early treatment (up to 2 weeks) between 20 and 30% and up to 41% after this period.[56–59]

To avoid complications, bone debris removal, wound washing, and hemostasis may decrease the rate of heterotopic ossification. Careful use of retractors, avoiding their blind placement, i.e., posterior to the radius, may reduce the incidence of PIN paralysis, especially in the SA technique.[58]

Re-ruptures are rare, occurring at a 1 to 2% rate.[53–57] A higher re-rupture rate, of 5%, was reported in patients treated with fixation using SA.[45]

Limitations

Studies on distal biceps injuries tendon mostly focus on access routes, surgical techniques, and complications. Outcomes are given by functional scores, mainly MEPS, which do not necessarily reproduce the reality of the population affected by this lesion (adults aged 35 to 54 years old). Moreover, the follow-up time is insufficient. Further research requires assessments, functional and strength tests, and isokinetic dynamometry. The time to return to sports is long, approximately 1 year, and, in professional athletes, the durability of the post-injury career is 56% in the 2 years after surgical treatment.

Final Comments

Rupture of the distal tendon of the biceps brachii is an infrequent injury. It mostly occurs in middle-aged men involved in heavy work or sports. Early surgical repair yields the best outcomes with decreased incidence of complications and consistent functional recovery.

Financial Support
This study received no financial support from public, commercial, or not-for-profit sources.

Conflict of Interests
The authors declare no conflict of interests.

References

1 Safran MR, Graham SM. Distal biceps tendon ruptures: incidence, demographics, and the effect of smoking. Clin Orthop Relat Res 2002;(404):275–283
2 Freeman CR, McCormick KR, Mahoney D, Baratz M, Lubahn JD. Nonoperative treatment of distal biceps tendon ruptures compared with a historical control group. J Bone Joint Surg Am 2009; 91(10):2329–2334
3 Devereaux MW, ElMaraghy AW. Improving the rapid and reliable diagnosis of complete distal biceps tendon rupture: a nuanced approach to the clinical examination. Am J Sports Med 2013;41 (09):1998–2004
4 Idler CS, Montgomery WH III, Lindsey DP, Badua PA, Wynne GF, Yerby SA. Distal biceps tendon repair: a biomechanical comparison of intact tendon and 2 repair techniques. Am J Sports Med 2006;34(06):968–974
5 Júnior JC, de Castro Filho CD, de Castro Mello TF, de Vasconcelos RA, Zabeu JL, Garcia JP. Isokinetic and functional evaluation of distal bíceps reconstruction using the Mayo mini-double route technique. Rev Bras Ortop 2015;47(05):581–587
6 Srinivasan RC, Pederson WC, Morrey BF. Distal Biceps Tendon Repair and Reconstruction. J Hand Surg Am 2020;45(01): 48–56
7 Eames MH, Bain GI, Fogg QA, van Riet RP. Distal biceps tendon anatomy: a cadaveric study. J Bone Joint Surg Am 2007;89(05): 1044–1049
8 Bhatia DN, Kandhari V, DasGupta B. Cadaveric Study of Insertional Anatomy of Distal Biceps Tendon and its Relationship to the Dynamic Proximal Radioulnar Space. J Hand Surg Am 2017;42 (01):e15–e23

 © 2023. Sociedade Brasileira de Ortopedia e Traumatologia. All rights reserved.

9 Athwal GS, Steinmann SP, Rispoli DM. The distal biceps tendon: footprint and relevant clinical anatomy. J Hand Surg Am 2007;32(08):1225–1229
10 Pacha Vicente D, Forcada Calvet P, Carrera Burgaya A, Llusá Pérez M. Innervation of biceps brachii and brachialis: Anatomical and surgical approach. Clin Anat 2005;18(03):186–194
11 Kelly MP, Perkinson SG, Ablove RH, Tueting JL. Distal Biceps Tendon Ruptures: An Epidemiological Analysis Using a Large Population Database. Am J Sports Med 2015;43(08):2012–2017
12 Seiler JG III, Parker LM, Chamberland PD, Sherbourne GM, Carpenter WA. The distal biceps tendon. Two potential mechanisms involved in its rupture: arterial supply and mechanical impingement. J Shoulder Elbow Surg 1995;4(03):149–156
13 Pagonis T, Givissis P, Ditsios K, Pagonis A, Petsatodis G, Christodoulou A. The effect of steroid-abuse on anatomic reinsertion of ruptured distal biceps brachii tendon. Injury 2011;42(11):1307–1312
14 Green JB, Skaife TL, Leslie BM. Bilateral distal biceps tendon ruptures. J Hand Surg Am 2012;37(01):120–123
15 Storti TM, Paniago AF, Faria RS. Simultaneous bilateral distal biceps tendon repair: case report. Rev Bras Ortop 2016;52(01):107–110
16 Jockel CR, Mulieri PJ, Belsky MR, Leslie BM. Distal biceps tendon tears in women. J Shoulder Elbow Surg 2010;19(05):645–650
17 Kannus P, Józsa L. Histopathological changes preceding spontaneous rupture of a tendon. A controlled study of 891 patients. J Bone Joint Surg Am 1991;73(10):1507–1525
18 O'Driscoll SW, Goncalves LB, Dietz P. The hook test for distal biceps tendon avulsion. Am J Sports Med 2007;35(11):1865–1869
19 Pallante GD, O'Driscoll SW. Return of an intact hook test result: clinical assessment of biceps tendon integrity after surgical repair. Orthop J Sports Med 2019;7(02):2325967119827311
20 Luokkala T, Siddharthan SK, Karjalainen TV, Watts AC. Distal biceps hook test - Sensitivity in acute and chronic tears and ability to predict the need for graft reconstruction. Shoulder Elbow 2020;12(04):294–298
21 Harding WG III. A new clinical test for avulsion of the insertion of the biceps tendon. Orthopedics 2005;28(01):27–29
22 ElMaraghy A, Devereaux M, Tsoi K. The biceps crease interval for diagnosing complete distal biceps tendon ruptures. Clin Orthop Relat Res 2008;466(09):2255–2262
23 Giacalone F, Dutto E, Ferrero M, Bertolini M, Sard A, Pontini I. Treatment of distal biceps tendon rupture: why, when, how? Analysis of literature and our experience. Musculoskelet Surg 2015;99(Suppl 1):S67–S73
24 Lynch J, Yu CC, Chen C, Muh S. Magnetic resonance imaging versus ultrasound in diagnosis of distal biceps tendon avulsion. Orthop Traumatol Surg Res 2019;105(05):861–866
25 Tagliafico A, Michaud J, Perez MM, Martinoli C. Ultrasound of distal brachialis tendon attachment: normal and abnormal findings. Br J Radiol 2013;86(1025):20130004
26 Festa A, Mulieri PJ, Newman JS, Spitz DJ, Leslie BM. Effectiveness of magnetic resonance imaging in detecting partial and complete distal biceps tendon rupture. J Hand Surg Am 2010;35(01):77–83
27 Giuffrè BM, Moss MJ. Optimal positioning for MRI of the distal biceps brachii tendon: flexed abducted supinated view. AJR Am J Roentgenol 2004;182(04):944–946
28 Schenkels E, Caekebeke P, Swinnen L, Peeters J, van Riet R. Is the flexion-abduction-supination magnetic resonance imaging view more accurate than standard magnetic resonance imaging in detecting distal biceps pathology? J Shoulder Elbow Surg 2020;29(12):2654–2660
29 Fitzgerald SW, Curry DR, Erickson SJ, Quinn SF, Friedman H. Distal biceps tendon injury: MR imaging diagnosis. Radiology 1994;191(01):203–206
30 Frazier MS, Boardman MJ, Westland M, Imbriglia JE. Surgical treatment of partial distal biceps tendon ruptures. J Hand Surg Am 2010;35(07):1111–1114
31 García Rodríguez C, García-Polín López C, Del Olmo Hernández T, Moros Marco S, Jacobo Edo O, Ávila Lafuente JL. Distal biceps tendon rupture: diagnostic strength of ultrasonography and magnetic resonance. Rev Esp Cir Ortop Traumatol (Engl Ed) 2020;64(02):77–82
32 Nicolay RW, Lawton CD, Selley RS, et al. Partial rupture of the distal biceps brachii tendon: a magnetic resonance imaging analysis. J Shoulder Elbow Surg 2020;29(09):1859–1868
33 Goedderz C, Plantz MA, Gerlach EB, et al. Determining the incidence and risk factors for short-term complications following distal biceps tendon repair. Clin Shoulder Elbow 2022;25(01):36–41
34 Pascarelli L, Righi LC, Bongiovanni RR, Imoto RS, Teodoro RL, Ferro HF. Technique and results after distal braquial biceps tendon reparation, through two anterior mini-incisions. Acta Ortop Bras 2013;21(02):76–79
35 Tanner C, Johnson T, Muradov P, Husak L. Single incision power optimizing cost-effective (SPOC) distal biceps repair. J Shoulder Elbow Surg 2013;22(03):305–311
36 Castioni D, Mercurio M, Fanelli D, Cosentino O, Gasparini G, Galasso O. Single- versus double-incision technique for the treatment of distal biceps tendon rupture. Bone Joint J 2020;102-B(12):1608–1617
37 Saldua N, Carney J, Dewing C, Thompson M. The effect of drilling angle on posterior interosseous nerve safety during open and endoscopic anterior single-incision repair of the distal biceps tendon. Arthroscopy 2008;24(03):305–310
38 Maciel RA, Costa PS, Figueiredo EA, Belangero PS, Pochini AC, Ejnisman B. Acute distal biceps ruptures: single incision repair by use of suture anchors. Rev Bras Ortop 2017;52(02):148–153
39 Otto A, Mehl J, Obopilwe E, et al. Biomechanical comparison of onlay distal biceps tendon repair: All-suture anchors versus titanium suture anchors. Am J Sports Med 2019;47(10):2478–2483
40 de Mattos CA, Maia D, Castro R, Etchebehere M. Reinsertion of distal brachial biceps tendon rupture through single incision using anchors. Rev Bras Ortop 2020;55(02):191–197
41 Mazzocca AD, Burton KJ, Romeo AA, Santangelo S, Adams DA, Arciero RA. Biomechanical evaluation of 4 techniques of distal biceps brachii tendon repair. Am J Sports Med 2007;35(02):252–258
42 Miyazaki AN, Fregoneze M, Santos PD, et al. Functional evaluation of patients with injury of the distal insertion of the biceps brachii muscle treated surgically. Rev Bras Ortop 2014;49(02):129–133
43 Lang NW, Bukaty A, Sturz GD, Platzer P, Joestl J. Treatment of primary total distal biceps tendon rupture using cortical button, transosseus fixation and suture anchor: A single center experience. Orthop Traumatol Surg Res 2018;104(06):859–863
44 Barret H, Winter M, Gastaud O, Saliken DJ, Gauci MO, Bronsard N. Double incision repair technique with immediate mobilization for acute distal biceps tendon ruptures provides good results after 2 years in active patients. Orthop Traumatol Surg Res 2019;105(02):323–328
45 Logan CA, Shahien A, Haber D, Foster Z, Farrington A, Provencher MT. Rehabilitation following distal bíceps repair. Int J Sports Phys Ther 2019;14(02):308–317
46 McKee MD, Hirji R, Schemitsch EH, Wild LM, Waddell JP. Patient-oriented functional outcome after repair of distal biceps tendon ruptures using a single-incision technique. J Shoulder Elbow Surg 2005;14(03):302–306
47 Morrey BF, Askew LJ, An KN, Dobyns JH. Rupture of the distal tendon of the biceps brachii. A biomechanical study. J Bone Joint Surg Am 1985;67(03):418–421

 © 2023. Sociedade Brasileira de Ortopedia e Traumatologia. All rights reserved.

48 Siebenlist S, Fischer SC, Sandmann GH, et al. The functional outcome of forty-nine single-incision suture anchor repairs for distal biceps tendon ruptures at the elbow. Int Orthop 2014;38 (04):873–879
49 Rubinger L, Solow M, Johal H, Al-Asiri J. Return to work following a distal biceps repair: a systematic review of the literature. J Shoulder Elbow Surg 2020;29(05):1002–1009
50 Pagani NR, Leibman MI, Guss MS. Return to play and performance after surgical repair of distal biceps tendon ruptures in National Football League athletes. J Shoulder Elbow Surg 2021;30(02): 346–351
51 Gowd AK, Liu JN, Maheshwer B, et al. Return to sport and weightlifting analysis following distal biceps tendon repair. J Shoulder Elbow Surg 2021;30(09):2097–2104
52 Amarasooriya M, Bain GI, Roper T, Bryant K, Iqbal K, Phadnis J. Complications after distal biceps tendon repair: A systematic review. Am J Sports Med 2020;48(12):3103–3111
53 Ford SE, Andersen JS, Macknet DM, Connor PM, Loeffler BJ, Gaston RG. Major complications after distal biceps tendon repairs: retrospective cohort analysis of 970 cases. J Shoulder Elbow Surg 2018; 27(10):1898–1906
54 Dunphy TR, Hudson J, Batech M, Acevedo DC, Mirzayan R. Surgical treatment of distal biceps tendon ruptures: An analysis of complications in 784 surgical repairs. Am J Sports Med 2017;45(13): 3020–3029
55 Cain RA, Nydick JA, Stein MI, Williams BD, Polikandriotis JA, Hess AV. Complications following distal biceps repair. J Hand Surg Am 2012;37(10):2112–2117
56 Bisson L, Moyer M, Lanighan K, Marzo J. Complications associated with repair of a distal biceps rupture using the modified two-incision technique. J Shoulder Elbow Surg 2008;17(01): 67S–71S
57 Kelly EW, Morrey BF, O'Driscoll SW. Complications of repair of the distal biceps tendon with the modified two-incision technique. J Bone Joint Surg Am 2000;82(11):1575–1581
58 Vandenberghe M, van Riet R. Distal biceps ruptures: open and endoscopic techniques. Curr Rev Musculoskelet Med 2016;9(02): 215–223
59 Alencar JB, Bernardes DF, Souza CJD, Girão MAS, Rocha PHMD, Façanha FAM. Clinical result of patients with distal biceps tendo rupture with endobutton. Acta Ortop Bras 2021;29 (03):149–152

 © 2023. Sociedade Brasileira de Ortopedia e Traumatologia. All rights reserved.