Article published online: 2021-03-31

Shoulder Arthroplasty for the Treatment of Proximal Humeral Fractures: Current Concepts*

Artroplastia do ombro no tratamento das fraturas da extremidade proximal do úmero: Conceitos atuais

Geraldo da Rocha Motta Filho[1] Marcus Vinícius Galvão Amaral[1]

[1] Shoulder and Elbow Surgery Center, Instituto Nacional de Traumatologia e Ortopedia (INTO), Rio de Janeiro, RJ, Brazil

Rev Bras Ortop 2022;57(4):529–539.

Address for correspondence Geraldo da Rocha Motta Filho, MD, MSc, Rua Raimundo de Magalhães, 92, Gávea, Rio de Janeiro, RJ, 22451-150, Brazil (e-mail: geraldomotta@terra.com.br).

Abstract

Complex proximal humeral fractures, especially in elderly patients, often require arthroplastic surgical treatment. Traditionally, shoulder hemiarthroplasty (HA) is the method of choice, resulting in long implant survival and a painless shoulder; however, shoulder HA has heterogeneous clinical outcomes related to the correct position of the implant, both in terms of height and version, and the anatomical consolidation of tuberosities. Today, reverse shoulder arthroplasties are increasingly used to treat such fractures. These techniques result in better functional outcomes compared to HAs, especially regarding anterior flexion, but implant longevity has not been established. The development of specific prosthetic humeral components for the treatment of fractures, which were recently introduced in the clinical practice, led to better clinical outcomes.

Keywords
- arthroplasty
- shoulder
- fractures, bone

Resumo

Fraturas complexas da extremidade proximal do úmero, especialmente em idosos, frequentemente necessitam de tratamento cirúrgico artroplástico. Tradicionalmente, a hemiartroplastia (HA) do ombro é o método de escolha, com longa sobrevida do implante, e oferece um ombro indolor, mas com resultados clínicos heterogêneos, relacionados ao correto posicionamento do implante quanto à altura e à versão, além da consolidação anatômica dos tubérculos. Atualmente, a utilização de artroplastias reversas do ombro para o tratamento dessas fraturas vêm aumentando exponencialmente, com melhores resultados funcionais do que as HAs, principalmente quanto à flexão anterior, apesar de a longevidade do implante ainda não ter sido estabelecida. O desenvolvimento de componentes umerais protéticos específicos para o tratamento de fraturas, introduzidos na prática clínica nos últimos anos, levou a resultados clínicos melhores.

Palavras-chave
- artroplastia
- ombro
- fraturas ósseas

* *Work developed at the Shoulder and Elbow Surgery Center, Instituto Nacional de Traumatologia e Ortopedia (INTO), Rio de Janeiro, RJ, Brazil.*

received
August 24, 2020
accepted
September 16, 2020
published online
March 31, 2021

DOI https://doi.org/10.1055/s-0040-1721359.
ISSN 0102-3616.

© 2021. Sociedade Brasileira de Ortopedia e Traumatologia. All rights reserved.
This is an open access article published by Thieme under the terms of the Creative Commons Attribution-NonDerivative-NonCommercial-License, permitting copying and reproduction so long as the original work is given appropriate credit. Contents may not be used for commercial purposes, or adapted, remixed, transformed or built upon. (https://creativecommons.org/licenses/by-nc-nd/4.0/)
Thieme Revinter Publicações Ltda., Rua do Matoso 170, Rio de Janeiro, RJ, CEP 20270-135, Brazil

Introduction

Proximal humeral fractures account for up to 10% of all fractures in the elderly population.[1] Most of these fractures can be treated in a closed manner with satisfactory outcomes. On the other hand, complex fractures, such as those in three and four parts according to the Neer classification,[2] fracture-dislocations, fractures of the humeral head, and deviated fractures with multiple fragments and metaphyseal bone loss, often require surgical treatment (►**Fig. 1A-B**).[2]

Traditionally, hemiarthroplasty (HA) is indicated for fractures in which anatomical reduction is impossible and that present a high risk of failure of the internal fixation.[1,3,4]

Hemiarthroplasty is technically challenging, especially regarding humeral length and proper version of the humeral head.[5] One of the factors determining the quality of the clinical outcome is the anatomical reconstruction of the proximal humerus and the repair and consolidation of the greater and lesser tuberosities.[6,7]

The development of new techniques for tuberosity fixation and specific humeral components for the arthroplastic treatment improved the clinical outcomes. These low-profile humeral components, with reduced proximal metallic thickness, medialized off-set and holes to pass the suture through the stem neck, favor the anatomical positioning of the greater tuberosity, the placement of the bone graft, and the suture[8] (►**Fig. 2**).

Over the years, HA outcomes have not been clinically consistent.[7–10] The introduction of reverse shoulder arthroplasty (RSA) to treat degenerative conditions of the shoulder, with exciting outcomes, stimulated the specialists to expand its use for the treatment of complex proximal humeral fractures.[11,12]

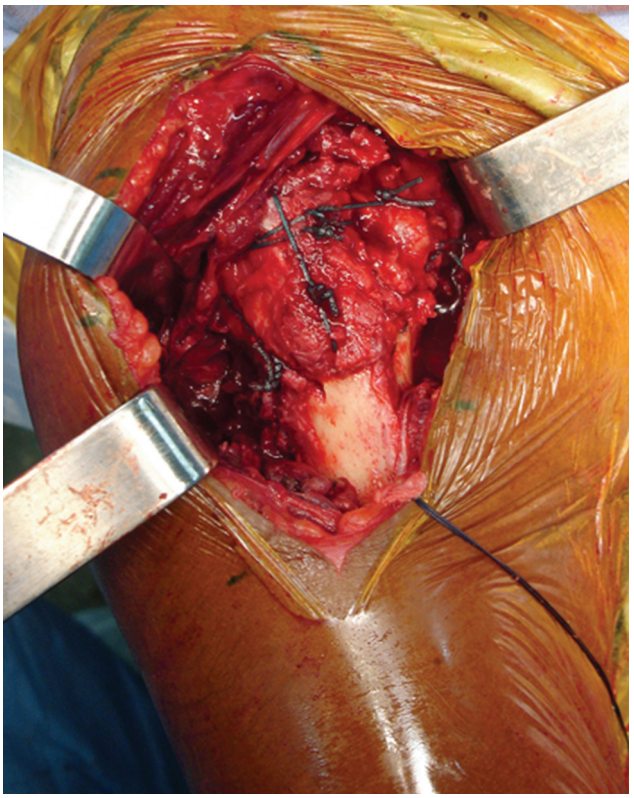

Fig. 2 Perioperative image of wires at the greater and lesser tuberosities associated to hemiarthroplasty.

The evaluation of outcomes from 69,120 fractures treated from 2008 to 2016 at the Korean Health Insurance Review and Assessment Service[13] showed a significant increase in the surgical treatment of proximal humeral fractures, rising from 24.6% in 2008 to 36.8% in 2016. In total, 85.6% of these

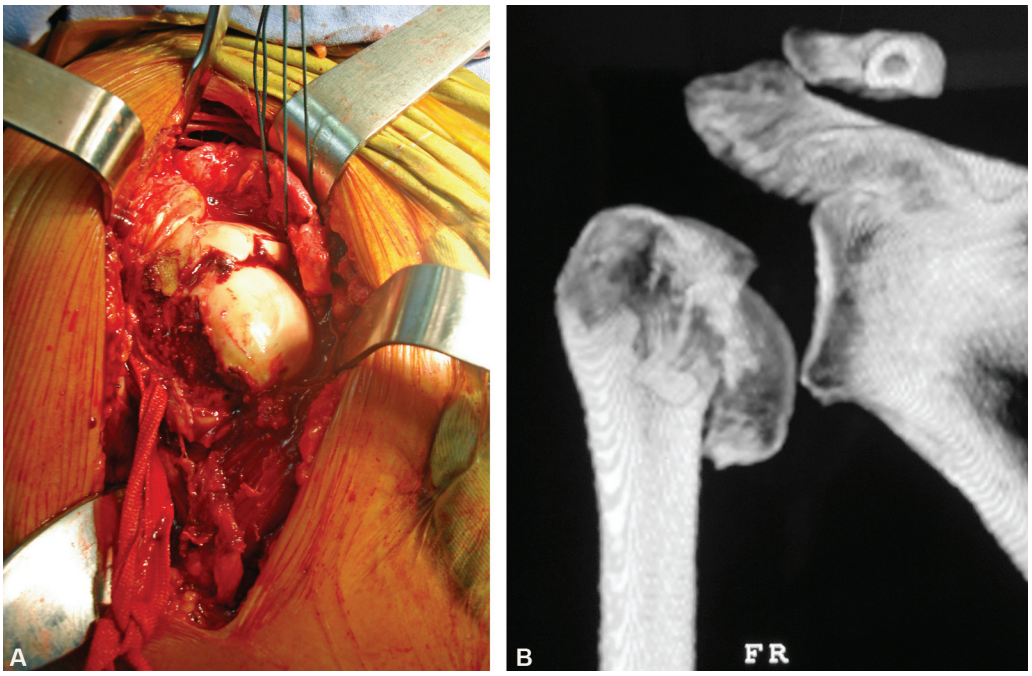

Fig. 1 (**A**) Perioperative image of a head split. (**B**) Three-dimensional computed tomography scan of a head split.

 © 2021. Sociedade Brasileira de Ortopedia e Traumatologia. All rights reserved.

fractures were treated with surgical reduction and internal fixation. In this series, the indication for arthroplasty to treat these fractures varied slightly, from 8.6% in 2008 to 9.9% in 2016. However, despite the small variation in the total number of arthroplasties performed in this group of patients, the performance of RSAs increased significantly, from 8.2% in 2008 to 52% in 2016, mainly among the population older than 80 years of age.[13]

The present paper aims to review the current literature on HA and RSA to treat displaced proximal humeral fractures when surgical reduction and internal fixation are not feasible.

Criteria for hemiarthroplasty and reverse arthroplasty indication and contraindication

Since the initial reports by Neer in the 1970s,[14] the prosthetic replacement of the proximal humerus for the treatment of complex fractures was well accepted.[7–10] However, over the years, and with the introduction of more specific clinical assessment scores, the functional outcomes have often proved unpredictable, inconsistent and inferior compared to those obtained in patients with degenerative and inflammatory conditions undergoing total shoulder arthroplasty (TSA).[15]

Proximal humerus HA is classically indicated for elderly subjects with low to moderate functional demand, or patients around the sixth decade of life who are not candidates for open reduction and internal fixation (ORIF) of the fracture and preferentially present low fragmentation of the greater tuberosity.[7–10] Nowadays, the treatment of fractures can use specific humeral components that favor the consolidation of the tuberosity and enable a future conversion to an RSA with no need to replace components.[7,8,16] Despite the unfavorable outcomes from past arthroplasty constructions, Paul Grammont, in the 1980s, redesigned this shoulder prosthesis model. Since the biomechanical modifications improved the clinical outcomes and reduced the number of complications, this prosthesis model gained popularity.[17,18]

Today, RSAs supplanted HAs for the treatment of fractures because more consistent clinical outcomes are expected. Subjects older than 70 years of age with 3- or 4-part displaced fractures constitute this potential group of patients.[12]

An RSA requires preserved structure and function of the deltoid. However, deltoid hypotrophy is not a contraindication for the performance of an RSA, as long as muscle innervation is spared.[18] In contrast, complete palsy of the axillary nerve is a classic contraindication due to the high risk of instability and limited potential for functional improvement.[17,18] Adequate glenoid bone structure and stock, enabling a secure fixation of the components, is critical for the procedure. In cases of erosion or loss of bone mass, the decision must be based on three-dimensional computed tomography images. Absolute contraindications include active infection, neuroarthropathy and severe glenoid bone loss. Patients with severe osteopenia, such as chronic steroid users, have relative contraindications.[17,18]

Even though HA is used in the treatment of fractures, its success is questionable.[7–10] The HA outcomes for the treatment of fractures are often not predictable, with a high rate of tuberosity-related complications.[7–10] Recent studies have shown better results for RSAs compared to HAs in the treatment of deviated proximal humeral fractures in the elderly population.[19–30] This difference occurs because the functional outcomes of HAs for the treatment of fractures are directly related to the anatomical consolidation of the tuberosities.[7–10] The performance of RSA for the treatment of fractures results in more homogeneous functional outcomes, even in the absence of consolidation or with vicious tuberosity consolidation.[11,12,31–35]

In fractures with more than three weeks of evolution and humeral fracture sequelae, in which HAs present poor outcomes due to the need for dissection and more aggressive tuberosity mobilization that negatively influence the consolidation.[21,36,37] Thus, RSA is an alternative for elderly patients who present unsatisfactory outcomes after the initial non-surgical treatment.[36,37]

Outcome analysis and literature review

The functional outcomes associated with shoulder HA for the treatment of fractures are inconsistent.[7–10] This inconsistency is due to complex, reconstruction-related technical factors, to the time in which the surgery is performed, to populational features, and to the heterogeneity of clinical evaluation scores.[7–10] Nevertheless, the rates of pain relief range from 73% to 97%, whereas subjective patient satisfaction varies from 70% to 92%.[7–10]

Accurate positioning of the HA in a complex humeral fracture, reproducing humeral height and version, enables anatomical reduction and rigid fixation of the tuberosities, which are essential for a satisfactory clinical outcome.[5,7,8]

The published case series[7,10,15] evaluating this procedure demonstrate that the functional outcomes are directly correlated with the anatomical consolidation of the tuberosities.

At the vertical plane, the head-to-tuberosity distance (HTD), an objective measure of the height of the greater tuberosity in relation to the articular surface of the humeral head of the prosthesis, has prognostic value in the assessment of the correct position of the greater tuberosity. The average HTD is 8 mm, with a variation of $\pm$ 3 mm. Distances greater than 15 mm suggest a high risk of complications and poor functional outcomes.[7,15] At the horizontal plane, the posterior positioning of the greater tuberosity must be avoided due to the increased risk of fixation failure, resulting in limited mobility.[8] (►**Fig. 3A-B**).

In 2013, a systematic review[30] of HA outcomes, using a fracture-specific stem compared to RSA for the treatment of proximal humeral fractures, was published, and it presented a summary of the best evidence available in the literature at the time. Fourteen papers met the inclusion criteria for this systematic review. Efforts were made to determine the demographic criteria associated with each arthroplasty technique, as well as their subjective, objective, and radiographic outcomes.[30] The HA was performed mainly in male, younger subjects with four-part fractures. In older patients, with a

 © 2021. Sociedade Brasileira de Ortopedia e Traumatologia. All rights reserved.

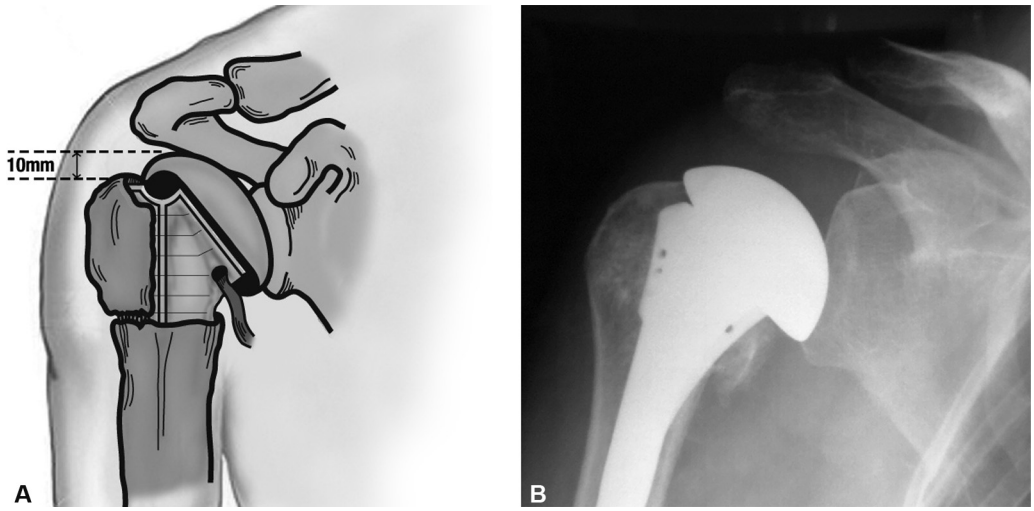

Fig. 3 (**A**) Schematic representation showing the head-to-tubercle distance (HTD), an objective measure of the height of the greater tuberosity in relation to the articular surface of the humeral head of the prosthesis; its average value is 8 mm. (**B**) Radiographic image showing an HTD within normal limits.

higher incidence of associated rotator-cuff tears, RSA was indicated.[30] The functional outcomes of HAs and RSAs were similar regarding both Constant-Murley and American Shoulder and Elbow Surgeons (ASES) scores, as well as physical examination parameters. The incidence of complications and reoperations was also assessed. Clinical complications were four times more frequent with RSAs, which is a major issue. Radiographic changes were observed in 90% of RSAs, and in 27% of HAs, although part of these changes, mainly lower scapular impingement (notching) and heterotopic ossification, have debatable clinical repercussions. On the other hand, the percentage of reoperations did not differ significantly between both groups.[30]

In 2014, Sebastiá-Forcada et al.[19] published a randomized, controlled analysis comparing HA and RSA. The RSAs showed higher values on the following scores: Constant-Murley, Disabilities of the Arm, Shoulder and Hand (DASH), and University of California Los Angeles Shoulder Score (UCLA), in addition to improved anterior flexion and abduction. There were no differences regarding lateral rotation. Tuberosity fixation was performed using the same technique in both groups and consolidation occurred more frequently in the group submitted to RSAs. Based on these parameters, these authors suggested that RSA was a better option.

In two similar meta-analysis, Shukla et al.[20] and Wang et al.[21] compared HA and RSA to treat proximal humeral fractures. The authors concluded that the available literature suggests that RSA results in more favorable clinical outcomes compared to HA, with a lower percentage of complications, higher ASES scores, greater tuberosity consolidation, and better mobility regarding anterior flexion.

A retrospective study from the Société Française de Chirurgie Orthopédique et Traumatologique (SOFCOT)[22] comparing HA and RSA in proximal humeral fractures, with an average follow-up of 39 months, demonstrated that subjects submitted to RSA presented a higher adjusted Constant-Murley score. On the other hand, there were no significant differences in the absolute Constant-Murley, DASH and Subjective Shoulder Value (SSV) scores. The RSA group presented superior anterior flexion, while lateral rotation was better in the the HA group. However, there were no differences regarding medial rotation. The complications were more frequent in the HA group. The percentage of radiographic consolidation of the greater tuberosity was the same in both groups, occurring in 70% of the cases. Inferior scapular impingement, that is, notching, was observed in 23% of the patients submitted to RSA.

Gallinet et al.[23] performed a systematic literature review on behalf of SOFCOT. They identified studies comparing HA and RSA for the treatment of proximal humeral fractures in patients older than 65 years of age who were operated on between 2006 and 2016. They found 67 studies, and 22 were selected for their level of evidence. The RSA resulted in better active anterior flexion and abduction, as well as a higher Constant-Murley score. On the other hand, the lateral and medial rotations were lower in subjects treated with RSA. The fixation and consolidation of the tuberosities around the RSA were related to the rotational ability. In cases with no tuberosity consolidation, the functional outcomes were satisfactory for RSA, but not HA, due to the marked functional deficit in this latter group of patients. For RSA, age did not influence tuberosity consolidation, in contrast to HA. Complications were more frequent in the RSA group, although the reoperation rate was the same for both techniques. The incidence of revisions, which required implant replacement, was lower in the RSA group.[23]

In 2016, Chen et al.[24] carried out a network meta-analysis (NMA), which is a novel technique to define medical evidence by comparing relative benefits associated with multiple interventions, thus establishing the interventional hierarchy of a number of treatment options. These authors evaluated the effectiveness and safety of ORIF, RSA, HA, intramedullary (IM) fixation, and closed treatment in displaced proximal humeral fractures. Using this methodology, 34 studies, involving 2,165

 © 2021. Sociedade Brasileira de Ortopedia e Traumatologia. All rights reserved.

patients, were included. The RSA group had the highest Constant-Murley score and the lowest percentage of complications when compared to the ORIF, HA and IM fixation groups. In addition, the RSA group had a lower incidence of additional surgeries than the ORIF and IM fixation groups. They concluded that RSA had the highest probability of improving the functional outcomes and reducing the incidence of complications and the need for additional surgery.[24]

In 2017, Du et al.[25] identified 7 randomized studies during a query in 3 electronic databases, totaling 347 elderly patients treated for 3- or 4-part proximal humeral fractures. The patients were treated using the closed technique, ORIF, HA and RSA. The RSA group presented the best Constant-Murley score and the lowest number of reoperations. On the other hand, the ORIF had the worst effectiveness in these elderly patients. The best Constant-Murley scores were obtained by the patients submmited to RSA, followed by HA, closed technique, and ORIF. Regarding reoperations, the best treatment was RSA, followed by the closed technique, HA and ORIF[23] (►**Table 1**).

Factors that impact outcomes

Dedicated humeral stems are the implants of choice for HA or RSA for the treatment of fractures.[5,6,13,14,36,37]

Stems with more suitable designs for the reduction and fixation of the tuberosities favor consolidation because these components present lower proximal profiles, presence of holes in the stem for passage of resistant sutures, and space to place bone grafts in an adequate volume to provide a biological stimulus to healing[7,8,15,16,38,39] (►**Fig. 4A-B**).

Despite all technological developments, HA still results in heterogeneous functional outcomes and complications related to tuberosity consolidation[7,8,40] (►**Figs. 5** and **6**).

The RSA is becoming the implant of choice for the surgical treatment of these injuries probably due to the technical challenges imposed by HA. It is worthy discussing whether, even in RSA, the use of specific implant designs to treat complex proximal humeral fractures is required, or whether the common implant designs used to treat other conditions are sufficient.

In RSA, the use of humeral components with low proximal profiles, medialized stem epiphysis, smooth, polished medial stem neck area, and hydroxyapatite at the lateral metaphysis seems to favor the reduction and stabilization of the tuberosities and an increase in the rate of consolidation, influencing the postoperative rotational mobility.[4,37] The position of the polyethylene inlay in relation to the stem apparently contributes to a greater integration of the tuberosity.[38,39]

In addition, some implant designs enable the lateralization or medialization of the center of rotation of the shoulder joint during RSA. Comparative studies suggest that the lateralization of the center of rotation of the joint and a smaller cervical-diaphyseal angle improve the function of the muscles that rotate the shoulder externally, improving the clinical outcomes regarding lateral rotation mobility in RSA.[38] In contrast, in 2018, Verdano et al.[39] performed a retrospective assessment of clinical and radiographic outcomes to compare lateralized reverse prostheses on the humeral side with the Grammont medialized model in the treatment of displaced proximal humeral fractures. The

Table 1 Clinical data from the studies comparing RSA and HA

Author (year)	Sample	Constant-Murley score	AF	Abd	LR	MR	Greater tuberosity consolidation
Cuff and Pupello [26] (2013)	27 RSA 26 HA	NI	139° RSA 100° HA	NI	24° RSA 25° HA	NI	RSA 83% HA 37% ($p = 0.17$)
Namdari et al.[30] (2013)	210 RSA 231 HA	50..3 RSA (41.1–70..9) 56 HA (38.7–61.9)	114° RSA (97°–137°) 117° HA (96°–133°)	92° RSA (66°–119°) 111° HA (70°–151°)	20° RSA (3°–37°) 34° HA (21°–47°)	NI	NI
Mata-Fink et al.[27] (2013)	377 RSA 504 HA	54.7 RSA 48.6 HA	113° RSA 92° HA	NI	20° RSA 22° HA	L3 RSA T12 HA	NI
Sebastiá-Forcada et al.[19] (2014)	31 RSA 31 HA	56.1 RSA (24–80) 40 HA (8–74)	120° RSA (40°–180°) 80° HA (20°–180°)	113° RSA (50°–170°) 79° HA (30°–150°)	30° RSA (0°–10°) 26° HA (0°–10°)	Sacral RSA Sacral HA	RSA 64.5% HA 56.7% ($p =$ NI)
Baudi et al.[28] (2014)	25 RSA 28 HA	56.2 RSA 42.3 HA	131° RSA 89° HA	128° RSA 82° HA	15° RSA 23° HA	NI	RSA 84% HA 37% ($p < 0.05$)
Ferrel et al.[29] (2015)	322 RSA 1.024 HA	54.6 RSA 58 HA	118° RSA 108° HA	98° RSA 94° HA	20° RSA 30° HA	NI	RSA 82.8% HA 73.9%
Bonnevialle et al.[22] (2016)	41 RSA 57 HA	57 RSA (23–90) 54 HA (19–89)	130° RSA (50°–180°) 112° HA (20°–180°)	NI	23° RSA (-20°–70°) 28° HA (0°–80°)	Sacral RSA L3 HA	RSA 73% HA 72% ($p = 0.95$)

Abbreviations: Abd, abduction; AF, anterior flexion; HA, hemiarthroplasty; LR, lateral rotation; MR, medial rotation; NI, not informed; RSA, reverse shoulder arthroplasty.

 © 2021. Sociedade Brasileira de Ortopedia e Traumatologia. All rights reserved.

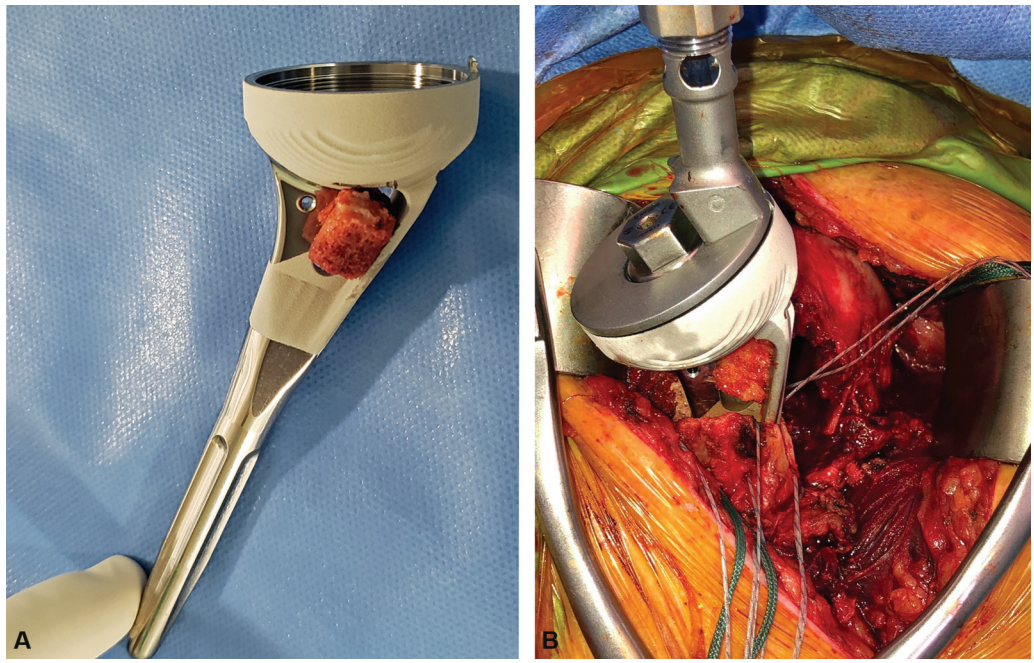

Fig. 4 (**A**) Image of a fracture stem with bone graft in the proper orifice. (**B**) Perioperative image of a fracture-specific stem.

Constant-Murley score and lateral and medial rotation ranges were similar, while anterior flexion and consolidation of the greater tuberosity were higher in patients receiving a medialized prosthesis. However, this study[39] did not use any type of humeral component with a specific design for the treatment of fractures. This work, with the limitations of such a type of review, does not clearly establish which implant must be used.[39–41]

Reverse arthroplasty for the treatment of fractures is traditionally performed with cemented humeral components. The literature suggests that cementless humeral components in RSA for the treatment of fractures show inferior outcomes in subjective scores, although there is no correlation with pain, mobility, and tuberosity consolidation.[42]

A key point for RSA is the preparation and placement of the glenoid component, even in proximal humeral fractures.

Fig. 5 Postoperative radiographic image of a hemiarthroplasty with avulsion of the greater tuberosity.

Fig. 6 Postoperative radiographic image of a hemiarthroplasty with avulsion of the lesser tuberosity.

 © 2021. Sociedade Brasileira de Ortopedia e Traumatologia. All rights reserved.

However, few studies address this topic. There are reports regarding loosening of the metal base (0.52% to 3.5%) and the high incidence of scapular impingement (43.6%) related to inadequate positioning and incorrect version of the glenosphere. The factors preventing scapular impingement include inclination and inferior positioning of the glenoid component, cervical-diaphyseal angle lower than 155°, and lateralized implants. Therefore, in addition to implant selection, understanding the morphology of the glenoid is important.[39]

Regarding the moment when patients should be operated, the literature reports good results from the use of ARO both for the treatment of acute displaced fractures as for fractures treated late.[36,37]

It is worth mentioning what the literature defines as "late". After 20 days, the mobilization and fixation of the tuberosities are compromised by bone consolidation and reabsorption.[43] In the personal opinion of the authors of the present study, the treatment of the sequelae of proximal humeral fractures implies a more complex, extensive dissection, and surgeons must be prepared to deal with the compromised bone stock that may exist depending on the characteristics of the injury. In addition, greater blood loss is expected, with its potential results, as well as higher percentages of neurological complications, instability, and infection.

Dezfuli et al.[43] evaluated 49 patients who underwent RSA to treat proximal humerus fractures. They stratified the patients according to acute and chronic fractures operated for different reasons. The group of acute fractures showed better outcomes compared to all other groups. In cases of late fractures or fracture sequelae, including mal union and pseudoarthrosis, the RSA outcomes, although lower compared to those of the RSAs performed in cases of acute fractures, were superior to RSAs performed to review poor outcomes in fractures submitted to other primary techniques, such as HA or osteosynthesis.

Seidl et al.[37] compared patients who underwent reverse arthroplasty to treat acute fractures occurred within four weeks with patients previously submitted to another type of treatment. The authors concluded that, although all the subjects may present satisfactory outcomes, the acute patients presented superior tuberosity consolidation and improved external rotation.

In 2019, Torchia et al.[36] performed a meta-analysis including 16 studies and 322 subjects to determine which patients should be operated on during the acute or late phase. Of these, 4 were comparative studies and 12 were case series. In the first group, consisting of comparative studies, there were no differences in anterior flexion, clinical scores, or reoperation rates. Among the patients treated later, lateral rotation increased 6º, which was statistically significant. The authors concluded that, facing the risk associated with surgery in the elderly population, the closed treatment must be considered, reserving the RSA for patients with therapeutic failure.[36]

Boileau et al.[34] hypothesized that fixation and consolidation of the greater tuberosity would result in better clinical outcomes in patients undergoing RSA for the treatment of proximal humeral fractures. Patients with fractures and an average age of 80.4 years underwent RSA using a fracture-specific stem, which enables the placement of a bone graft removed from the humeral head and the suture of the tuberosities around it. Healing of the fractures occurred in 84% of the patients, with 4 cases of resorption and 2 cases of non-union and migration. These 6 patients had an SSV score of 65% compared to 83% in subjects with consolidation of the tuberosities. Regarding range of motion, the anterior flexion was of 115°, compared to 141°, while the lateral rotation wasof 11°, compared to 27° respectively. Despite the higher age of the patients, the authors concluded that reconstruction and consolidation of the tuberosities provided better clinical outcomes, as well as better anterior flexion and lateral rotation.[34] It is worth noting the small number of patients to support this conclusion.

The experience of the SOFCOT shows that the fixation and consolidation of the tuberosities around the RSA corroborate the expectation of improved rotation.[35]

In 2018, Torrens et al.[33] carried out a retrospective study with 41 consecutive subjects to assess the influence of the consolidation of the greater tuberosity on the functional outcomes after an RSA for the treatment of proximal humeral fractures. Consolidation occurred in 68% of the cases. In this study, the functional scores, range of motion and scapular impingement were similar regardless of the consolidation status. Although expected, this case series showed no improvement in shoulder functional outcomes[33] (►**Figs. 7** and **8A-C**).

We can conclude that the literature is controversial regarding the influence of the consolidation of the tuberosities by RSA on the clinical outcomes and range of motion, especially in lateral and medial rotation and essential daily activities (►**Fig. 9A-B**).[32–34]

It is worth mentioning some differences between the RSA and HA for the treatment of proximal humeral fractures regarding the consolidation of the tuberosities. For RSA, the functional outcomes can be satisfactory even when the consolidation does not occur, unlike HA, in which there is a marked functional deficit.[32–34]

Shoulder arthroplasty is not associated with extensive bleeding, but all measures must be taken to minimize blood loss. Tranexamic acid (TXA), an antifibrinolytic agent, has the potential of reducing blood loss and the need for blood transfusion after hip and knee arthroplasties.[44]

Several studies tried to evaluate the effectiveness and safety of TXA. Gillespie et al.[44] carried out a randomized trial with 111 patients divided into 2 groups. The group treated with 2 g of TXA topically applied at the surgical wound presented lower blood loss and a lower reduction in the level of serum hemoglobin compared to the placebo group.

Kirsch et al.[45] and Sun et al.[46] performed meta-analyses regarding the administration of TXA in RSAs, and found a significant reduction in the alteration of hemoglobin, suggesting a reduced need for transfusion.

In summary, the literature clearly suggests the administration of of TXA in RSAs.

 © 2021. Sociedade Brasileira de Ortopedia e Traumatologia. All rights reserved.

Fig. 7 Radiographic image illustrating the consolidation of the greater tuberosity with proximal migration associated with an RSA.

Complications

The overall average for RSA complications in acute fractures is 25%, with 17.4% and 7.6% classified as minor and major complications respectively.[47,48]

Lopiz et al.[49] performed a retrospective evaluation of 42 patients undergoing RSA to treat proximal humeral fractures. The subjects were divided into 2 groups, one consisting of patients younger than 80 years of age (<80), and the other with patients with 80 years old or older (=80). The average follow-up period was of 32.6 months. The Constant-Murley score, adjusted for gender and age, was of 64 for the <80 group and of 33 for the =80 group. Regarding the range of motion, the <80 and = 80 groups presented, respectively, 126° and 110° of anterior flexion, 117° and 105° of abduction, 22° and 20° of lateral rotation, and medial rotation at L3 and the sacrum. There were 9.5% of prosthesis- and procedure-related complications in both groups. The authors concluded that age is a critical factor for the success of the RSA.[49]

Noguera et al.[47] evaluated the complications associated with RSAs for the treatment of proximal humeral fractures in 103 patients older than 65 years of age, with a mean age of 77.3 years. In total, there were 25% of complications, including 17.4% simple and 7.6% complex intercurrences. The correlation between severe complications and the American Society of Anesthesiologists (ASA) score was statistically significant. Complications occurred within an approximate period of 90 days. There was also a trend towards simple complications within the first week, associated with a high ASA score. Rheumatoid disease was significantly associated with severe complications. The rate of transfusion was of 11.5%. This study concluded that the average rate of severe complications in patients undergoing RSA for the treatment of fractures was low in the elderly population.[47]

In a systematic review and meta-analysis, Austin et al.[50] suggested that RSA improved the range of motion, the clinical follow-up scores, and the rate of reoperations for all causes when compared to HA; in addition, there was no difference in the rate of infection associated with both techniques. The authors concluded that RSA for the treatment of acute proximal humeral fractures in the elderly population may result in better outcomes both in the short- and medium-terms when compared to HA. Finally, they suggest that long-term assessments are required to define whether these RSA benefits will persist.[50]

Costs

The significant increase in the complexity of the cenario of health systems worldwide requires a rationalization of costs and expenditures[51] The economic viability of incorporating high-cost technologies depends on the interpretation of the clinical outcomes in the context of cost compensation.[51] The increased performance of RSAs to treat proximal humeral fractures makes this issue extremely relevant, mainly because this procedure is associated with longer hospitalizations, a higher incidence of complications, and higher costs when compared to RSA for the treatment of rotator-cuff arthropathy.[52] Relevant studies must consider the

Fig. 8 Range of motion of the patient shown in Figure 7. The range of motion was achieved despite the radiographic aspect. (**A**) anterior flexion; (**B**) lateral rotation; (**C**) medial rotation.

 © 2021. Sociedade Brasileira de Ortopedia e Traumatologia. All rights reserved.

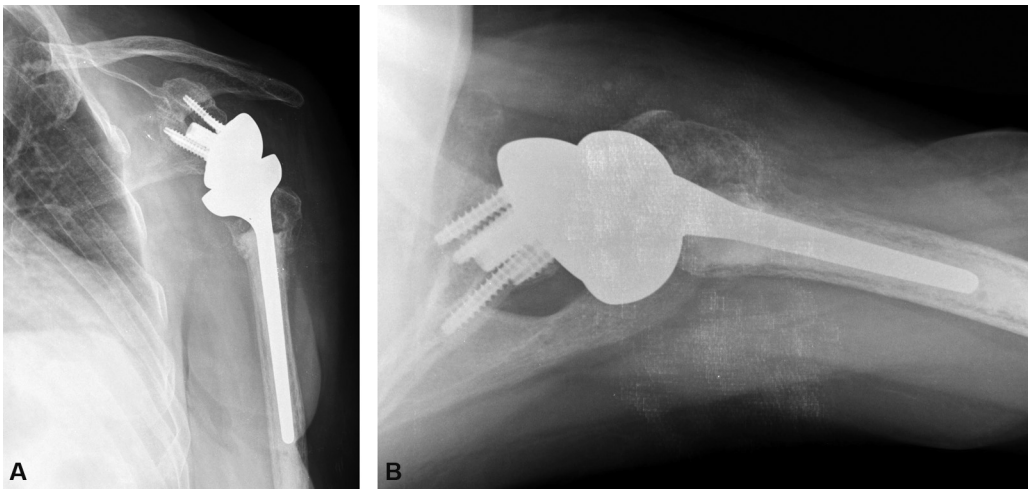

Fig. 9 (**A**) Radiographic image, anteroposterior view, of RSA with consolidation of the greater tuberosity, but not resembling the normal anatomy. (**B**) Axillary image.

relationship between total hospital costs, including the length of hospital stay, the surgical time, the rate of blood transfusions, the clinical and surgical complications, and the cost of the implant, and compare them to the functional clinical outcomes.[52–54]

Liu et al.[52] demonstrated that RSAs have higher costs compared to HAs, but with no difference in length of hospital stay, use of blood products, and final range of motion, despite improved pain and functional scores.[52] The authors suggested that a better investigation regarding the costs of postoperative rehabilitation, special nursing care and the rate of surgical revision are required for the best interpretation of the cost-benefit ratio of this type of treatment.[52]

Some financial analyses suggest that RSA for the treatment of proximal humeral fractures in elderly patients is the preferred strategy when compared to HA.[53,54] Cost calculations demonstrate that the increased cost of RSA to treat these fractures is well below the standard payment thresholds for technologies that improve the quality of life, and its cost-benefit ratio is similar to that of other surgical therapies that are widely successful in orthopedics, such as total hip arthroplasties for osteoarthritis.[53]

Final Considerations

Due to the heterogeneous HA outcomes, which are directly related to the quality of the reduction and consolidation of the tuberosities, RSA has been increasingly used, resulting in more homogeneous functional outcomes and similar complication rates.

There are doubts regarding the selection of appropriate patients for HA or RSA mainly because all meta-analyzes are limited by the heterogeneity of the studies.

Conflict of Interests

The authors have no conflict of interests to declare.

References

1 Kim SH, Szabo RM, Marder RA. Epidemiology of humerus fractures in the United States: nationwide emergency department sample, 2008. Arthritis Care Res (Hoboken) 2012;64(03):407–414
2 Neer CS II. Displaced proximal humeral fractures. I. Classification and evaluation. J Bone Joint Surg Am 1970;52(06):1077–1089
3 Maier D, Jaeger M, Izadpanah K, Strohm PC, Suedkamp NP. Proximal humeral fracture treatment in adults. J Bone Joint Surg Am 2014;96(03):251–261
4 Checchia SL, Doneux PS, Miyazaki AN, et al. Tratamento das fraturas do terço proximal do úmero com a prótese parcial Eccentra®. Rev Bras Ortop 2005;40(03):130–140
5 Murachovsky J, Ikemoto RY, Nascimento LG, Fujiki EN, Milani C, Warner JJ. Pectoralis major tendon reference (PMT): a new method for accurate restoration of humeral length with hemiarthroplasty for fracture. J Shoulder Elbow Surg 2006;15(06): 675–678
6 Brandão BL, Amaral MV, Cohen M, et al. Osteossíntese das fraturas da extremidade proximal do úmero com sistema de placa de ângulo fixo com parafusos bloqueados: técnica e resultados. Rev Bras Ortop 2009;44(02):106–111
7 Boileau P, Winter M, Cikes A, et al. Can surgeons predict what makes a good hemiarthroplasty for fracture? J Shoulder Elbow Surg 2013;22(11):1495–1506
8 Cadet ER, Ahmad CS. Hemiarthroplasty for three- and four-part proximal humerus fractures. J Am Acad Orthop Surg 2012;20(01): 17–27
9 Robinson CM, Page RS, Hill RM, Sanders DL, Court-Brown CM, Wakefield AE. Primary hemiarthroplasty for treatment of proximal humeral fractures. J Bone Joint Surg Am 2003;85(07): 1215–1223
10 Mighell MA, Kolm GP, Collinge CA, Frankle MA. Outcomes of hemiarthroplasty for fractures of the proximal humerus. J Shoulder Elbow Surg 2003;12(06):569–577
11 Bufquin T, Hersan A, Hubert L, Massin P. Reverse shoulder arthroplasty for the treatment of three- and four-part fractures of the proximal humerus in the elderly: a prospective review of 43 cases with a short-term follow-up. J Bone Joint Surg Br 2007;89 (04):516–520
12 Dillon MT, Prentice HA, Burfeind WE, Chan PH, Navarro RA. The increasing role of reverse total shoulder arthroplasty in the treatment of proximal humerus fractures. Injury 2019;50(03): 676–680

 © 2021. Sociedade Brasileira de Ortopedia e Traumatologia. All rights reserved.

13 Jo YH, Lee KH, Lee BG. Surgical trends in elderly patients with proximal humeral fractures in South Korea: a population-based study. BMC Musculoskelet Disord 2019;20(01):136
14 Neer CS II. Displaced proximal humeral fractures. II. Treatment of three-part and four-part displacement. J Bone Joint Surg Am 1970;52(06):1090–1103
15 Boileau P, Sinnerton RJ, Chuinard C, Walch G. Arthroplasty of the shoulder. J Bone Joint Surg Br 2006;88(05):562–575
16 Garofalo R, Flanagin B, Castagna A, Lo EY, Krishnan SG. Reverse shoulder arthroplasty for proximal humerus fracture using a dedicated stem: radiological outcomes at a minimum 2 years of follow-up-case series. J Orthop Surg Res 2015;10:129
17 Boileau P, Watkinson DJ, Hatzidakis AM, Balg F. Grammont reverse prosthesis: design, rationale, and biomechanics. J Shoulder Elbow Surg 2005;14(1, Suppl S)147S–161S
18 Gerber C, Pennington SD, Nyffeler RW. Reverse total shoulder arthroplasty. J Am Acad Orthop Surg 2009;17(05):284–295
19 Sebastiá-Forcada E, Cebrián-Gómez R, Lizaur-Utrilla A, Gil-Guillén V. Reverse shoulder arthroplasty versus hemiarthroplasty for acute proximal humeral fractures. A blinded, randomized, controlled, prospective study. J Shoulder Elbow Surg 2014;23 (10):1419–1426
20 Shukla DR, McAnany S, Kim J, Overley S, Parsons BO. Hemiarthroplasty versus reverse shoulder arthroplasty for treatment of proximal humeral fractures: a meta-analysis. J Shoulder Elbow Surg 2016;25(02):330–340
21 Wang J, Zhu Y, Zhang F, Chen W, Tian Y, Zhang Y. Meta-analysis suggests that reverse shoulder arthroplasty in proximal humerus fractures is a better option than hemiarthroplasty in the elderly. Int Orthop 2016;40(03):531–539
22 Bonnevialle N, Tournier C, Clavert P, Ohl X, Sirveaux F, Saragaglia Dla Société française de chirurgie orthopédique et traumatologique. Hemiarthroplasty versus reverse shoulder arthroplasty in 4-part displaced fractures of the proximal humerus: Multicenter retrospective study. Orthop Traumatol Surg Res 2016;102(05): 569–573
23 Gallinet D, Ohl X, Decroocq L, Dib C, Valenti P, Boileau PFrench Society for Orthopaedic Surgery (SOFCOT). Is reverse total shoulder arthroplasty more effective than hemiarthroplasty for treating displaced proximal humerus fractures in older adults? A systematic review and meta-analysis. Orthop Traumatol Surg Res 2018;104(06):759–766
24 Chen L, Xing F, Xiang Z. Effectiveness and safety of interventions for treating adults with displaced proximal humeral fracture: A network meta-analysis and systematic review. PLoS One 2016;11 (11):e0166801
25 Du S, Ye J, Chen H, Li X, Lin Q. Interventions for Treating 3- or 4-part proximal humeral fractures in elderly patient: A network meta-analysis of randomized controlled trials. Int J Surg 2017; 48:240–246
26 Cuff DJ, Pupello DR. Comparison of hemiarthroplasty and reverse shoulder arthroplasty for the treatment of proximal humeral fractures in elderly patients. J Bone Joint Surg Am 2013;95(22): 2050–2055
27 Mata-Fink A, Meinke M, Jones C, Kim B, Bell JE. Reverse shoulder arthroplasty for treatment of proximal humeral fractures in older adults: a systematic review. J Shoulder Elbow Surg 2013;22(12): 1737–1748
28 Baudi P, Campochiaro G, Serafini F, et al. Hemiarthroplasty versus reverse shoulder arthroplasty: comparative study of functional and radiological outcomes in the treatment of acute proximal humerus fracture. Musculoskelet Surg 2014;98 (Suppl 1):19–25
29 Ferrel JR, Trinh TQ, Fischer RA. Reverse total shoulder arthroplasty versus hemiarthroplasty for proximal humeral fractures: a systematic review. J Orthop Trauma 2015;29(01):60–68
30 Namdari S, Horneff JG, Baldwin K. Comparison of hemiarthroplasty and reverse arthroplasty for treatment of proximal humeral fractures: a systematic review. J Bone Joint Surg Am 2013;95 (18):1701–1708
31 Simovitch RW, Roche CP, Jones RB, et al. Effect of Tuberosity Healing on Clinical Outcomes in Elderly Patients Treated With a Reverse Shoulder Arthroplasty for 3- and 4-Part Proximal Humerus Fractures. J Orthop Trauma 2019;33(02):e39–e45
32 Chun YM, Kim DS, Lee DH, Shin SJ. Reverse shoulder arthroplasty for four-part proximal humerus fracture in elderly patients: can a healed tuberosity improve the functional outcomes? J Shoulder Elbow Surg 2017;26(07):1216–1221
33 Torrens C, Alentorn-Geli E, Mingo F, Gamba C, Santana F. Reverse shoulder arthroplasty for the treatment of acute complex proximal humeral fractures: Influence of greater tuberosity healing on the functional outcomes. J Orthop Surg (Hong Kong) 2018;26(01): 2309499018760132
34 Boileau P, Alta TD, Decroocq L, et al. Reverse shoulder arthroplasty for acute fractures in the elderly: is it worth reattaching the tuberosities? J Shoulder Elbow Surg 2019;28(03):437–444
35 Ohl X, Bonnevialle N, Gallinet D, et al. SOFCOT. How the greater tuberosity affects clinical outcomes after reverse shoulder arthroplasty for proximal humeral fractures. J Shoulder Elbow Surg 2018;27(12):2139–2144
36 Torchia MT, Austin DC, Cozzolino N, Jacobowitz L, Bell JE. Acute versus delayed reverse total shoulder arthroplasty for the treatment of proximal humeral fractures in the elderly population: a systematic review and meta-analysis. J Shoulder Elbow Surg 2019;28(04):765–773
37 Seidl A, Sholder D, Warrender W, et al. Early Versus Late Reverse Shoulder Arthroplasty for Proximal Humerus Fractures: Does It Matter? Arch Bone Jt Surg 2017;5(04):213–220
38 Hamilton MA, Diep P, Roche C, et al. Effect of reverse shoulder design philosophy on muscle moment arms. J Orthop Res 2015;33 (04):605–613
39 Verdano MA, Aliani D, Galavotti C, Maroun C, Vaienti E, Ceccarelli F. Grammont versus lateralizing reverse shoulder arthroplasty for proximal humerus fracture: functional and radiographic outcomes. Musculoskelet Surg 2018;102(Suppl 1):57–65
40 Sirveaux F, Roche O, Molé D. Shoulder arthroplasty for acute proximal humerus fracture. Orthop Traumatol Surg Res 2010;96 (06):683–694
41 Barros LH, Figueiredo S, Marques M, Rodrigues C, Ramos J, Claro R. Tuberosity Healing after Reverse Shoulder Arthroplasty for Proximal Humerus Fractures: Is there Clinical Improvement? [Published online: 2020-02-07]. Rev Bras Ortop. Available from: https://www.thieme-connect.de/products/ejournals/pdf/10.1055/s-0039-3402459
42 Schoch B, Aibinder W, Walters J, et al. Outcomes of Uncemented Versus Cemented Reverse Shoulder Arthroplasty for Proximal Humerus Fractures. Orthopedics 2019;42(02):e236–e241
43 Dezfuli B, King JJ, Farmer KW, Struk AM, Wright TW. Outcomes of reverse total shoulder arthroplasty as primary versus revision procedure for proximal humerus fractures. J Shoulder Elbow Surg 2016;25(07):1133–1137
44 Gillespie R, Shishani Y, Joseph S, Streit JJ, Gobezie R. Neer Award 2015: A randomized, prospective evaluation on the effectiveness of tranexamic acid in reducing blood loss after total shoulder arthroplasty. J Shoulder Elbow Surg 2015;24(11):1679–1684
45 Kirsch JM, Bedi A, Horner N, et al. Tranexamic Acid in Shoulder Arthroplasty: A Systematic Review and Meta-Analysis. JBJS Rev 2017;5(09):e3
46 Sun CX, Zhang L, Mi LD, Du GY, Sun XG, He SW. Efficiency and safety of tranexamic acid in reducing blood loss in total shoulder arthroplasty: A systematic review and meta-analysis. Medicine (Baltimore) 2017;96(22):e7015
47 Noguera L, Trigo L, Melero V, Santana F, Torrens C. Reverse shoulder arthroplasty for acute proximal humeral fractures: Postoperative complications at 7 days, 90 days and 1 year. Injury 2019;50(02):371–375

 © 2021. Sociedade Brasileira de Ortopedia e Traumatologia. All rights reserved.

48 Koh J, Galvin JW, Sing DC, Curry EJ, Li X. Thirty-day Complications and Readmission Rates in Elderly Patients After Shoulder Arthroplasty. J Am Acad Orthop Surg Glob Res Rev 2018;2(11):e068
49 Lopiz Y, García-Coiradas J, Serrano-Mateo L, García-Fernández C, Marco F. Reverse shoulder arthroplasty for acute proximal humeral fractures in the geriatric patient: results, health-related quality of life and complication rates. Int Orthop 2016;40(04):771–781
50 Austin DC, Torchia MT, Cozzolino NH, Jacobowitz LE, Bell JE. Decreased Reoperations and Improved Outcomes With Reverse Total Shoulder Arthroplasty in Comparison to Hemiarthroplasty for Geriatric Proximal Humerus Fractures: A Systematic Review and Meta-Analysis. J Orthop Trauma 2019;33(01):49–57
51 Manoli A, Capriccioso CE, Konda SR, Egol KA. Total shoulder arthroplasty for proximal humerus fracture is associated with increased hospital charges despite a shorter length of stay. Orthop Traumatol Surg Res 2016;102(01):19–24
52 Liu JN, Agarwalla A, Gowd AK, et al. Reverse shoulder arthroplasty for proximal humerus fracture: a more complex episode of care than for cuff tear arthropathy. J Shoulder Elbow Surg 2019;28(11):2139–2146
53 Osterhoff G, O'Hara NN, D'Cruz J, et al. A Cost-Effectiveness analysis of reverse total shoulder arthroplasty versus hemiarthroplasty for the management of complex proximal humeral fractures in the elderly. Value Health 2017;20(03):404–411
54 Solomon JA, Joseph SM, Shishani Y, et al. Cost Analysis of Hemiarthroplasty Versus Reverse Shoulder Arthroplasty for Fractures. Orthopedics 2016;39(04):230–234

 © 2021. Sociedade Brasileira de Ortopedia e Traumatologia. All rights reserved.