REV BRAS ORTOP. 2018;53(1):15–21

SOCIEDADE BRASILEIRA DE ORTOPEDIA E TRAUMATOLOGIA

RBO REVISTA BRASILEIRA DE ORTOPEDIA

www.rbo.org.br

Original Article

Axillary nerve neurotization by a triceps motor branch: comparison between axillary and posterior arm approaches☆

Daniel Tôrres Jácome, Fernando Henrique Uchôa de Alencar, Marcos Vinícius Vieira de Lemos, Rudolf Nunes Kobig, João Francisco Recalde Rocha*

Instituto Nacional de Traumatologia e Ortopedia (Into), Rio de Janeiro, RJ, Brazil

ARTICLE INFO

Article history:
Received 18 October 2016
Accepted 22 November 2016
Available online 12 December 2017

Keywords:
Brachial plexus
Axillary nerve
Nerve transfer
Neurotization
Shoulder

ABSTRACT

Objectives: This study is aimed at comparing the functional outcome of axillary nerve neurotization by a triceps motor branch through the axillary approach and posterior arm approach.
Methods: The study included 27 patients with post-traumatic brachial plexus injury treated with axillary nerve neurotization by a triceps motor branch for functional recovery of shoulder abduction and external rotation. The patients were retrospectively evaluated and two groups were identified, one with 13 patients undergoing axillary nerve neurotization by an axillary approach and the second with 14 patients using the posterior arm approach. Patients underwent assessment of muscle strength using the scale recommended by the British Medical Research Council, preoperatively and 18 months postoperatively, with useful function recovery considered as grade M3 or greater.
Results: In the axillary approach group, 76.9% of patients achieved useful abduction function recovery and 69.2% achieved useful external rotation function recovery. In the group with posterior arm approach, 71.4% of patients achieved useful abduction function recovery and 50% achieved useful external rotation function recovery. The difference between the two groups was not statistically significant ($p = 1.000$ for the British Medical Research Council abduction scale and $p = 0.440$ for external rotation).
Conclusion: According to the British Medical Research Council grading, axillary nerve neurotization with a triceps motor branch using axillary approach or posterior arm approach shows no statistical differences.

© 2016 Sociedade Brasileira de Ortopedia e Traumatologia. Published by Elsevier Editora Ltda. This is an open access article under the CC BY-NC-ND license (http://creativecommons.org/licenses/by-nc-nd/4.0/).

☆ Study conducted at the Instituto Nacional de Traumatologia e Ortopedia, Rio de Janeiro, RJ, Brazil.

* *Corresponding author.*
E-mail: daniel_jacome@hotmail.com (D.T. Jácome).

https://doi.org/10.1016/j.rboe.2017.12.002

2255-4971/© 2016 Sociedade Brasileira de Ortopedia e Traumatologia. Published by Elsevier Editora Ltda. This is an open access article under the CC BY-NC-ND license (http://creativecommons.org/licenses/by-nc-nd/4.0/).

Neurotização do nervo axilar por um ramo do tríceps: comparação entre acesso axilar e posterior

Palavras-chave:
Plexo braquial
Nervo axilar
Transferência nervosa
Neurotização
Ombro

R E S U M O

Objetivos: Comparar o resultado funcional da neurotização do nervo axilar por um ramo motor do tríceps através do acesso axilar e do acesso posterior.
Métodos: Foram incluídos no estudo 27 pacientes com lesão pós-traumática de plexo braquial submetidos à neurotização do nervo axilar por um ramo motor do tríceps para recuperação funcional do ombro de 2010 a 2014. Os pacientes foram avaliados e dois grupos foram identificados, um com 13 pacientes submetidos a neurotização do nervo axilar por um acesso axilar e o segundo com 14 pacientes nos quais foi usada a via de acesso posterior. Os pacientes foram submetidos a avaliação da força muscular com a escala preconizada pelo *British Medical Research Council* no pré-operatório e com 18 meses de pós-operatório, foi considerada força motora efetiva graduação M3 ou maior.
Resultados: No grupo que fez o acesso axilar, 76,9% dos pacientes obtiveram força motora efetiva de abdução e 69,2% de rotação externa. Já no grupo com acesso posterior, 71,4% dos pacientes conseguiram força motora efetiva de abdução e 50% de rotação externa. A diferença entre os dois grupos não foi estatisticamente significante ($p = 1{,}000$ para escala British Medical Research Council de abdução e $p = 0{,}440$ para rotação externa).
Conclusão: Na avaliação da graduação de força na escala British Medical Research Council, o uso do acesso axilar para neurotização de um ramo motor do tríceps para o nervo axilar não apresenta diferenças estatísticas em relação ao uso do acesso posterior.

© 2016 Sociedade Brasileira de Ortopedia e Traumatologia. Publicado por Elsevier Editora Ltda. Este é um artigo Open Access sob uma licença CC BY-NC-ND (http://creativecommons.org/licenses/by-nc-nd/4.0/).

Introduction

In traumatic lesions of the upper trunk of the brachial plexus, paralysis of the muscles innervated by the suprascapular, axillary, and musculocutaneous nerves results in loss of shoulder and elbow function.[1,2] Shoulder stabilization, which restores abduction and external rotation, is essential as it directly influences the more distal functions of the upper limb.[3] To achieve this goal, several techniques have been used. Primary repair or nerve grafting usually results in poor function recovery. In recent decades, nerve transfer has become an option with great potential for improving the results.[4–6]

To recover shoulder function in brachial plexus lesions, the most important targets to be reanimated are the supraspinatus and infraspinatus complex by neurotization of the suprascapular nerve, and the deltoid and teres minor, by neurotization of the axillary nerve. The neurotization of the suprascapular nerve has already been well-established in the literature with the use of the accessory nerve as a donor providing good results.[7–9]

Several nerves have already been used as donors for transfer to the axillary nerve. However, unlike other options, the triceps motor branch function is synergistic to shoulder abduction and external rotation, which facilitates postoperative re-education of the deltoid and teres minor. Moreover, the triceps motor branch can be used without the need for nerve graft interposition, and its use does not cause a deficit in triceps function.[10,11]

Different access routes have already been used for axillary nerve neurotization by one of the triceps motor branches; however, they all have limitations.[12] This study is aimed at evaluating the functional outcome of axillary nerve neurotization by triceps motor branch through two approaches: posterior arm and axillary.

Materials and methods

Study population

The study reviewed the medical records of patients with post-traumatic brachial plexus lesions who underwent neurotization of a motor branch of the triceps to the axillary nerve, associated with suprascapular nerve neurotization through the accessory nerve for functional shoulder recovery, between 2010 and 2014. All patients underwent the surgical procedure at the Instituto Nacional de Traumatologia e Ortopedia; all procedures were performed by the Reconstructive Microsurgery team. The initial diagnosis was made through serial physical examinations and electroneuromyography tests; the diagnosis was confirmed intraoperatively. The inclusion criteria for the present study were: (1) Post-traumatic brachial plexus lesion, (2) C5 and C6 root lesion, (3) postoperative follow-up of at least 18 months, and (4) age between 15 and 50 years. Patients who were operated on over one year after the injury and those who underwent secondary reconstructive procedures on the shoulder, either before or after nerve transfer, were excluded.

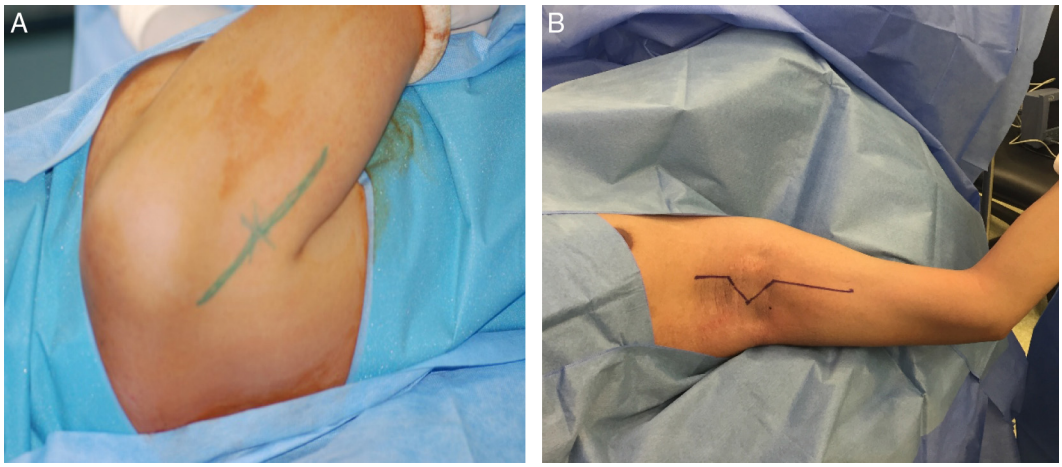

Fig. 1 – (A) Skin marking of the posterior arm approach from the posterior border of the deltoid muscle and following distally in a line between the long and lateral heads of the triceps muscle; (B) skin marking of the axillary approach, with an incision that begins in the middle of the armpit, and continues along the brachial vessels to the upper arm.

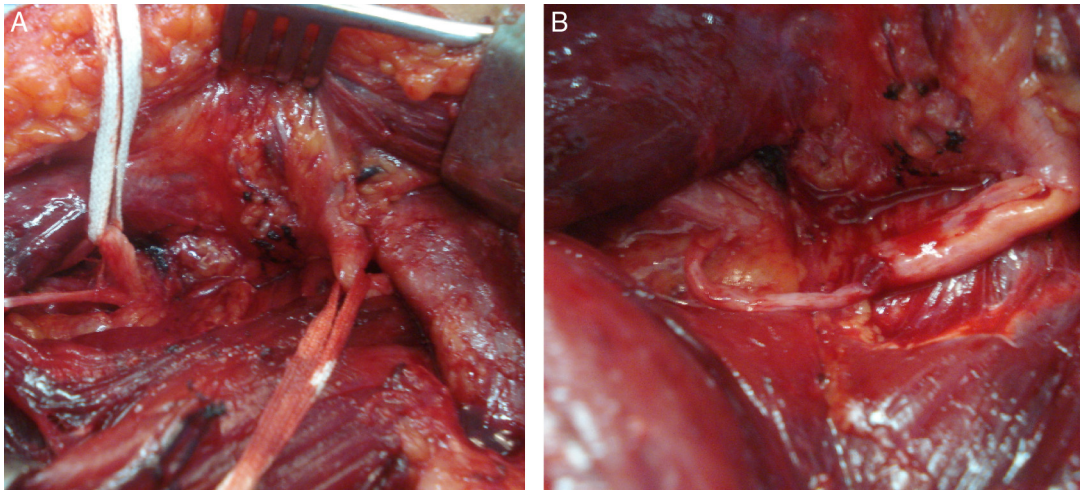

Fig. 2 – (A) Motor branch of the triceps (RM tri) and axillary nerve (Axi), already dissected and repaired; (B) motor branch of the triceps (RM tri) and axillary nerve (Axi) were sectioned and coapted to later receive suture with 9-0 nylon and fibrin glue.

Surgical technique and rehabilitation

The patients were placed in dorsal recumbent position, with their head turned to the healthy side, under general anesthesia and without muscle relaxants; the supraclavicular brachial plexus was explored. The suprascapular nerve was located along the lateral aspect of the upper trunk. At the lateral border of the sternocleidomastoid muscle, the accessory spinal nerve was located distally and laterally in the posterior triangle. After dissecting the nerve as distally as possible, leaving the upper branches of the trapezius muscle intact, the distal part of the accessory spinal nerve was divided, displaced proximally, and coapted with the suprascapular nerve using a 9-0 nylon suture and fibrin glue.

The neurotization of one of the motor branches of the triceps to the axillary nerve was performed through two access routes:

Posterior arm: a 10 cm longitudinal incision is made on the posterior face of the arm from the posterior border of the deltoid muscle, followed distally in a line between the long and lateral heads of the triceps (Fig. 1). A deep dissection exposes the teres major tendon. The axillary nerve is dissected and divided as proximally as possible, so that all branches to the deltoid and teres minor muscle are identified; it is not always possible to identify the branches to the teres minor through

this approach. The nerve branches to the long, medial, and lateral heads of the triceps are identified and confirmed with a nerve stimulator. One of the nerve branches for the triceps is dissected as distally as possible, divided and reflected proximally, and coapted to the axillary nerve; a simple nylon 9-0 suture is made and fibrin glue is used (Fig. 2).

Axillary: The incision begins in the armpit and continues to the medial upper arm (Fig. 1). The nerve branches to the long, medial, and lateral heads of the triceps muscle are identified and confirmed with a nerve stimulator. The affected limb is abducted and externally rotated; the tendon of the latissimus dorsi muscle is identified. A deep dissection is made toward the medial border of the latissimus dorsi and the lateral border of the subscapularis muscle. The quadrangular space is palpated and the axillary nerve is located in a triangle delimited by the tendon of the latissimus dorsi muscle, the posterior humeral circumflex artery, and the subscapular artery. The anterior and middle branches to the deltoid muscle and the axillary nerve branch to the teres minor are identified; the latter is sectioned proximally to the origin of these branches and distally folded back. One of the radial nerve branches to the triceps is dissected as distally as possible, divided and reflected proximally, and coapted to the axillary nerve; a simple nylon 9-0 suture is made and fibrin glue is used,

At the end of the surgical procedure, the patients are immobilized in a sling for three weeks. Slight movements are allowed in order to prevent stiffness. After the third week, movements are gradually increased to maintain the range of motion. Exercises for muscle strengthening are initiated as soon as muscle activity begins.

Assessment

The data evaluated in the patients' medical charts included age, gender, trauma mechanism, laterality, time of injury until the surgical procedure, approach used (posterior arm or axillary), and pre and postoperative physical examination. The physical examination included all tests for upper limb musculature using the British Medical Research Council (BMRC) scale; a result was considered effective when a return of muscular strength greater than or equal to M3 was observed.

Statistical analysis

The results between groups were compared using Fisher's exact test. The p-values were two tailed; p-values < 0.05 were considered to be statistically significant. All analyses were performed using the software *Statistical Package for the Social Sciences* SPSS, version 15.

Results

From 2010 to 2014, 33 patients underwent surgery due to upper brachial plexus trunk injury (C5 and C6 roots); they underwent neurotization of the suprascapular nerve to the accessory nerve and axillary nerve neurotization to one of the triceps motor branches. Of this total, one patient was excluded from the sample as the time between injury and surgery had been longer than one year, and five were excluded due to loss of follow-up (patients who were operated at the institution and returned to their city of origin). A total of 27 patients met the inclusion criteria. In all of them, the neurotization of the accessory nerve to the suprascapular nerve was performed using the aforementioned technique. Regarding axillary nerve neurotization to one of the triceps motor branches, the axillary approach was used in 13 patients and in the posterior arm approach, in 14 patients.

All patients were male, between 17 and 50 years of age (mean of 27.8). Left brachial plexus lesion was observed in 14 patients; in 13 patients, this lesion was observed on the right side. The time between initial lesion and surgery ranged from 4 to 11 months (mean of 6.6). Motorcycle accident was the cause of the injury in 22 patients, two were victims of automobile accident, and three had been run over. In all patients, the preoperative physical examination showed

Table 1 – Axillary approach.

Patient	Age (years)	Side	Time of injury (months)	BMRC scale – abduction	BMRC scale – external rotation
1	26	R	5	4	4
2	33	L	7	4	4
2	23	R	6	0	0
4	26	R	9	4	3
5	20	L	8	3	3
6	29	R	6	3	2
7	32	R	5	2	4
8	22	R	6	2	4
9	19	L	5	4	0
10	25	R	4	4	3
11	20	L	8	3	3
12	30	R	10	4	3
13	21	L	7	4	0

Table 2 – Posterior arm approach.

Patient	Age (years)	Side	Time of injury (months)	BMRC scale – abduction	BMRC scale – external rotation
14	21	L	9	3	3
15	25	L	11	3	4
16	45	L	6	4	3
17	45	R	5	2	2
18	23	L	6	4	4
19	31	L	7	3	2
20	50	R	7	3	3
21	18	L	5	2	1
22	44	L	7	0	0
23	20	L	4	3	2
24	30	R	4	4	3
25	28	R	11	0	0
26	23	L	5	4	3
27	29	R	6	3	0

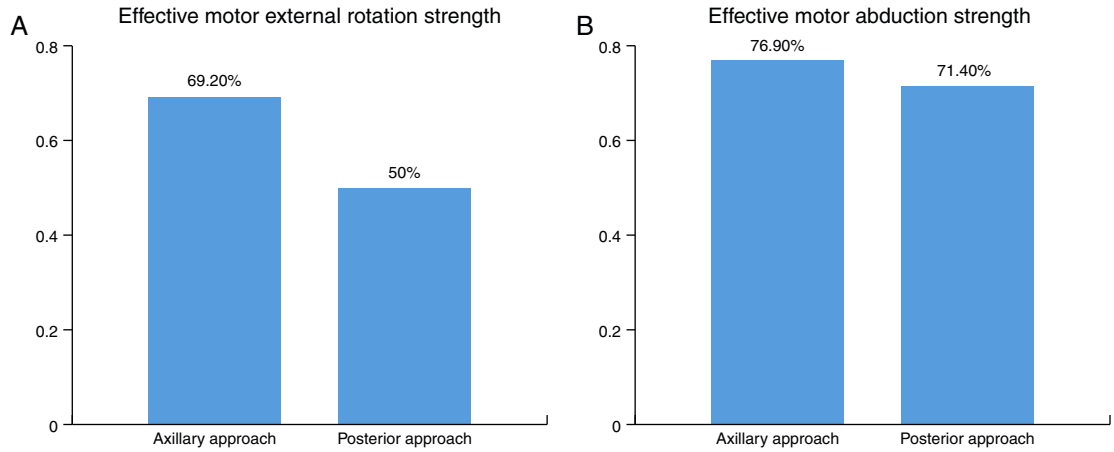

Fig. 3 – (A) Comparison of the recovery of effective motor abduction strength between the axillary and posterior arm approaches (Fisher's exact test: $p = 1.000$); (B) comparison of the recovery of effective motor external rotation strength between the axillary and posterior arm approaches (Fisher's exact test: $p = 0.440$).

supraspinatus, infraspinatus, and deltoid muscle atrophy; none of the patients were able to abduct or externally rotate the affected shoulder. Furthermore, all patients presented at least one triceps muscle classified as M4 preoperatively. In all patients, the physical examination and radiographs confirmed subluxation of the glenohumeral joint, and electroneuromyography tests indicated an injury consistent with upper trunk paralysis of the brachial plexus.

The muscle abduction and external rotation range for groups submitted to surgery through the axillary and posterior arm approaches are summarized in Tables 1 and 2, respectively. An M3 or greater grade was considered as an effective recovery of motor function.

Of the 13 patients in whom the axillary approach was used for neurotization of the axillary nerve to a triceps motor branch, seven (53.8%) achieved an M4 abduction recovery, three (23.1%) recovered to M3, while three (23.1%) reached M2 or lower. Regarding the external rotation strength, four (30.7%) patients achieved grade M4; five (38.5%), M3; and four (30.7%) reached a M2 or lower grade. A total of 76.9% of the patients recovered effective motor function in abduction, while 69.2% recovered this function in external rotation.

Of the 14 patients in whom the posterior arm approach was used for neurotization of the axillary nerve to a triceps motor branch, four (28.6%) achieved M4 abduction recovery, six (42.8%) recovered to M3, while four (28.6%) reached M2 or lower. Regarding the external rotation strength, two (14.3%) patients achieved grade M4; five (35.7%), M3; and seven (50%) reached M2 or a lower grade. A total of 71.4% of the patients recovered effective motor function in abduction, while 50% recovered function in external rotation.

Regarding the BMRC scale, considering the effective motor strength recovery, no significant differences were observed between the two groups for abduction ($p = 1.000$; Fig. 3A) and for external rotation ($p = 0.440$; Fig. 3B).

Discussion

In patients with upper brachial plexus injury, the main goal of reconstruction is flexion of the elbow and abduction and external rotation of the shoulder. For patients who are operated on early, the most commonly used strategy is to explore the brachial plexus with a supraclavicular approach and use of nerve grafting or nerve transfer according to the intraoperative findings.[5–7] However, some patients present with older lesions; in these cases, if the repair of the brachial plexus is made at the supraclavicular level, reinnervation takes a long time to reach the target muscles, which leads to motor plaque degeneration and poor functional outcome. In addition, during brachial plexus exploration, some patients present with root avulsions and intense scar tissue formation; the use of the proximal roots as donors is not adequate. For these patients, a direct nerve transfer to the target nerve, thus closer to the muscle to be reinvigorated, has attracted greater interest in recent decades.[11,13,14]

Direct multiple nerve transfers to the target nerve have been described, including transfer of the accessory nerve to the suprascapular nerve, fascicles of the ulnar nerve to the motor branch of the biceps, and the motor branch of the long or lateral head of the triceps to the axillary nerve.[7,8] Bertelli and Ghizoni[9] and Leechavengyongs et al.[15] demonstrated that upper brachial plexus reconstruction with these three transfers improved the functional recovery of the shoulder and elbow. However, the procedures described were performed using three surgical approaches.

In 2007, Bertelli et al.[12] described the anatomical bases and clinical results of the transfer of one of the motor branches of the triceps nerve to the axillary nerve through an axillary access route. This access route has the advantage of allowing better individualization of the axillary nerve branches, including the motor branch of the teres minor.[12] Moreover, the axillary approach is safer because it allows direct visualization

of the great vessels, does not involve the section of muscular fibers, and allows the transfer of fascicles from the ulnar nerve to the biceps motor branch by the same approach, differently from the posterior arm approach.

Kostas-Agnantis et al.[16] described a series of nine patients who underwent triple nerve transfer by transferring one of the triceps motor branches to the posterior axillary nerve; these patients reached a mean abduction strength on the BRMC scale of 3.6, and a mean external rotation of 3.2 points. In the present series, the recovery of effective abduction strength, considered as a BRMC score greater than or equal to 3 (76.9% in the axillary approach group and 71.4% in the posterior arm approach group), and of the effective external rotation strength (69.2% in the axillary approach group and 50% in the posterior arm approach group) was similar to other reports in the literature.[8,11,17] Still in agreement with other authors, the external rotation gain in both groups was inferior to that of abduction.[18–20] One of the explanations for this smaller gain in external rotation is that most authors consider the suprascapular nerve that innervates the supraspinatus muscle as the first reconstruction target, but few perform the nerve transfer to the branch of the teres minor, a muscle that contributes to shoulder stabilization and external rotation.[16] Knowing the great contribution of the teres minor to the external rotation function, it seems logical to include this muscle in the reconstruction strategy. As Bertelli et al.[12] has already described in his anatomical study, the identification of the axillary nerve branch to the teres minor is technically easier through the axillary approach; this finding was observed in the present study, and facilitated neurotization. Other data found in the present study that corroborate this explanation is the fact that, although not statistically significant, patients in the axillary approach group presented greater gains in external rotation when compared with the group whose surgery was performed through the posterior arm approach (69.2% and 50%, respectively, with $p = 0.440$), which may be related to the greater ease of neurotization of the branch to the teres minor through the axillary approach.

The present results demonstrated a lack of significant differences in the functional outcome of external rotation and abduction between axillary nerve neurotizations through the axillary or posterior arm approach. However, through the axillary approach, fewer surgical approaches are needed to perform multiple neurotizations; it also allows a better identification of the axillary nerve branch to the teres minor, facilitating its neurotization. Moreover, it may justify the greater gain of external rotation observed in the group in which this approach was used. Further prospective randomized studies, including muscle strength measurement and range of motion gain, may confirm this trend.

Conclusion

Regarding effective strength recovery on the BRMC scale, the use of the axillary approach for the neurotization of a motor branch of the triceps to the axillary nerve did not present significant differences when compared with the use of the posterior arm approach.

Conflicts of interest

The authors declare no conflicts of interest.

REFERENCES

1. Sedel L. The results of surgical repair of brachial plexus injuries. J Bone Joint Surg Br. 1982;64(1):54–66.
2. Lee SK, Wolfe SW. Nerve transfers for the upper extremity: new horizons in nerve reconstruction. J Am Acad Orthop Surg. 2012;20(8):506–17.
3. Terzis JK, Barmpitsioti A. Secondary shoulder reconstruction in patients with brachial plexus injuries. J Plast Reconstr Aesthet Surg. 2011;64(7):843–53.
4. Bhandari PS, Deb P. Dorsal approach in transfer of the distal spinal accessory nerve into the suprascapular nerve: histomorphometric analysis and clinical results in 14 cases of upper brachial plexus injuries. J Hand Surg Am. 2011;36(7):1182–90.
5. Rühmann O, Gossé F, Wirth CJ, Schmolke S. Reconstructive operations for the paralyzed shoulder in brachial plexus palsy: concept of treatment. Injury. 1999;30(9):609–18.
6. Garg R, Merrell GA, Hillstrom HJ, Wolfe SW. Comparison of nerve transfers and nerve grafting for traumatic upper plexus palsy: a systematic review and analysis. J Bone Joint Surg Am. 2011;93(9):819–29.
7. Colbert SH, Mackinnon SE. Nerve transfers for brachial plexus reconstruction. Hand Clin. 2008;24(4):341–61.
8. Vekris MD, Beris AE, Pafilas D, Lykissas MG, Xenakis TA, Soucacos PN. Shoulder reanimation in posttraumatic brachial plexus paralysis. Injury. 2010;41(3):312–8.
9. Bertelli JA, Ghizoni MF. Reconstruction of C5 and C6 brachial plexus avulsion injury by multiple nerve transfers: spinal accessory to suprascapular, ulnar fascicles to biceps branch, and triceps long or lateral head branch to axillary nerve. J Hand Surg Am. 2004;29(1):131–9.
10. Bertelli JA, Ghizoni MF. Nerve transfer from triceps medial head and anconeus to deltoid for axillary nerve palsy. J Hand Surg Am. 2014;39(5):940–7.
11. Terzis JK, Barmpitsioti A. Axillary nerve reconstruction in 176 posttraumatic plexopathy patients. Plast Reconstr Surg. 2010;125(1):233–47.
12. Bertelli JA, Kechele PR, Santos MA, Duarte H, Ghizoni MF. Axillary nerve repair by triceps motor branch transfer through an axillary access: anatomical basis and clinical results. J Neurosurg. 2007;107(2):370–7.
13. Terzis JK, Kostas I. Suprascapular nerve reconstruction in 118 cases of adult posttraumatic brachial plexus. Plast Reconstr Surg. 2006;117(2):613–29.
14. Shin AY, Spinner RJ, Steinmann SP, Bishop AT. Adult traumatic brachial plexus injuries. J Am Acad Orthop Surg. 2005;13(6):382–96.
15. Leechavengvongs S, Witoonchart K, Uerpairojkit C, Thuvasethakul P, Malungpaishrope K. Combined nerve transfers for C5 and C6 brachial plexus avulsion injury. J Hand Surg Am. 2006;31(2):183–9.
16. Kostas-Agnantis I, Korompilias A, Vekris M, Lykissas M, Gkiatas I, Mitsionis G, et al. Shoulder abduction and external rotation restoration with nerve transfer. Injury. 2013;44(3):299–304.
17. Jerome JT. Long head of the triceps branch transfer to axillary nerve in C5, C6 brachial plexus injuries: anterior approach. Plast Reconstr Surg. 2011;128(3):740–1.

18. Malessy MJ, de Ruiter GC, de Boer KS, Thomeer RT. Evaluation of suprascapular nerve neurotization after nerve graft or transfer in the treatment of brachial plexus traction lesions. J Neurosurg. 2004;101(3):377–89.
19. Alnot JY, Rostoucher P, Oberlin C, Touam C. C5-C6 and C5-C6-C7 traumatic paralysis of the brachial plexus of the adult caused by supraclavicular lesions. Rev Chir Orthop Reparatrice Appar Mot. 1998;84(2):113–23.
20. El-Gammal TA, Fathi NA. Outcomes of surgical treatment of brachial plexus injuries using nerve grafting and nerve transfers. J Reconstr Microsurg. 2002;18(1):7–15.