Article published online: 2023-09-22

Minimally Invasive Surgery for Managing Grade IV and V Spondylolisthesis

Felipe Ramirez Velandia[1] David Camilo Gomez Cristancho[2] Andres Urrego Nieto[2]
Isabel Marquez[1] Alejandra Restrepo Martinez[1] Jaime Eduardo Becerra Ospina[3]
Juan Carlos Pérez Rodriguez[3,4]

[1] Neurology and Neurosurgery Research Group, Pontificia Universidad Javeriana, Bogotá D.C., Colombia
[2] Department of Neurologic Surgery, Universidad Nacional de Colombia, Neurosurgery Research Group, NeuroAxis SAS, Bogota D.C., Colombia
[3] Department of Neurologic Sugery, Pontificia Universidad Javeriana, Neurosurgery Research Group, NeuroAxis SAS, Bogota D.C., Colombia
[4] Department of Spinal Deformity Surgery, Instituto Nacional de Traumatología e Ortopedia Jamil Haddad, Río de Janeiro, Brazil

Address for correspondence Felipe Ramirez Velandia, MD, Neurology and Neurosurgery Research Group, Pontificia Universidad Javeriana, Carrera 7 # 40-62, Bogotá D.C. 110231, Colombia (e-mail: felipegolframirez@gmail.com).

Asian J Neurosurg 2023;18:437–443.

Abstract

Surgical treatment of high-grade spondylolisthesis is controversial and aims at restoring the spinopelvic sagittal balance through complete or partial reduction of the listhesis. Nerve decompression and interbody fusion are necessary for patients presenting with neurological deficit, severe pain, lower limb asymmetry, or deformities. We present the case and the results of a patient with high-grade spondylolisthesis, in whom minimally invasive management was performed. A narrative review in this topic is also provided.

We performed a literature review of high-grade spondylolisthesis to compare our technique to current surgical alternatives. We included articles from PubMed, Embase, Scopus, Ovid, and Science Direct published between 1963 and 2022 that were written in English, German, and Spanish. The terms used were the following: "high grade spondylolisthesis," "spondyloptosis," "surgical management," "interbody fusion," and "arthrodesis." In all, 485 articles were displayed, from which we filtered 112 by title and abstract. At the end, 75 references were selected for the review.

Different interbody fusion techniques can be used to correct the lumbosacral kyphosis and restore the spinopelvic parameters. A complete reduction of the listhesis is not always required. The surgical procedure carried out in our patient corresponds to the first known case of minimally invasive circumferential arthrodesis with iliac screws and sacral fixation in a high-grade dysplastic spondylolisthesis. This approach guarantees the correction of the lumbosacral kyphosis and a complete reduction of the listhesis. Further studies are required to determine whether the results of this case can be extrapolated to other patients with high-grade spondylolisthesis.

Keywords
- spondylolisthesis
- spondylosis
- spondylolysis
- minimally invasive surgical procedures
- lumbar spine surgery
- anterior lumbar interbody fusion

article published online
September 22, 2023

DOI https://doi.org/10.1055/s-0043-1771317.
ISSN 2248-9614.

© 2023. Asian Congress of Neurological Surgeons. All rights reserved.
This is an open access article published by Thieme under the terms of the Creative Commons Attribution-NonDerivative-NonCommercial-License, permitting copying and reproduction so long as the original work is given appropriate credit. Contents may not be used for commercial purposes, or adapted, remixed, transformed or built upon. (https://creativecommons.org/licenses/by-nc-nd/4.0/)
Thieme Medical and Scientific Publishers Pvt. Ltd., A-12, 2nd Floor, Sector 2, Noida-201301 UP, India

Introduction

Spondylolisthesis, from the Greek *spondylos* (vertebrae) and *olisthesis* (slide), refers to the displacement of one vertebral body over the other, causing instability of the segment. The most common cause is degenerative spondylolisthesis, which affects older adults, has a prevalence of 19.1 to 43.1%, affects L4–L5, and has a higher female preponderance.[1] On the other hand, isthmic spondylolisthesis involves defects in unilateral or bilateral pars interarticularis, affects adolescents or younger adults, has an incidence of 5 to 7%, most commonly affects the L5–S1 level, and tend to occur more in males.[2] The incidence is much higher in people who develop activities that involve hyperextension stress forces, such as gymnastics, weightlifting, diving, football, and volleyball.

Spondyloptosis represents 5 to 15% of spondylolisthesis, affects almost exclusively the lumbosacral junction, and corresponds to dysplastic spondylolisthesis with some exceptions due to a traumatic nature.[3–6] Spondylolysis, facet, or laminar aplasia, wedging of L5, and dome deformation of the upper surface of S1 can be seen in traumatic spondyloptosis.[4,7–11] On the other hand, congenital spondyloptosis occurs due to a dysplasia of the upper articular process of the sacrum, which decreases the diameter of the foramina and triggers compression of the corresponding roots, producing a mixed pain that is very difficult to manage.[12,13]

Most individuals with isthmic spondylolisthesis are asymptomatic, and sliding is often discovered incidentally on plain radiographs. Symptomatic patients complain of activity-dependent low back pain that may be accompanied by radicular pain, which usually corresponds to the exiting nerve root at the level of the pars interarticularis defect.[5] In some cases, when the sliding is significant, the patient can present with cauda equina syndrome. There is no established age for the onset of symptoms; however, some patients with dysplastic forms may have a gradual onset of symptoms in adolescence.[4]

Surgical treatment of high-grade spondylolisthesis aims at restoring the spinopelvic sagittal balance through complete or partial reduction of the listhesis.[12,14–18] There is no consensus regarding the ideal surgical approach or technique; nevertheless, nerve decompression and interbody fusion are necessary in patients presenting with neurological deficit, severe pain, lower limb deep tendon reflex asymmetry, or deformity progression.[19–25] We present the case and the results of a patient with high-grade spondylolisthesis, in whom minimally invasive management was performed. Also, a narrative review in this topic is also provided.

Methods

We performed a literature review of high-grade spondylolisthesis to compare our technique to current surgical alternatives. We included articles from PubMed, Embase, Scopus, Ovid, and Science Direct published between 1963 and 2021 that were written in English, German, and Spanish. The terms used were the following: "high grade spondylolisthesis," "spondyloptosis," "surgical management," "interbody fusion," and "arthrodesis." After removing duplicates, 485 articles were filtered, from which we selected 112 based on their title and abstract. Other articles were included using a snowballing search approach. At the end, after reading the 112 articles, 70 were included and 8 others were included from the snowballing search. A total of 75 references were selected for the review.

Illustrative Case

A 38-year-old woman, nursing assistant, with no medical or traumatic history, presented to the outpatient clinic due to an 8-year history of back pain and neuropathic symptoms in the lower extremities, predominantly in the left lower extremity, associated with bilateral neurogenic claudication and pain exacerbation with back extension and prolonged fixed posture while standing. In the physical examination, pain was worsened with lumbar extension. Initially, physical therapy and analgesics were offered with poor response to these interventions. A lumbosacral magnetic resonance imaging (MRI) showed a grade IV L5–S1 isthmic spondylolisthesis, severe bilateral foraminal stenosis, and mild thoracolumbar scoliosis (►**Fig. 1A,B**). In addition, the panoramic X-ray films of the spine revealed a slip angle of 25.5 degrees, a lumbosacral angle of 86.4 degrees, and a Spinal Deformity Study Group (SDSG) angle of 4.85 degrees. The dynamic X-ray films of the lumbar spine showed signs of spinal instability.

In 2006, Mac-Thiong and Labelle proposed a surgical classification for dysplastic spondylolisthesis, taking into account the degree of slippage, the degree of dysplasia, and the sagittal spinopelvic balance from the measurement of the pelvic incidence (PI), sacral slope (SS), and pelvic tilt (PT) observed in anteroposterior and lateral preoperative radiographs of the lumbosacral spine.[26] Our patient was classified as Mac-Thiong type 7 (high grade, high dysplastic, balanced pelvis), given the trapezoid-shaped L5, high lumbosacral angle, SS 50 degrees or more, and PT 35 degrees or less.

Based on these findings, a circumferential lumbar arthrodesis was performed in two stages. We performed on the same surgical day a minimally invasive L5–S1 360-degree instrumentation, with anterior lumbar interbody fusion (ALIF), and posterior percutaneous L4–S2–iliac instrumentation. The estimated blood loss was less than 100 mL, and the surgical time for the two stages was 190 minutes. No intraoperative or postoperative complications were seen. She was discharged on her third postoperative day. Three months after surgery, the patient referred a 70% improvement in neuropathic pain in the left lower limb, and the computed tomography (CT) scan revealed an adequate bone fusion, along with an adequate correction of the sagittal balance and a significant reduction of listhesis (►**Fig 1C**), with a sliding angle of 1.56 degrees, a lumbosacral angle of 102 degrees, and an SDSG angle of –22.3 degrees. Due to a satisfactory postoperative recovery, the patient was discharged, and permission was given to return to her daily working activities.

 © 2023. Asian Congress of Neurological Surgeons. All rights reserved.

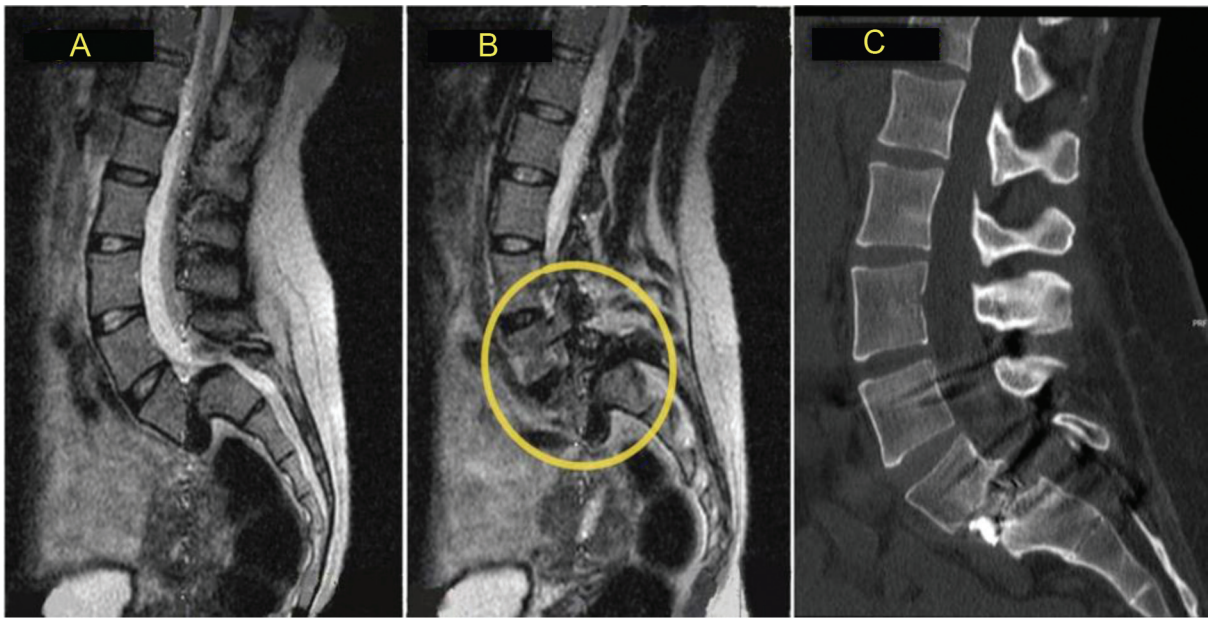

Fig. 1 (**A**) Lumbar spine magnetic resonance imaging (MRI) with grade IV L5–S1 dysplastic spondylolisthesis. (**B**) The *yellow circle* shows the foraminal stenosis secondary to spondylolisthesis. (**C**) Postoperative computed tomography (CT) lumbar spine after minimally invasive surgery (MIS) reduction.

Surgical Technique

The patient is placed in the Trendelenburg position with a roll at the level of the sacrum to achieve pelvic anteversion; subsequently, skin traction is performed with 7 kg of weight on each lower limb. Under electrophysiological neuromonitoring, an anterior mini-open ALIF approach was performed (see ►**Fig. 2A**). Through spacers anchored to the anterior wall of the vertebral body of L5, an anterior osteotomy of the lower L5 end plate is made to access the intervertebral space. Subsequently, distraction maneuvers are performed to extract the intervertebral disk decompressing the foramina and the posterior border of the vertebral end plates of L5 and S1. Afterward, to ensure adequate foraminal decompression, the posterior longitudinal ligament is resected until the epidural fat and slight epidural bleeding are seen, ensuring entry into the anterior epidural space. The intersomatic lumbar cage is then fixed to the dome of S1 with a locking screw, after placing a mix of autologous and heterologous bone graft inside the device. This fixation with a single caudal screw allows the posterior translation of L5 over the device.

Once the anterior approach is performed, the anterior wound is closed in the regular fashion and the patient is placed in the prone position. No skin traction is needed in this second approach. The screws are placed from caudal to cranial. The radiographic repair called "tear drop" is identified with the use of intraoperative fluoroscopy and the trans-S2–iliac entry point is marked on the skin. The anatomical landmark is the posterior iliac crest, 1 mm inferior and 1 mm lateral to the S1 foramen. Subsequently, a percutaneous technique is used to advance the screws to the lateral cortex of the iliac bone (see ►**Fig. 2B**). For L4, L5, and S1 levels, the conventional technique of percutaneous screw insertion is used, maintaining an adequate relationship between the sacral inclination and the vertebral body of L5, keeping a convergent trajectory and the largest possible diameter of screws bilaterally. This will help withstand the tensile loads when it comes to achieving the reduction of listhesis and avoiding the so-called pullout. Finally, the system is fixed to the previously bent titanium bars to achieve reduction and modify the slope of L5 following its natural contour and avoiding the external exposure of the material (see ►**Fig. 2C**). Afterward, each wound is closed in regular fashion.

Results

Different interbody fusion techniques have been described with the aim of achieving a complete or partial reduction of the listhesis. This can be done through a circumferential in situ anterior or posterior arthrodesis, isolated posterior arthrodesis or "stand-alone" ALIF,[7,20–22,27–31] using intra-sacral bars,[32] trans-sacral transfer screws for interbody fusion,[33–35] or custom-made screws.[36]

The circumferential approach, with anterior arthrodesis, and posterior transpedicular instrumentation along with reduction of the listhesis, has been reported to be superior to anterior or posterior fusion by themselves in terms of correction of lumbosacral kyphosis, bone healing rate, and risk of nonunion.[37,38] Several authors consider that circumferential arthrodesis provides a better balance of loads in the lumbosacral junction, greater stability, and greater surface area for bone fusion.[39–42]

However, there is a debate whether complete correction of spondylolisthesis is necessary weighed against complications such as neurological injury. Several authors advocate that reducing the listhesis may not be necessary if there are no neurological findings,[28] given the potential risks of causing neurological injury during the procedure, complication seen in

 © 2023. Asian Congress of Neurological Surgeons. All rights reserved.

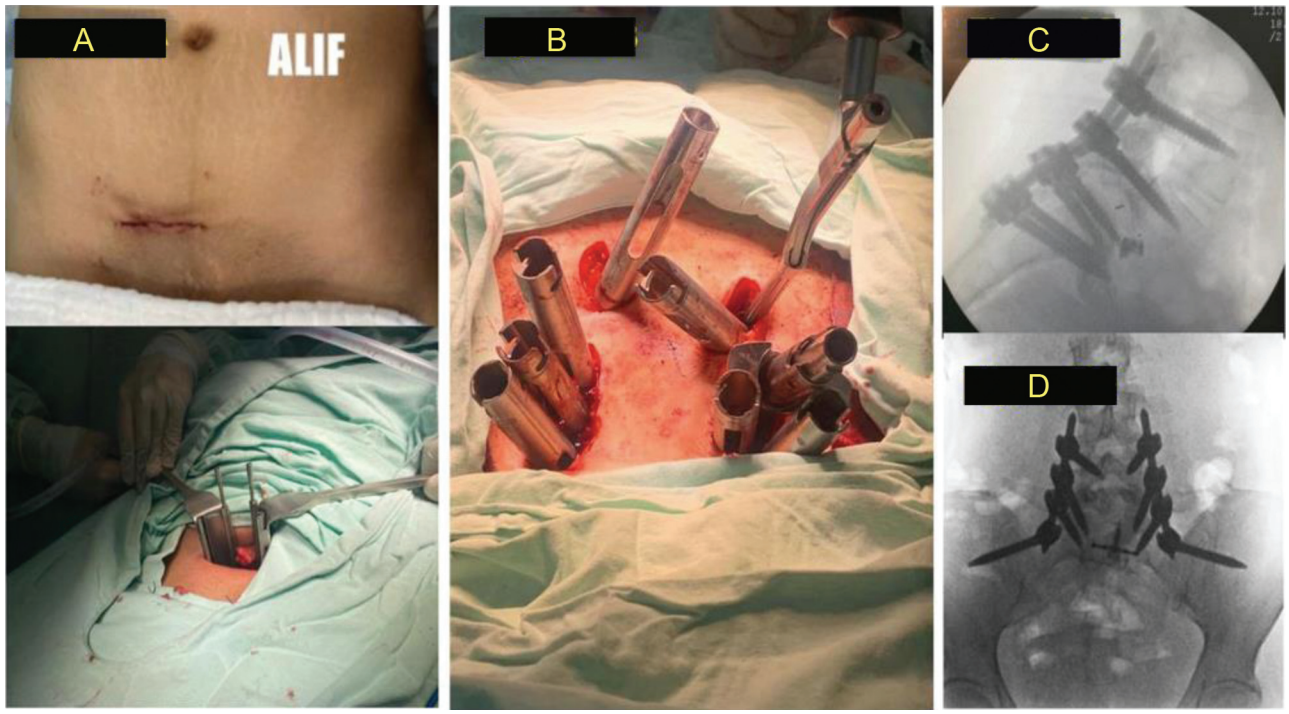

Fig. 2 (**A**) Approach for a mini-open anterior lumbar interbody fusion (ALIF). (**B**) Minimally invasive posterior approach for arthrodesis. (**C**,**D**) Intraoperative radiograph with adequate position of the arthrodesis material and complete reduction of the L5–S1 listhesis.

up to 25% of cases,[4,41,43,44] with L5 neuropraxia being the most common deficit.[40,45] Scheer et al did not find an association between carrying out a complete reduction with length of hospital stay, intraoperative complications, and postoperative complications; however, this retrospective study did not include patients with high-grade spondylolisthesis.[46] On the other hand, Labelle et al[18] found that interbody fusion with partial correction of high-grade spondylolisthesis was sufficient to improve spinopelvic parameters, as opposed to other authors who report that in situ posterior or anterior fusion without complete reduction of the listhesis does not resolve the adjacent biomechanical alteration, and leads to higher rates of pseudoarthrosis, disease progression, and even cauda equina syndrome.[29,40,47–55] Mac-Thiong and Labelle[26] considered that the reduction of high-grade spondylolisthesis allows direct decompression of the neural elements, corrects lumbosacral kyphosis, reduces tension on the fusion mass, improves sagittal spinopelvic balance, gait, and aesthetic appearance. In relation to this controversy, some authors consider that correcting lumbosacral kyphosis rather than the degree of sliding is essential in surgical treatment of high-grade spondylolisthesis since it is correlated with better results and relief of root compression.[4,18,26,56,57]

Also, Poussa et al[53] retrospectively reviewed data comparing groups that underwent staged circumferential reduction and fusion versus in situ fusion. At an average follow-up of 14.8 years, Oswestry Disability Index (ODI) and Scoliosis Research Society (SRS) scores were both significantly improved in the in situ group compared with the reduction group (1.6 vs. 7.2, $p = 0.0096$, and 90.0 vs. 103.9, $p = 0.046$, respectively). Furthermore, they reported significantly higher values for pain and postoperative function domains according to the SRS questionnaire. However, these findings may change since the surgical techniques evaluated in this study have changed in the last 30 years with the advent of newer fusion cages, screws, and the retread of retroperitoneal minimally invasive ALIF techniques.

Considering that in situ arthrodesis does not correct the lumbar kyphosis, it is associated with progression of the deformity and pseudoarthrosis, even when L4 is involved in the construct.[30,47,58,59] In addition, patients with dysplasia of the posterior elements of L4 and L5 may not be candidates for this technique due to limited space for the bone graft placement.[40] Nevertheless, posterior arthrodesis with autologous or heterologous graft, with transpedicular and transsacral screws, which achieve partial reduction (modified Bohlman technique) or complete reduction (Cloward technique) of the listhesis, are an adequate option to restore physiological lumbar lordosis, decrease lumbosacral shear forces, reduce the risk of nonunion, and maintain a permanent reduction of the listhesis.[7,29,48,59–62]

Furthermore, Hire et al report a case of L5–S1 spondyloptosis treated by using a modified Bohlman technique with replacement of the fibular graft with an axial lumbar interbody fusion (AxiaLIF) bolt with solid fusion and partial correction of lumbar kyphosis 2 years after the procedure, which proves to be a less technically demanding procedure with better outcome at long term.[63]

The stand-alone minimally invasive ALIF has shown in different case reports satisfactory results, clinically and radiographically in adolescents with high-grade listhesis.[64] However, Viglione et al concluded that there is limited evidence to support the safety and efficacy of this technique in the treatment of L5–S1 spondylolisthesis given the

 © 2023. Asian Congress of Neurological Surgeons. All rights reserved.

heterogeneity of the postsurgical results evaluated in the literature.[31] The Gaines technique is another described alternative that involves an L5 vertebrectomy with L4–S1 arthrodesis; however, it has been less accepted globally due to the high incidence of associated neurological and vascular complications.[23,59,65–67] Despite this, a similar technique involving a partial L5 vertebrectomy with resection of the S1 dome and posterior L4–S1 and iliac arthrodesis has been associated with a shorter surgical time, less bleeding, and lower risk of nerve injury.[68,69] Regardless of the interbody fusion used, it is common to perform decompression techniques such as laminectomies, microdiskectomies, and/or foraminotomies to relieve radicular pain.[27,28]

Concerning the extent of the arthrodesis, fixation to L4 is preferred when reduction is performed.[18,40,70] Additionally, the implementation of iliac screws for sacral fixation after reduction diminishes the risk of fatigue on the construction[40,70,71] and eliminates the need for anterior support if the spinopelvic balance is corrected after reduction.[26]

Discussion

Lumbar spondylolisthesis is the anterior translation of one vertebra over the other, which in most of the cases occurs due to a lysis in the pars interarticularis, creating instability and nerve compression. Thus, the standard of care is the interbody fusion, which can be open or percutaneous. The minimally invasive spine surgery (MIS) has increased in popularity in the last years, given the overall benefits in terms of recovery and minimal blood loss during the operation. A recent meta-analysis reported that patients with spondylolisthesis undergoing minimally invasive total lumbar interbody fusion (MI-TLIF) had less blood loss, less pain, and a lower rate of complications, without increasing the surgical time.[72]

Most of the cases of high-grade spondylolisthesis requiring surgical intervention are corrected using open procedures, and there is a scarcity of information on the use of MIS for such cases. The use of MIS has been reported in procedures of patients with low-grade spondylolisthesis. Alvi et al presented a case in which they achieved a reduction of a grade III L4–L5 isthmic anterolisthesis via MI-TLIF.[73] Mehdian et al described a similar technique with L5–S1 ALIF plus open posterior approach with L5 laminectomy, sacral dome osteotomy, and L4–S1 transpedicular instrumentation, obtaining good results in terms of reduction of the listhesis, absence of pseudoarthrosis, and improvement on the ODI and visual analog pain scale[74]; even so, the minimally invasive approach achieves comparable results in terms of intervertebral fusion and has a lower complication rate compared to open surgery.[75]

Based on the reviewed medical literature, the surgical procedure carried out in our patient corresponds to the first reported case of minimally invasive circumferential arthrodesis with iliac screws in a patient with a high-grade dysplastic spondylolisthesis. With the MIS, there is less segmental instability that can occur in open approaches; there is less need for muscle retraction leading to less tissue damage; and there is lower rate of secondary neurological deficit, pseudoarthrosis, and mechanical failures. Thus, the progressive incorporation of MIS in the treatment of complex spinal procedures like high-grade spondylolisthesis is promising; however, much more research in this area is required, and a greater number of cases are needed.

Conclusion

The management of high-grade spondylolisthesis is poorly defined; however, in the outlined case, the minimally invasive circumferential approach corrected the lumbosacral kyphosis and led to a complete reduction of listhesis. Further studies are required to determine whether the results of this case can be extrapolated to other patients with high-grade spondylolisthesis.

Contributors
David Camilo Gomez Cristancho conceived the presented idea and organized the information of the presented clinical case with the help of Andrés Urrego. Felipe Ramirez Velandia, Isabel Márquez, and Alejandra Restrepo performed the narrative search and organized the collected information. Jaime Eduardo Becerra and Juan Carlos Pérez Rodríguez helped supervise the whole project. All the authors discussed the results and contributed to the final manuscript.

Conflict of Interest
None declared.

References

1 Bydon M, Alvi MA, Goyal A. Degenerative lumbar spondylolisthesis: definition, natural history, conservative management, and surgical treatment. Neurosurg Clin N Am 2019;30(03):299–304
2 Bhalla A, Bono CM. Isthmic lumbar spondylolisthesis. Neurosurg Clin N Am 2019;30(03):283–290
3 Wiltse LL, Newman PH, Macnab I. Classification of spondylolisis and spondylolisthesis. Clin Orthop Relat Res 1976;(117):23–29
4 Ploumis A, Hantzidis P, Dimitriou C. High-grade dysplastic spondylolisthesis and spondyloptosis: report of three cases with surgical treatment and review of the literature. Acta Orthop Belg 2005;71(06):750–757
5 Mac-Thiong J-M, Labelle H, Kim D, Marchetti P, Bartolozzi P. Spondylolysis and spondylolisthesis. In:Surgery of the Pediatric Spine. Section III: Congenital Anomalies and Developmental Disorders. Germany: Thieme;2008. https://www.thieme-connect.de/products/ebooks/lookinside/10.1055/b-0034-72581
6 Newman PH, Stone KH. The etiology of spondylolisthesis. J Joint Bone Surg Brit 1963;45-B(01):39–59
7 Klöckner C, Weber U. Correction of lumbosacral kyphosis in high grade spondylolisthesis and spondyloptosis. Orthopade 2001;30(12):983–987
8 Curylo LJ, Edwards C, DeWald RW. Radiographic markers in spondyloptosis: implications for spondylolisthesis progression. Spine 2002;27(18):2021–2025
9 Miyake R, Ikata T, Katoh S, Morita T. Morphologic analysis of the facet joint in the immature lumbosacral spine with special reference to spondylolysis. Spine 1996;21(07):783–789
10 Yue W-M, Brodner W, Gaines RW. Abnormal spinal anatomy in 27 cases of surgically corrected spondyloptosis: proximal sacral endplate damage as a possible cause of spondyloptosis. Spine 2005;30(06):S22–S26

 © 2023. Asian Congress of Neurological Surgeons. All rights reserved.

11 McAfee PC, Yuan HA. Computed tomography in spondylolisthesis. Clin Orthop Relat Res 1982;(166):62–71
12 Ferris LR, Ho E, Leong JC. Lumbar spondyloptosis. A long term follow up of three cases. Int Orthop 1990;14(02):139–143
13 Lamartina C, Bassani R, Cecchinato R, Sinigaglia A, Berjano P. In-situ L5-S1 fusion of a stable, sagittally balanced L5 spondyloptosis. Eur Spine J 2014;23(12):2769–2770
14 Hanson DS, Bridwell KH, Rhee JM, Lenke LG. Correlation of pelvic incidence with low- and high-grade isthmic spondylolisthesis. Spine 2002;27(18):2026–2029
15 Jackson RP, Phipps T, Hales C, Surber J. Pelvic lordosis and alignment in spondylolisthesis. Spine 2003;28(02):151–160
16 Labelle H, Roussouly P, Chopin D, Berthonnaud E, Hresko T, O'Brien M. Spino-pelvic alignment after surgical correction for developmental spondylolisthesis. Eur Spine J 2008;17(09): 1170–1176
17 Rajnics P, Templier A, Skalli W, Lavaste F, Illés T. The association of sagittal spinal and pelvic parameters in asymptomatic persons and patients with isthmic spondylolisthesis. J Spinal Disord Tech 2002;15(01):24–30
18 Labelle H, Roussouly P, Berthonnaud E, Dimnet J, O'Brien M. The importance of spino-pelvic balance in L5-s1 developmental spondylolisthesis: a review of pertinent radiologic measurements. Spine 2005;30(06):S27–S34
19 Ghogawala Z, Dziura J, Butler WE, et al. Laminectomy plus fusion versus laminectomy alone for lumbar spondylolisthesis. N Engl J Med 2016;374(15):1424–1434
20 Ishihara H, Osada R, Kanamori M, et al. Minimum 10-year follow-up study of anterior lumbar interbody fusion for isthmic spondylolisthesis. J Spinal Disord 2001;14(02):91–99
21 Remes V, Lamberg T, Tervahartiala P, et al. Long-term outcome after posterolateral, anterior, and circumferential fusion for high-grade isthmic spondylolisthesis in children and adolescents: magnetic resonance imaging findings after average of 17-year follow-up. Spine 2006;31(21):2491–2499
22 Kayali H, Kahraman S, Sirin S, Atabey C. Treatment of L5-S1 spondyloptosis with single-stage surgery through the posterior approach: case report. Neurol Med Chir (Tokyo) 2004;44(07): 386–390
23 Lehmer SM, Steffee AD, Gaines RWJ Jr. Treatment of L5-S1 spondyloptosis by staged L5 resection with reduction and fusion of L4 onto S1 (Gaines procedure). Spine 1994;19(17):1916–1925
24 Hohmann F, Stürz H. Differential indications for lumbosacral fusion and reposition operation in spondylolisthesis. Orthopade 1997;26(09):781–789
25 Jones-Quaidoo SM, Hunt T, Shaffrey CI, Arlet V. Return of normal urological and neurological function after revision surgery for spondyloptosis. Case report. J Neurosurg Spine 2007;6(03): 272–275
26 Mac-Thiong J-M, Labelle H. A proposal for a surgical classification of pediatric lumbosacral spondylolisthesis based on current literature. Eur Spine J 2006;15(10):1425–1435
27 Bohlman HH, Cook SS. One-stage decompression and posterolateral and interbody fusion for lumbosacral spondyloptosis through a posterior approach. Report of two cases. J Bone Joint Surg Am 1982;64(03):415–418
28 Donnally CJ III, Madhavan K, Butler AJ, et al. A novel technique for stabilization of high-grade spondylolisthesis with transvertebral fusion without reduction. J Clin Neurosci 2019;60:170–175
29 Metz-Stavenhagen P, Sambale R, Völpel H-J, von Stavenhagen N. Treatment of the spondylolisthesis: operation in situ or reposition spondylodesis. Orthopade 1997;26(09):796–803
30 Tian W, Lang Z. Treatment of L5-S1 spondyloptosis with multiple pedicle defects through a combined anterior and posterior approach. World Neurosurg 2020;137:206–210
31 Viglione LL, Chamoli U, Diwan AD. Is stand-alone anterior lumbar interbody fusion a safe and efficacious treatment for isthmic spondylolisthesis of L5-S1? Global Spine J 2017;7(06):587–595
32 Bouyer B, Bachy M, Courvoisier A, Dromzee E, Mary P, Vialle R. High-grade lumbosacral spondylolisthesis reduction and fusion in children using transsacral rod fixation. Childs Nerv Syst 2014; 30(03):505–513
33 Bartolozzi P, Sandri A, Cassini M, Ricci M. One-stage posterior decompression-stabilization and trans-sacral interbody fusion after partial reduction for severe L5-S1 spondylolisthesis. Spine 2003;28(11):1135–1141
34 Abdu WA, Wilber RG, Emery SE. Pedicular transvertebral screw fixation of the lumbosacral spine in spondylolisthesis. A new technique for stabilization. Spine 1994;19(06):710–715
35 Lakshmanan P, Ahuja S, Lewis M, Howes J, Davies PR. Transsacral screw fixation for high-grade spondylolisthesis. Spine J 2009;9 (12):1024–1029
36 Jouve J-L, Blondel B, Fuentes S, Choufani E, Pesenti S, Bollini G. Circumferential fusion using a custom-made screw in the management of high-grade spondylolisthesis. Eur Spine J 2014;23 (Suppl 4):S457–S462
37 Muschik M, Zippel H, Perka C. Surgical management of severe spondylolisthesis in children and adolescents. Anterior fusion in situ versus anterior spondylodesis with posterior transpedicular instrumentation and reduction. Spine 1997;22(17):2036–2042, discussion 2043
38 Lindholm TS, Ragni P, Ylikoski M, Poussa M. Lumbar isthmic spondylolisthesis in children and adolescents. Radiologic evaluation and results of operative treatment. Spine 1990;15(12): 1350–1355
39 Mardjetko S, Albert T, Andersson G, et al. Spine/SRS spondylolisthesis summary statement. Spine 2005;30(06):S3
40 Molinari RW, Bridwell KH, Lenke LG, Ungacta FF, Riew KD. Complications in the surgical treatment of pediatric high-grade, isthmic dysplastic spondylolisthesis. A comparison of three surgical approaches. Spine 1999;24(16):1701–1711
41 Ani N, Keppler L, Biscup RS, Steffee AD. Reduction of high-grade slips (grades III-V) with VSP instrumentation. Report of a series of 41 cases. Spine 1991;16(06):S302–S310
42 Boos N, Marchesi D, Zuber K, Aebi M. Treatment of severe spondylolisthesis by reduction and pedicular fixation. A 4-6-year follow-up study. Spine 1993;18(12):1655–1661
43 Ruf M, Koch H, Melcher RP, Harms J. Anatomic reduction and monosegmental fusion in high-grade developmental spondylolisthesis. Spine 2006;31(03):269–274
44 Hu SS, Bradford DS, Transfeldt EE, Cohen M. Reduction of high-grade spondylolisthesis using Edwards instrumentation. Spine 1996;21(03):367–371
45 Fu K-MG, Smith JS, Polly DWJ Jr, et al. Morbidity and mortality in the surgical treatment of six hundred five pediatric patients with isthmic or dysplastic spondylolisthesis. Spine 2011;36(04): 308–312
46 Scheer JK, Auffinger B, Wong RH, et al. Minimally invasive transforaminal lumbar interbody fusion (TLIF) for spondylolisthesis in 282 patients: in situ arthrodesis versus reduction. World Neurosurg 2015;84(01):108–113
47 Grzegorzewski A, Kumar SJ. In situ posterolateral spine arthrodesis for grades III, IV, and V spondylolisthesis in children and adolescents. J Pediatr Orthop 2000;20(04):506–511
48 Boxall D, Bradford DS, Winter RB, Moe JH. Management of severe spondylolisthesis in children and adolescents. J Bone Joint Surg Am 1979;61(04):479–495
49 Maurice HD, Morley TR. Cauda equina lesions following fusion in situ and decompressive laminectomy for severe spondylolisthesis. Four case reports. Spine 1989;14(02):214–216
50 Harris IE, Weinstein SL. Long-term follow-up of patients with grade-III and IV spondylolisthesis. Treatment with and without posterior fusion. J Bone Joint Surg Am 1987;69(07):960–969
51 Johnson JR, Kirwan EO. The long-term results of fusion in situ for severe spondylolisthesis. J Bone Joint Surg Br 1983;65(01): 43–46

 © 2023. Asian Congress of Neurological Surgeons. All rights reserved.

52 Lenke LG, Bridwell KH, Bullis D, Betz RR, Baldus C, Schoenecker PL. Results of in situ fusion for isthmic spondylolisthesis. J Spinal Disord 1992;5(04):433–442
53 Poussa M, Schlenzka D, Seitsalo S, Ylikoski M, Hurri H, Osterman K. Surgical treatment of severe isthmic spondylolisthesis in adolescents. Reduction or fusion in situ. Spine 1993;18(07):894–901
54 Stanton RP, Meehan P, Lovell WW. Surgical fusion in childhood spondylolisthesis. J Pediatr Orthop 1985;5(04):411–415
55 Bradford DS, Boachie-Adjei O. Treatment of severe spondylolisthesis by anterior and posterior reduction and stabilization. A long-term follow-up study. J Bone Joint Surg Am 1990;72(07): 1060–1066
56 Petraco DM, Spivak JM, Cappadona JG, Kummer FJ, Neuwirth MG. An anatomic evaluation of L5 nerve stretch in spondylolisthesis reduction. Spine 1996;21(10):1133–1138, discussion 1139
57 Lamartina C. Posterior instrumentation, reduction and fusion in spondyloptosis. Eur Spine J 2010;19(10):1799–1800
58 Rindler RS, Miller BA, Eshraghi SR, et al. Efficacy of transsacral instrumentation for high-grade spondylolisthesis at L5-S1: a systematic review of the literature. World Neurosurg 2016; 95:623.e11–623.e19
59 Longo UG, Loppini M, Romeo G, Maffulli N, Denaro V. Evidence-based surgical management of spondylolisthesis: reduction or arthrodesis in situ. J Bone Joint Surg Am 2014;96(01):53–58
60 Cloward RB. Posterior lumbar interbody fusion updated. Clin Orthop Relat Res 1985;(193):16–19
61 Cloward RB. The treatment of ruptured lumbar intervertebral discs by vertebral body fusion. I. Indications, operative technique, after care. J Neurosurg 1953;10(02):154–168
62 Hart RA, Domes CM, Goodwin B, et al. High-grade spondylolisthesis treated using a modified Bohlman technique: results among multiple surgeons. J Neurosurg Spine 2014;20(05):523–530
63 Hire JM, Jacobs JM, Bundy JV, DeVine JG. A modified Bohlman technique using a novel implant for treatment of high-grade spondylolisthesis. J Neurosurg Spine 2015;22(01):80–83
64 Kerolus M, Turel MK, Tan L, Deutsch H. Stand-alone anterior lumbar interbody fusion: indications, techniques, surgical outcomes and complications. Expert Rev Med Devices 2016;13 (12):1127–1136
65 Gaines RW, Nichols WK. Treatment of spondyloptosis by two stage L5 vertebrectomy and reduction of L4 onto S1. Spine 1985; 10(07):680–686
66 Gelosi J. Espondiloptosis: técnica de Gaines. Rev Asoc Argent Ortop Traumatol 1999;65:299–301
67 Gaines RW. L5 vertebrectomy for the surgical treatment of spondyloptosis: thirty cases in 25 years. Spine 2005;30(06): S66–S70
68 Obeid I, Laouissat F, Bourghli A, Boissière L, Vital J-M. One-stage posterior spinal shortening by L5 partial spondylectomy for spondyloptosis or L5-S1 high-grade spondylolisthesis management. Eur Spine J 2016;25(02):664–670
69 Wild A, Jäger M, Werner A, Eulert J, Krauspe R. Treatment of congenital spondyloptosis in an 18-month-old patient with a 10-year follow-up. Spine 2001;26(21):E502–E505
70 Shufflebarger HL, Geck MJ. High-grade isthmic dysplastic spondylolisthesis: monosegmental surgical treatment. Spine 2005;30 (06):S42–S48
71 Kuklo TR, Bridwell KH, Lewis SJ, et al. Minimum 2-year analysis of sacropelvic fixation and L5-S1 fusion using S1 and iliac screws. Spine 2001;26(18):1976–1983
72 Chen Z, Wu W, Xiong H, et al. Systematic review and meta-analysis of the therapeutic effects of minimally invasive transforaminal interbody fusion on spondylolisthesis. Ann Palliat Med 2021;10(09):9848–9858
73 Alvi MA, Kerezoudis P, Alamoudi A, et al. Minimally invasive percutaneous approach for the management of high grade spondylolisthesis. J Neurosurg Sci 2018;62(04):521–522
74 Mehdian SH, Arun R. A new three-stage spinal shortening procedure for reduction of severe adolescent isthmic spondylolisthesis: a case series with medium- to long-term follow-up. Spine 2011; 36(11):E705–E711
75 Hoffmann C-H, Kandziora F. Minimally invasive transforaminal lumbar interbody fusion. Oper Orthop Traumatol 2020;32(03): 180–191

 © 2023. Asian Congress of Neurological Surgeons. All rights reserved.