LABIOMANDIBULAR GLOSSOTOMY APPROACH FOR CRANIOCERVICAL PATHOLOGIES - SPINE RECONSTRUCTION

ACESSO POR GLOSSOTOMIA LABIOMANDIBULAR EM PATOLOGIAS CRANIOCERVICAIS – RECONSTRUÇÃO DA COLUNA

ACCESO POR GLOSOTOMÍA LABIOMANDIBULAR EN PATOLOGÍAS CRANEOCERVICALES – RECONSTRUCCIÓN DE LA COLUMNA

Jackson Daniel Sousa Silva[1,2], Luis Eduardo Carelli Teixeira da Silva[1,2], Felipe Gomes Sousa e Silva[2], Renato Henrique Tavares[1,2], Alderico Girão Campos de Barros[1]

1. Instituto Nacional de Traumatologia e Ortopedia Jamil Haddad (INTO) – Avenida Brasil, 500, Cajú, Rio de Janeiro, RJ, Brazil.
2. Instituto da Coluna Vertebral do Rio de Janeiro (INCOL), Rio de Janeiro, RJ, Brazil.

ABSTRACT

Objectives: Exposing the clivus and upper cervical spine should, ideally, provide an adequate surgical field in which the surgeon can safely decompress and stabilize the craniovertebral junction (CVJ). We present a series of four cases with a narrative review of the literature in which Median Labiomandibular Glossotomy was used to treat CVJ disorders, in order to highlight the importance and indications of this access. Methods: We performed a retrospective analysis of patients who underwent MLMG for several pathologies. The group comprised four patients (two men and two women). Five approaches were performed (one revision surgery). Results: The approach was suitable for all cases, clivus was achieved when necessary. Distally, C4 was exposed to obtain satisfactory osteosynthesis. Laterally, we had a good view of the tumor borders and control of the vertebral artery. Complications encountered were a superficial wound infection that was easily healed, a later pharyngeal wound dehiscence and pseudoarthrosis, all in the same patient. There are 3 main anterior surgical techniques for managing lesions of the clivus, foramen magnum or upper cervical vertebrae. We chose Median Labiomadibular Glossotomy (MLMG) as a primary option, which provided a direct view of the clivus, C3 – C4 caudally and a wider surgical field. The main advantages of the MLMG technique include direct access to spinal pathology, an avascular plane through the median pharyngeal raphe, and a wider surgical field in both the transverse and sagittal dimensions. Conclusion: This approach provides excellent exposure of the craniocervical junction and upper cervical spine. ***Level of evidence IV; Series of cases analyzed retrospectively.***

Keywords: Craniocervical; Spine; Surgery.

RESUMO

Objetivos: A exposição do clivo e da coluna cervical alta deve, de modo ideal, proporcionar um campo cirúrgico adequado, no qual o cirurgião possa descomprimir e estabilizar a junção craniovertebral (JCV) com segurança. Apresentamos uma série de quatro casos, com revisão narrativa da literatura, nos quais a glossotomia labiomandibular mediana foi utilizada para tratamento de afecções da JCV, com o objetivo de destacar a importância e as indicações desse acesso. Métodos: Foi realizada uma análise retrospectiva dos pacientes submetidos a GLMM para diversas patologias. O grupo foi composto por quatro pacientes (dois homens e duas mulheres). Cinco abordagens/procedimentos<??> foram realizados (uma cirurgia de revisão). Resultados: O método/via de acesso/técnica foi adequado para todos os casos e o clivo foi alcançado quando necessário. Distalmente, C4 foi exposta para obter a osteossíntese satisfatória. Lateralmente, obteve-se boa visão das margens tumorais e controle da artéria vertebral. As complicações encontradas foram infecção superficial da ferida, com fácil cicatrização, deiscência tardia da parede posterior da faringe e pseudoartrose, todas no mesmo paciente. Existem três técnicas cirúrgicas principais com acesso anterior para o tratamento de lesões do clivo, forame magno ou vértebras cervicais superiores. Escolhemos a glossotomia labiomadibular mediana (GLMM) como opção primária, que proporcionou uma visão direta do clivo, de C3-C4 caudalmente e campo cirúrgico mais amplo. As principais vantagens da GLMM incluem acesso direto à patologia espinhal, plano avascular através da parte mediana da rafe da faringe e um campo cirúrgico ampliado nas dimensões transversa e sagital. Conclusões: Esta abordagem proporciona excelente exposição da junção craniocervical e da coluna cervical alta. ***Nível de evidência IV; Série de casos analisados retrospectivamente.***

Descritores: *Craniocervical; Coluna Vertebral; Cirurgia.*

RESUMEN

Objetivos: La exposición del clivus y de la columna cervical alta debe, de modo ideal, proporcionar un campo quirúrgico adecuado, en que el cirujano pueda descomprimir y estabilizar de manera segura la unión craneovertebral (UCV). Presentamos una serie de cuatro casos con revisión narrativa de la literatura, en los que se utilizó la glosotomía labiomandibular mediana para el tratamiento de afecciones

Study conducted at the Instituto Nacional de Traumatologia e Ortopedia Jamil Haddad (INTO) – Avenida Brasil, 500, Cajú, Rio de Janeiro, RJ, Brazil.
Correspondence: Jackson Daniel Sousa Silva. Instituto Nacional de Traumatologia e Ortopedia Jamil Haddad (INTO) – Avenida Brasil, 500, Cajú, Rio de Janeiro, Brazil - jacksonneuro@gmail.com

http://dx.doi.org/10.1590/S1808-185120212002224171

Received on 05/19/2019 accepted on 08/21/2020
Reviewed by: Marcelo Risso Marcelo Italo Risso-Neto

de la UCV, con el objetivo de destacar la importancia y las indicaciones de ese acceso. Métodos: Se realizó un análisis retrospectivo de los pacientes sometidos a GLMM para diversas patologías. El grupo fue compuesto por cuatro pacientes (dos hombres y dos mujeres). Fueron realizados cinco abordajes/procedimientos (una cirugía de revisión). Resultados: El método/vía de acceso/técnica fue adecuado para todos los casos y el clivus fue alcanzado cuando fue necesario. Distalmente, C4 fue expuesta para obtener la osteosíntesis satisfactoria. Lateralmente, se obtuvo buena visión de los márgenes tumorales y control de la arteria vertebral. Las complicaciones encontradas fueron infección superficial de la herida, con fácil cicatrización, dehiscencia tardía de la pared posterior de la faringe y pseudoartrosis, todas en el mismo paciente. Existen tres técnicas quirúrgicas principales con acceso anterior para el tratamiento de lesiones del clivus, foramen magno o vértebras cervicales superiores. Elegimos la glosotomía labiomandibular mediana (GLMM) como opción primaria, que proporcionó una visión directa del clivus, C3-C4 caudalmente y campo quirúrgico más amplio. Las principales ventajas de la GLMM incluyen acceso directo a la patología espinal, plano avascular a través de la parte mediana del rafe de la faringe y un campo quirúrgico ampliado en las dimensiones transversa y sagital. Conclusiones: Este abordaje proporciona excelente exposición de la unión craneocervical y de la columna cervical alta. ***Nivel de evidencia IV; Serie de casos analizados retrospectivamente.***

Descriptores: *Craniovertebral; Columna Vertebral; Cirugía.*

INTRODUCTION

The exposure of the clivus and upper cervical spine should, ideally, provide and optimal operative field in which the surgeon can decompress and stabilize craniovertebral junction (CVJ). Various surgical techniques have been described using the transcervical retropharyngeal,[1,2] retrocarotid lateral,[3] and pharyngeal approaches.[4] These techniques are unsuitable for accessing the upper cervical vertebrae, clivus and CVJ as they afford only limited ventral exposure, posing a risk to critical neurovascular structures.[5]

Roux[6] describe splitting the lower lip and mandible in the midline for tumors of the anterior tongue. A mandible and tongue splitting procedure was described by Kocher[7] and Trotter[8] for exposing the base of the tongue, epiglottis and posterior oropharyngeal wall. Hall et al.,[4] reported the use of the median labiomandibular glossotomy to gain surgical access to the upper cervical spine in the treatment of a case of cervical kyphosis causing myelopathy. Wood et all.,[9] used the same approach to access the clivus, operating on two patients, one with chordoma and the other with basilar impression.

The most direct approach to the clivus and upper cervical spine is through the transoral and transpalatopharyngeal wall. This approach has been used to fuse or decompress the upper spinal canal in many cases, such as chordoma, metastatic cancer, odontoid fracture, basilar invagination and hypertrophic rheumatic connective tissue.[10-14] The primary indication for MLMG is to provide access to the CVJ when this cannot be achieved by the standard transoral transpharyngeal technique, particularly in pediatric patients in whom exposure is limited due to the smaller anatomy, or in cases where the surgeon needs to reach the subaxial spine below discs C2 – C3, or where the inter-incisor distance is less than 3cm.

The MLMG approach is most often used for extradural pathologies,[15] such as congenital anomalies, benign or malignant neoplasms, inflammatory diseases and traumatic injury.[16] Congenital pathology may include cervical kyphosis and odontoid malformations.[17]

The main primary tumors on the clivus and upper cervical spine are chordomas, chondromas and chondrosarcoma. Osteogenic sarcoma and osteoblastoma may represent rare indications.[18] Rheumatoid arthritis is a relatively indication for the anterior approach to access CVJ.[19] Traumatic indications for the upper cervical spine are rare, with odontoid fracture being the most common,[20] but the majority can be treated with traction and immobilization.[16]

Here we present four cases in which the Median Labiomadibular Glossotomy (MLMG) approach was used to treat CVJ and upper cervical spine pathologies. We also present a review of the relevant literature, in order to highlight the importance and indications of this approach.

METHODS

We performed a retrospective analysis of patients who underwent MLMG for several pathologies. The group comprised four patients (two men and two women). Five approaches were performed (one revision surgery). The cases involved three tumors (aneurysmal bone cyst, chordoma and giant cell tumor) and one congenital kyphosis. Each patient was subjected to tracheostomy, as an initial step. Palatotomy was not necessary in case 1 only. The reconstructions were performed using a harms cage filled with bone graft in three cases. In the fourth, the reconstruction was performed with a fibular bone allograft. In the patients with tumor (cases 2, 3 and 4), cerebral angiogram with balloon occlusion of the vertebral artery was performed to determine the feasibility of vessel sacrifice. The main vessel feeding the tumor was embolized and occluded with coil in these cases. Broad spectrum antibiotics, including anaerobic antibiotics, were given to all four patients. This work was approved by the INTO ethics committee under number 053/2018. As this is a review of medical records, the participants did not need to sign an informed consent form.

Operative Technique

First, all patients were submitted to a posterior occipitocervical fusion. The patient is placed in the supine position. A tracheostomy tube is placed initially, to provide a good view of the posterior oropharynx and to ensure a secure airway postoperatively, avoiding complications secondary to significant lingual and oropharyngeal oedema. The perioral region, jaw, neck, mouth and oropharynx are prepared and sterile drapes are applied.

A midline incision is made from the lower lip and sublabial crease, curving around the chin pad, back to the midline on the submental space, extending inferiorly to the hyoid bone. (Figure 1A)

The soft tissue of the anterior neck is incised at the midline between the hyoid and mandible, with anterior exposure of the mandible at the planned osteotomy site. Mini plates and screws are positioned and molded before, for later replacement. (Figure 1B) The osteotomy is made with an oscillating saw, following a median line and preserving the central incisor roots. (Figure 1C) This step ensures the occlusion relationships are preserved postoperatively.

Following a mandibular osteotomy, the soft tissue dissection on the floor of the mouth is continued along the midline, between the submandibular ducts, and continued into the intrinsic tongue musculature. Retention sutures are then placed on either side of the tongue, to retract it. (Figure 2A) An electrocautery incision is made posteriorly along the median raphe to expose the lingual surface of the epiglottis as far as the hyoid, exposing the posterior oropharyngeal wall. The mandibular lingual halves are spread laterally and held in place by retractors. (Figure 2B) Midline split of the soft plate can be performed.

The posterior pharyngeal wall is infiltrated and then incised along the median raphe. The pharyngeal flaps are moved to either side to expose the clivus and upper cervical spine, (Figure 2C) or incised using the Harms-schmelzle[21] technique, with an open-door flap to provided better access to the lateral aspects of the C1 – C2 joints, with the added advantage that it is covered by a metallic prosthesis, preserving the arterial blood supply.

Retractors are used to expose the surgical field, allowing for decompression or resection of the lesion. Anterior internal fixation can be done using a titanium implant or bone graft. Meticulous closure is performed along the longus colli muscle and prevertebral fascia.

The pharyngeal wall is closed in two layers: first the pharyngeal musculature, then the mucosa. The tongue is reconstructed from posterior to anterior using absorbable suture thread. The intrinsic lingual musculature is brought together, and the ventral surface of the tongue and floor of the mouth are closed, in that order.

The mandibular osteotomy is re-positioned using the prefashioned rigid fixation plate and screws for osteosynthesis. When closing the floor of the mouth, care must be taken to cover the osteotomy site intraorally. The soft tissue of the lip, chin and mentual region are closed in layers with careful reapproximation of the vermilion – cutaneous junction. A nasogastric feeding tube is placed beyond the posterior pharyngeal incision, under direct visualization.

RESULTS

The approach was suitable for all cases, and clivus was achieved when necessary. (cases 3 and 4) Distally, C4 was exposed to obtain a satisfactory osteosynthesis. Laterally, we had a good view of the tumor and vascular control of vertebral artery.

Complications encountered were a superficial wound infection which was easily healed, a later pharyngeal wound dehiscence and pseudoarthrosis, in the same patient (case 1). There were two cases of velopharyngeal insufficiency. No problems were reported with the mandible osteosynthesis or tracheotomy. In two cases (3 and 4) anterolateral-retropharyngeal decompression was necessary for recurrent tumors. These two patients were undergoing radiotherapy. One death occurred (case 4), four months after index surgery for recurrent tumor and skull base invasion.

Illustrative Case

A 20-year-old woman presented with diffuse cervical pain, paresthesia on the left side and Hoffman signal, presumably Brown--Sequard syndrome caused by severe ventral cervicomedullary compression secondary to a congenital cervical kyphosis and CVJ instability. (Figure 3)

She had undergone to occipitocervicothoracic fixation and C1, C2 laminectomy in the first stage of the procedure, followed by an MLMG approach with resection of the lower part of the C2 and C3 vertebral body. Good decompression and cervical sagittal balance were achieved. The anterior fixation was secured by a titanium cage mesh filled with autograft bone from C2 to C4. (Figure 4)

Postoperatively, a superficial infection on the subcutaneous tissue of the lower lip was treated and in the long-term follow-up, the

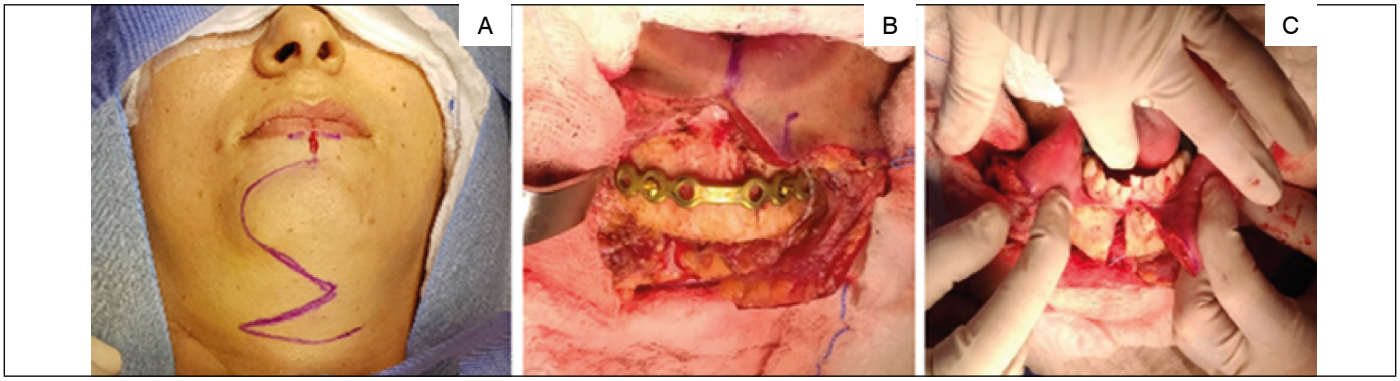

Figure 1. A - Planning incision. B - Planning reconstruction. C – Mandibular osteotomy.

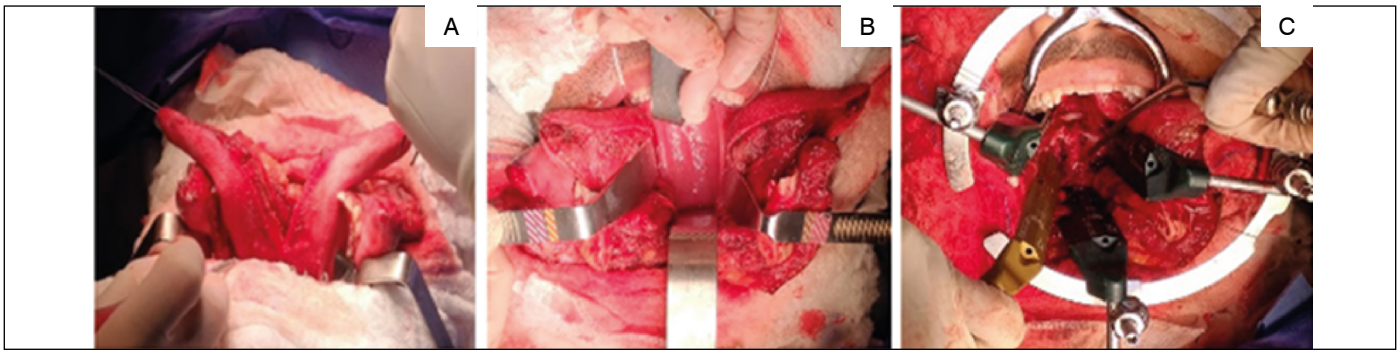

Figure 2. A – Tongue split. B – Pharyngeal wall. C – Exposure of the clivus and upper cervical spine.

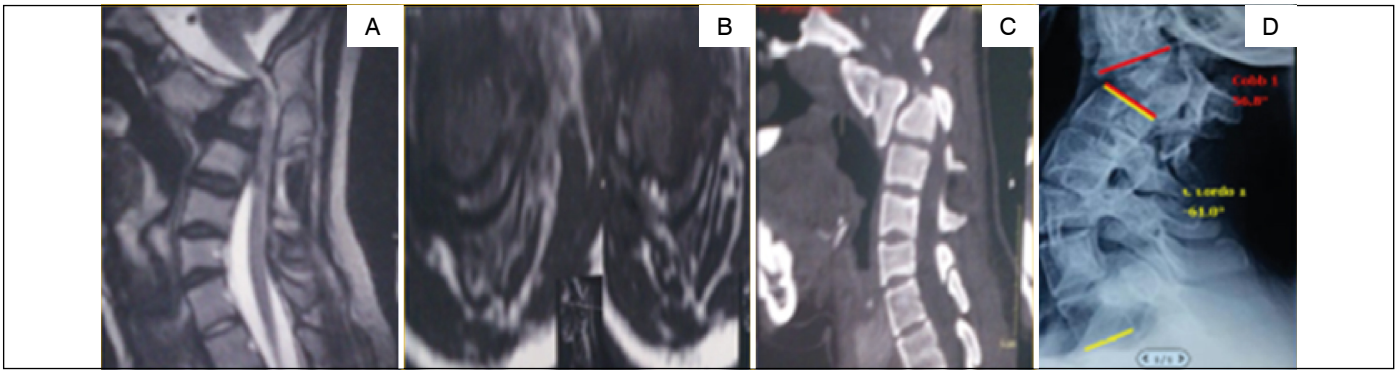

Figure 3. A and B – MRI sagittal and axial views showing severe medullary compression. C and D - CT scan and X-ray showing congenital kyphosis.

patient presented with asymptomatic pseudoarthrosis.

Almost two years after the first surgery, she again complained of numbness and difficulty walking. She presented hemiparesis on the right side and a new symptom: difficulty and pain on swallowing. New examinations were conducted, which showed progression of pseudoarthrosis and posterior pharyngeal wound dehiscence. The patient was submitted to a revision surgery by the same approach (MLMG). The cage was taken out and decompression of the spine cord was achieved. For the fusion, we used an iliac crest graft. Three weeks later, she developed Brown-Sequard syndrome on her right side with an epidural abscess, which was drained and a para--pharyngeal drain inserted. Due to the paresis, thromboprophylaxis was administrated resulting in a hematoma on the pharyngeal wall. We performed angiography of the cervical vasculature, and no abnormalities were found. A gastrostomy was placed for feeding. She is now recovering, with improvement in her strength, improved ability to swallow, and good healing of the pharyngeal wall. (Figure 5- 9)

Our cases are summarized in Table 1, followed by images of the cases.

DISCUSSION

A combined transoral-transpharyngeal approach with a median mandibulotomy (median labiomandibular approach) allows the caudal exposure to the C3 – C4 interspace to be increased and maintains the superior exposure of the lower third of the clivus. Dividing the tongue along the midline further increases caudal exposure to the C4 – C5 interspace (MLMG approach).[22-26] This approach has been used in the treatment of a variety of pathological process, with the final goal of decompression, fusion, or both, as we can see in our paper.

There are 3 main anterior surgical techniques for managing lesions of the clivus, foramen magnum or upper cervical vertebrae.[27-31] The first is the transoral standard approach, which allows the surgeon to operate directly on any intra- or extradural lesion located between the clivus and third cervical vertebrae.[32] The disadvantage of this approach is that the working space is limited, and there is a high risk of surgical field contamination. If the patient has limited mouth opening and restricted neck extension, the transoral approach does not provide adequate exposure for surgery. This was the case with one of the patients of our series. The second anterior technique is

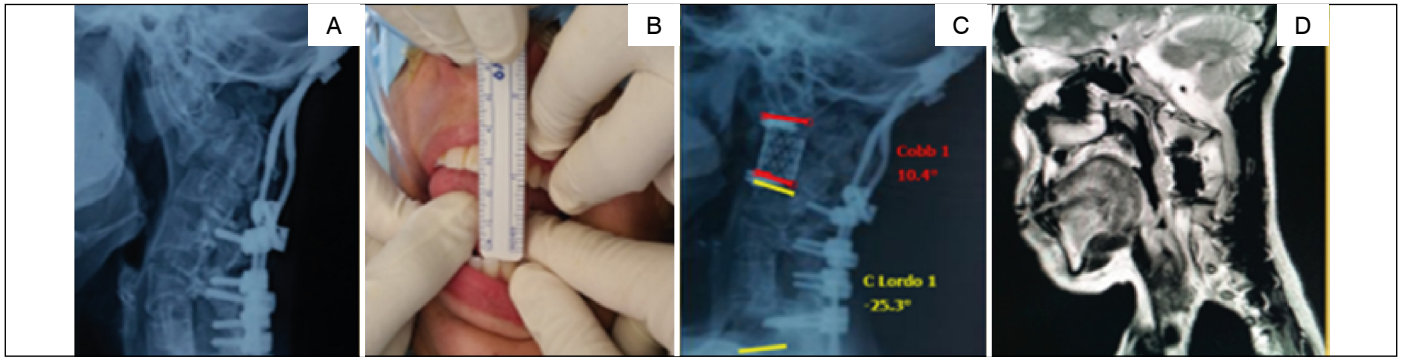

Figure 4. A – Occipitocervical fixation. B – Mouth opening < 3cm. C – Postoperative of anterior approach. D – MRI with medullary decompression.

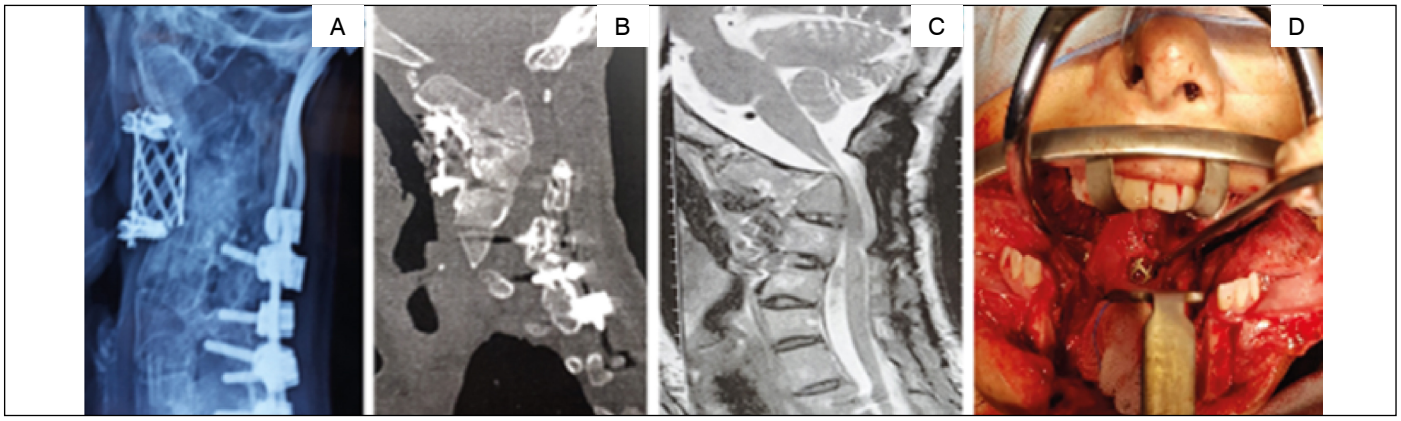

Figure 5. A – X-ray showing displaced cage. B – Bone growth behind the cage. C – MRI showing medullary compression. D – Dehiscence of the pharyngeal wall.

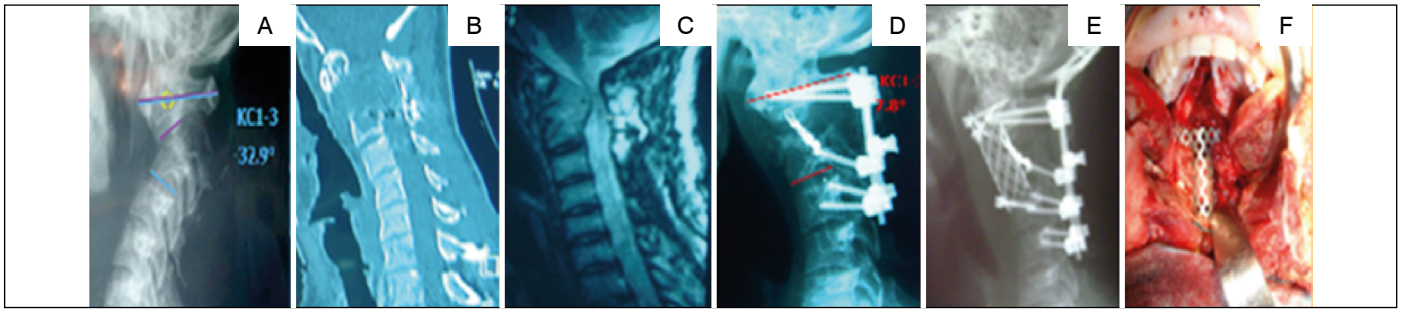

Figure 6. (case 2): A – Cervical Kyphosis. B – Lytic lesion C1-C3. C – T2 sagittal MRI showing tumor and medullary compression. D – C1–C4 posterior fixation. E – Anterior reconstruction C1-C4. F – Intraoperative view.

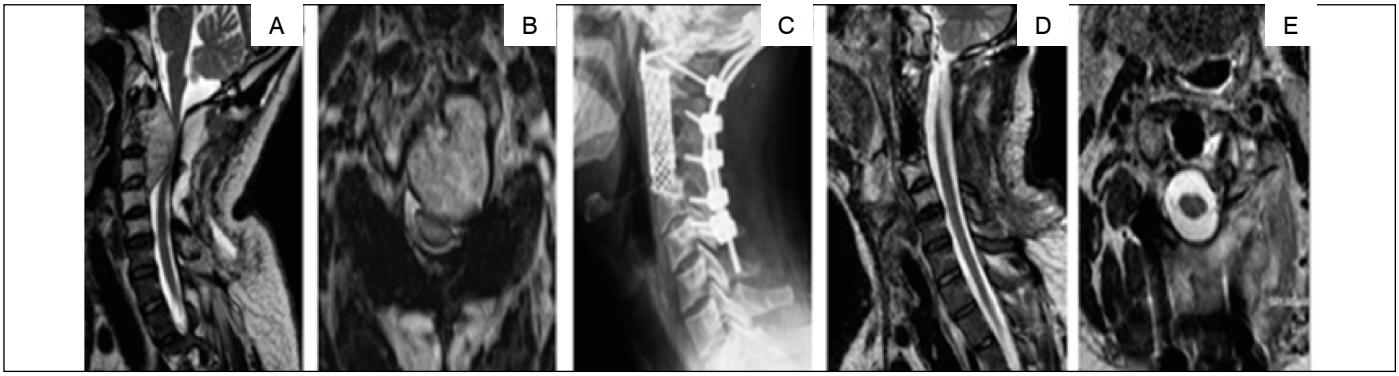

Figure 7. (case 3): A and B – T2 MRI showing a huge recurrent extradural lesion from C1-C4. C – Anterior reconstruction after tumoral removal. D and E – T2 MRI showing no residual tumor and medullary decompression.

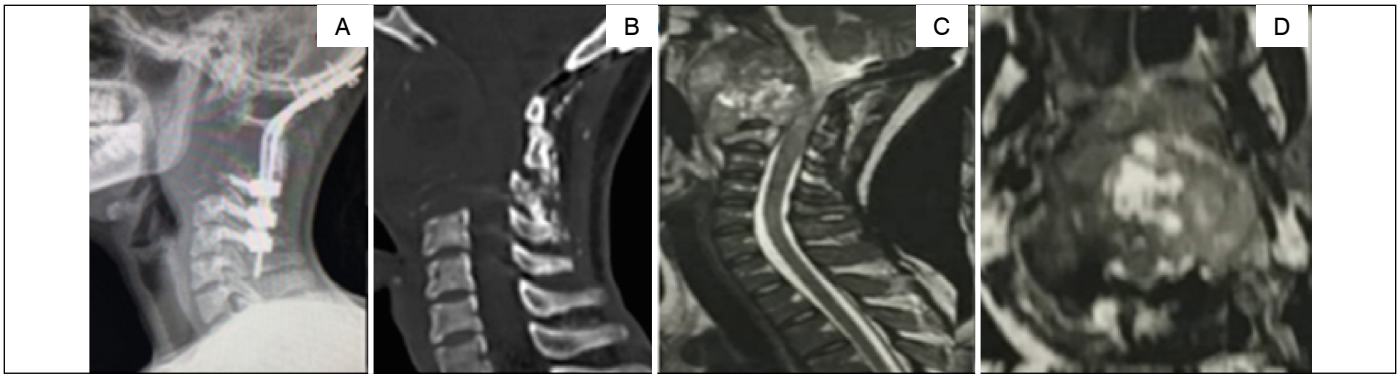

Figure 8. (case 4): A and B – X ray and CT scan showing litic lesion from C0-C4. C and D – T2 MRI sagittal and axial views showing heterogeneous lesion in CVJ.

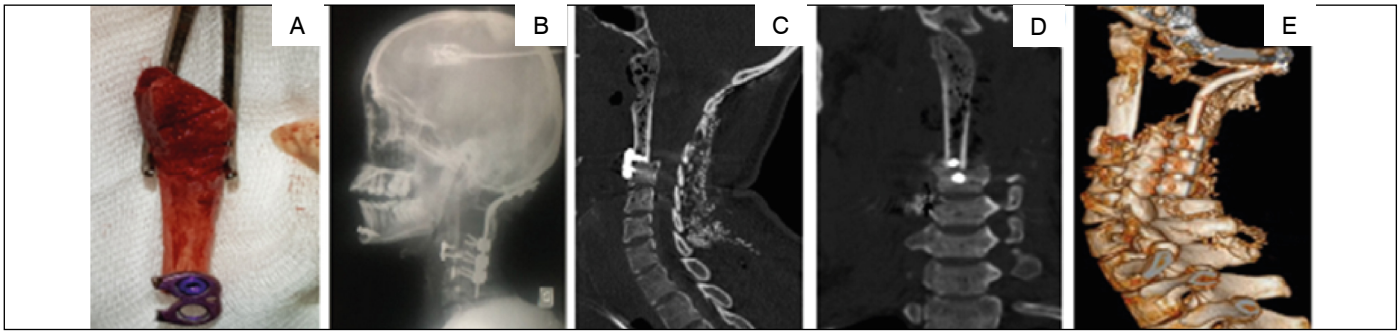

Figure 9. (case 4): A – Fibular allograft. B, C and D – X-ray and CT scan showing anterior CVJ reconstruction. E – 3D CT scan.

Table 1. Operative technique and complications.

	Diagnosis	Approach	Anterior Reconstruction	Posterior Reconstruction	Complications
1	Congenital Kyphosis with myelopathy	MLMG	Harms Cage with bone graft	OCF	Pharyngeal dehiscence + epidural abscess +hematoma
2	Aneurismal Bone Cyst	MLMG	Harms Cage with bone graft	OCF	-
3	Chordoma	MLMG + Anterolateral retropharyngeal*	Harms Cage with bone graft	Extension of posterior cervical fusion	velopharyngeal insufficiency
4	Giant Cell Tumor	MLMG + anterolateral retropharyngeal*	Fibular bone allograft	Extension of posterior cervical fusion**	velopharyngeal insufficiency

MLMG: median labiomandibular glossotomy, OCF: occipitocervical-fusion. *second surgery due to recurrence of the tumor. **Extension of previous posterior cervical fusion.

the transmaxillary approach, which allows the surgeon to access intra- or extradural lesions located between the clivus and C2.[27,33] However, this approach was unsuitable for our patients because the tumor had invaded the body of C2, C3 and extended to C4. The third surgical option for accessing the upper cervical region is the high cervical retropharyngeal approach, which was used in our cases 3 and 4 due to tumor recurrence. The disadvantages of this approach, as a first option, are the awkward trajectory, the restricted depth of exposure, and lack of the midline access, which was necessary for complete tumor resection. As our patient had undergone previous neck fusion, neck extension and rotation were not possible and none of these three main techniques was suitable.[32,34]

We choose the extended transoral transmandibular approach as a primary option because it provided a direct view of the clivus and C3 – C4 caudally[35] and a wider surgical field. The midline approach provided greater exposure without any significant damage to muscles, important blood vessels or nerves. Indications for the use of MLMG to increase exposure of the CVJ and upper cervical

vertebrae include an inter-incisor opening distance less than 2.5 - 3cm, and when access to C4 - C5 is required, as occurred in cases 3 and 4.[36] Glossotomy is necessary when the lesion extends down to C2 or below.[37]

The main advantages of MLMG are that it enables direct access to the ventral spinal pathology, with the extended head position and an avascular plane through the median pharyngeal raphe. This approach provides a wider surgical field in both the transverse and sagittal dimensions. As described by Arbit and Patterson, the cosmetic deformity and functional loss are minimal, despite the seemingly radical incision.[22] The disadvantages include facial scaring, oral and velopalatine incompetence, dysphagia, malocclusion, limited tongue mobility and sensation, and complications of tracheostomy.[23] In our series, we had two cases of phonation disorder and no complications of tracheostomy.

Oral contamination of the wound theoretically carries an increased risk of infection. In a study of 72 patients undergoing a transoral transpalatopharyngeal procedure, only one patient developed an infectious complication, which resolved without sequelae after drainage.[38] The majority of infectious complications are localized in the pharyngeal wall and do not progress to meningitis.[39,40] One of our four patients (case 1) had superficial infection on the subcutaneous tissue of the lower lip and developed an epidural abscess after an MLMG revision procedure. Some authors recommend empiric prophylactic antibiotics.[40-42] We made this recommendation for all our patients. Other authors indicate that preoperative throat cultures should be used to aid the choice of prophylactic antibiotics.[22]

We had no case of cerebrospinal fluid (CSF) leakage or meningitis as was reported by Menezes[36] in his series of 280 children aged under 16 years submitted to a transoral approach to the pharyngeal wall. We had two cases of dural lesion with CSF fistula, which was treated intraoperatively with primary repair.

A pharyngeal wound dehiscence is a rare complication, reported in 0.7% of cases.[43] Case 1 of our series had this later complication, and the patient was re-operated, with a satisfactory postoperative result.

Velopharyngeal insufficiency (VPI) typically occurs 4 to 6 months after surgery.[36] Authors have cited soft palate division as a significant risk for VPI, supporting the need for meticulous closure of the palatal defect. We had two temporary VPI episodes in cases 3 and 4, who needed the division of the soft palate in order to obtain better exposure of the superior limit of the tumor.

The limitations encountered for cervical spine chordomas are the result of involvement of the dura, nerve roots and vertebral arteries.[44,45] The duramater was infiltrated by the tumor in the chordoma case, and closure with fascia lata and artificial duramater was needed. In the last case, the behavior of the lesion (GCT) was aggressive; the posterior wall of the pharynx was infiltrated and both carotid arteries were encased, making en bloc resection impossible. Some authors recommend cerebral angiogram and temporary balloon occlusion test as part of the preoperative workup in patients with vertebral artery involvement, to determine the feasibility of vessel sacrifice to achieve en bloc resection[46] or perform intralesional resection, as we did in our cases.

Instability after resection of C1, C2 and C3 should be corrected. Reconstructions of the anterior column is mandatory. Anterior cage mesh filled with autologous bone graft was used in cases 1, 2 and 3. In the last case we used autologous fibula. The occipitocervical fusion is morbid because of the functional limitations that it places by greatly decreasing spinal mobility.[47] We decided to perform occipitocervical fusion in all cases to provide sufficient bio-mechanical support.

CONCLUSION

The Median Labiomandibular Glossotomy approach is useful for treating many different CVJ pathologies, including tumors and congenital abnormalities. This approach provides excellent and safe exposure of the craniocervical junction and upper cervical spine for decompression and reconstruction procedures, with few complications, making it acceptable.

All authors declare no potential conflict of interest related to this article.

CONTRIBUTION OF THE AUTHORS: Each authors made significant individual contributions to this manuscript, through bibliographic review, writing, revision and performing the surgeries: JDSS, LECTS, FGSS, RHT, AGCB.

REFERENCES

1. Southwick WO, Robson RA. Surgical Approaches to the Vertebral Bodies in the Cervical & lumbar Regions. J Bone Joint Surg. 1957;39-A(3):631– 44.
2. Stevenson AC, Sidney RJ, Perkins RK, Adams JE. A transclival Approach to the Ventral Surface of the Brain Stem for Removal of a Clivus Chordoma. J Neurosurg. 1966;24(2):544-51.
3. Barrenechea IJ, Perin NI, Triana A, Lesser J, Constantino P, Sen C. Surgical Management of Chordomas of the Cervical Spine. J Neurosurg Spine. 2007;6(5):398-406. doi: 10.3171/spi.2007.6.5.398.
4. Hall JE, Denis F, Murray J. Exposure of the Upper Cervical Spine for Spinal Decompression by a Mandible and Tongue-Splitting Approach. Case Report. J Bone Join Surg Am. 1977;59(1):121-3.
5. Shaha A, Johnson R, Miller J, Milhorat T. Transoral-Transpharyngeal Approach to the Upper Cervical Vertebrae. Am J Surg. 1993;166(4):336-40. doi: 10.1016/s0002-9610(05)80327-7.
6. Roux PJ, Butlin HT, Spencer GS. Disease of the Tongue. Londres: Ponden, Cassel and Co; 1900.
7. Kocker T. Operative Surgery. Londres: Forgotten Books; 1911.
8. Trotter W. Operator for Malignant Diseases of the Pharynx. BR J Surg. 1929;16:485.
9. Wood BG, Sadar ES, Levine HL, Dohn DF, Tucker HM. Surgical Problems of the Base of the Skul: An Interdiscplinary Approach. Arch Otolaryngol. 1980;106(1):1-5. doi: 10.1001/archotol.1980.00790250003001.
10. Apuzzo MJL, Weiss MH, Heiden JS. Transoral Exposure of the Atlantoaxial Region. Neurosurgery. 1978;3(2):201-7. doi: 10.1227/00006123-197809000-00012.
11. Estridge MN, Smith RA. Transoral Fusion of Odontoid Fracture. J Neurosurg. 1967;27:462-5.
12. Fang HSY, Ong GB. Direct Anterior Approach to the Upper Cervical Spine. J Bone Joint Surg. 1962;44:1588-604.
13. Fang HSY, Ong GB, Hodgson AR. Anterior Spinal Fusion: The Operative Approaches. Clin Orthop Relat Res. 1964;35:16-33.
14. Greenberg AD, Scoville WB, Davey LM. Transoral decompression of Atlanto-axial Dislocation due to Odontoid Hypoplasia. J Neurosurg. 1968;28(3):266-9. doi: 10.3171/jns.1968.28.3.0266.
15. George KS, McGurk M. Wilfred Batten Lewis Trotter 1872-1939. Br J Oral Maxillofac Surg. 2005;43(6):500-4. doi: 10.1016/j.bjoms.2005.01.021.
16. Donald P. Surgery of the Base. Philadelphia: Lippincott-Raven; 1998.
17. Ammirati M, Bernardo A. Analytical Evolution of Complex Anterior Approaches to the Cranial Base: an Anatomic Study. Neurosurgery. 1998;43(6):1398-407. doi: 10.1097/00006123-199812000-00081.
18. Brookes JT, Smith RJH, Menezes AH, Smith MC. Median Labiomandibular Glossotomy Approach to the Craniocervical Region. Childs Nerv Syst. 2008;24(10):1195-201. doi: 10.1007/s00381-008-0609-5.
19. Crockard H, Essigman W et al. Surgical Treatment of Cervical Cord Compression in Rheumatoid Arthritis. Ann Rheum Dis. 1985;44(12):809–16. doi: 10.1136/ard.44.12.809.
20. Floman Y, Kaplan L, Elidan J, Umansky F. Transverse Ligament Rupture Andatlanto-axial Subluxation in Children. J Bone Jt Surg Br. 1991;73(4):640–3. doi: 10.1302/0301-620X.73B4.2071650.
21. Schmelzle R, Harms J. Craniocervical Junction -diseases, diagnostic application of imaging procedures, surgical technics. Fortschr Kiefer Gesichtschir. 1987;32:206-8.
22. Arbit E, Patterson RH Jr. Combined Transoral and Median Labiomandibular Glossotomy Approach to the Upper Cervical Spine. Neurosurgery. 1981;8(6):672–4. doi: 10.1227/00006123-198106000-00006.
23. Brookes JT, Smith RJ, Menezes AH, Smith MC. Median Labiomandibular Glossotomy Approach to the Craniocervical Region. Childs Nerv Syst. 2008;24(10):1195–201. doi: 10.1007/s00381-008-0609-5.

24. Delgado TE, Garrido E, Harwick RD. Labiomandibular, Transoral Approach to Chordomas in the Clivus and Upper Cervical Spine. Neurosurgery. 1981;8(6):675–9. doi: 10.1227/00006123-198106000-00007.
25. Moore LJ, Schwartz HC. Median Labiomandibular Glossotomy for Access to the Cervical Spine. J Oral Maxillofac Surg. 1985;43(11):909–12. doi: 10.1016/0278-2391(85)90234-4.
26. Wessberg GA, Hill SC, McBride KL. Median Labiomandibular Glossotomy. Int J Oral Surg. 1981;10(5):333–7. doi: 10.1016/s0300-9785(81)80030-0.
27. Crockard HA, Pozo JL, Ransford AO, Stevens JM, Kendall BE, Essingman WK. Transoral Decompression and Posterior Fusion for Rheumatoid Atlanto-axial Subluxation. J Bone Joint Surg Br. 1986;68(3):350-6. doi: 10.1302/0301-620X.68B3.3733795.
28. Fang HS, Ong GB. Direct Anterior Approach to the Upper Cervical Spine. J Bone Joint Surgery Am. 1962;44:1588-1604.
29. Hall JE, Denis F, Murray J. Exposure of the Upper Cervical Spine for Spinal Decompression by Mandible and Tongue Splitting Approach. Case report. J Bone Joint Surg Am. 1977;59(1):121-3.
30. Honma G, Murota K, Shiba R, Kondo H. Mandible and Tongue-splitting Approach for Giant Cell Tumor of Axis. Spine (Phila Pa 1973). 1989;14(11):1204-10. doi: 10.1097/00007632-198911000-00012.
31. Krespi YP, Har-El G. Surgery of the clivus and anterior cervical spine. Arch Otolaryngol Head Neck Surg. 1988;114(1):73-8. doi: 10.1001/archotol.1988.01860130077019.
32. Henn JS, Lee MC, Rhoton AL. Transoral Approach to the Craniocervical Junction and Upper Cervical Spine. In: Kim DH, Henn JS, Vaccaro AR, Dickman AC. Surgical Anatomy & Techniques to the Spine. Philadelphia: Sauders&Elsevier; 2006. p. 3-12.
33. Bhangoo RS, Crockard HA. Transmaxillary anterior decompressions in patients with severe basilar impression. Clin Orthop Relat Res. 1999;(359):115-25. doi: 10.1097/00003086-199902000-00012.
34. German JW, Hart BL, Benzel EC. Nonoperative Management of Vertical C2 Body Fractures. Neurosurgery. 2005;56(3):516-21. doi: 10.1227/01.neu.0000153908.53579.e4.
35. Ortega-Porcayo LA, Cabrera-Aldana EE, Arriada-Mendicoa N, Gómez-Amador JL, Granados--García M, Barges-Coll J. Operative technique for en bloc resection of upper cervical chordomas: Extended Transoral Transmandibular Approach and Multilevel Reconstruction. Asian Spine J. 2014;8(6):820-6. doi: 10.4184/asj.2014.8.6.820.
36. Menezes A. Complications of Surgery at the Craniovertebral Junction—Avoidance and Management. Pediatr Neurosurg. 1991-1992;17(5):254–66. doi: 10.1159/000120607.
37. Delgado TE, Garrido E, Harwick RD. Labiomandibular, transoral approach to chordomas in the clivus and upper cervical spine. Neurosurgery. 1981;8(6):675-9. doi: 10.1227/00006123-198106000-00007.
38. Menezes A, VanGilder J. Transoral–transpharyngeal Approach to the Anterior Craniocervical Junction. J Neurosurg. 1988;69(6):895–903. doi: 10.3171/jns.1988.69.6.0895.
39. Menezes AH, Foltz GD. Transoral approach to the ventral craniocervical border. Operative Techniques in Neurosurgery. 2005;8(3):150–7. doi: 10.1053/j.otns.2005.10.007.
40. Merwin G, Post J, Sypert GW. Transoral approach to the upper cervical spine. Laryngoscope. 1991;101(7 Pt 1):780–4. doi: 10.1288/00005537-199107000-00016.
41. Kingdom T, Nockels R, Kaplan MJ. Transoral-transpharyngeal approach to the craniocervical junction. Otolaryngol Head Neck Surg. 1995;113(4):393–400. doi: 10.1016/s0194-5998(95)70074-9.
42. Tuite G, Veres R, Crockard HA, Sell D. Pediatric transoral surgery: indications, complications, and long-term outcome. J Neurosurg. 1996,84(4):573–83. doi: 10.3171/jns.1996.84.4.0573.
43. De Almeida JR, Zanation AM, Snyderman CH, Carrau RL, Prevedello DM, Gardner PA, et al. Defining the nasopalatine line: the limit for endonasal surgery of the spine. Laryngoscope. 2009;119(2):239–44. doi: 10.1002/lary.20108.
44. Rhines LD, Fourney DR, Siadati A, Suk I, Gokaslan ZL. En Bloc resection of multilevel cervical chordoma with C-2 involvement. Case report and description of operative technique. J Neurosurg Spine. 2005;2(2):199- 205. doi: 10.3171/spi.2005.2.2.0199.
45. Barrenechea IJ, Perin NI, Triana A, Lesser J, Costantino P, Sen C. Surgical management of chordomas of the cervical spine. J Neurosurg Spine. 2007;6(5):398-406. doi: 10.3171/spi.2007.6.5.398.
46. Hsieh PC, Gallia GL, Sciubba DM, Bydon A, Marco RA, Rhines L, et al. En bloc excisions of chordomas in the cervical spine: Review of five consecutive cases with more than 4-year follow-up. Spine (Phila Pa 1976). 2011;36(24):E1581-7. doi: 10.1097/BRS.0b013e318211839c.
47. Jackson RJ, Gokaslan ZL. Occipitocervicothoracic fixation for spinal instability in patients with neoplastic processes. J Neurosurg. 1999;91(1 Suppl):81-9. doi: 10.3171/spi.1999.91.1.0081.