Article published online: 2022-07-11

Evaluation of Screws Positioning in Latarjet Surgery: Is There a Correlation between Parallelism to Glenoid and Radiographic Complications?*

Avaliação do posicionamento dos parafusos na cirurgia de Latarjet: Existe correlação entre paralelismo à glenoide e complicações radiográficas?

Eduardo Felipe Kin Ito Kawakami[1] Gabriel Paris de Godoy[2] Marcio T. Cohen[3] Andre Fukunishi Yamada[1,4] Geraldo R. Motta Filho[3] Benno Ejnisman[5] Paulo Santoro Belangero[5]

[1] Radiologist, Department of Imaging Diagnosis, Escola Paulista de Medicina, Universidade Federal de São Paulo (Unifesp), São Paulo, SP, Brazil
[2] Orthopedist and traumatologist of the Discipline of Sports Medicine - Shoulder and Elbow Group, Department of Orthopedics and Traumatology, Escola Paulista de Medicina, Universidade Federal de São Paulo (Unifesp), São Paulo, SP, Brazil
[3] Orthopedist and traumatologist, Shoulder and Elbow Group, Instituto Nacional de Traumatologia e Ortopedia, Rio de Janeiro, RJ, Brazil
[4] Radiologist at Hospital do Coração (HCOR), São Paulo, SP, Brazil
[5] Head of the Discipline of Sports Medicine - Shoulder and Elbow Group, Department of Orthopedics and Traumatology, Escola Paulista de Medicina, Universidade Federal de São Paulo (Unifesp), São Paulo, SP, Brazil

Address for correspondence Gabriel Paris de Godoy, MD, Discipline of Sports Medicine, Department of Orthopedics and Traumatology, Paulista School of Medicine, Federal University of São Paulo (Unifesp), São Paulo, SP, Brazil, R. Estado de Israel, 713 - Vila Clementino - 04022-001, São Paulo, SP, Brazil (e-mail: gabrielparis80@gmail.com).

Rev Bras Ortop 2023;58(6):e876–e884.

Abstract

Objective To evaluate whether the parallelism of screws with glenoid in Latarjet surgery interferes in the positioning of the graft and to verify the reproducibility of a method of measuring screws positioning.

Methods Retrospective, multicenter study, of patients with anterior shoulder instability submitted to modified Latarjet surgery and at least one year of postoperative follow-up. Two radiologists analyzed the postoperative tomographic images, acquired in a database, to evaluate the positioning of screws and radiographic complications.

Results We evaluated 34 patients, aged between 21 and 60 years, one of them with bilateral shoulder involvement, totaling 35 shoulders evaluated. The tomographic evaluation of the inclination angles of the screws showed no difference between the

Keywords
- bone screws
- shoulder dislocation/surgery
- shoulder joint/surgery
- computed tomography x-ray

* *Multicenter work, carried out in the premises of the discipline of sports medicine – shoulder and elbow group of the department of orthopedics and traumatology, Universidade Federal de São Paulo, São Paulo, SP, Brazil and INTO (Instituto Nacional de Traumatologia e Ortopedia), Shoulder and Elbow Group, Rio de Janeiro – RJ, Brazil*

received
March 8, 2022
accepted after revision
May 19, 2022
article published online
July 11, 2022

DOI https://doi.org/10.1055/s-0042-1751110.
ISSN 0102-3616.

© 2022. Sociedade Brasileira de Ortopedia e Traumatologia. All rights reserved.
This is an open access article published by Thieme under the terms of the Creative Commons Attribution-NonDerivative-NonCommercial-License, permitting copying and reproduction so long as the original work is given appropriate credit. Contents may not be used for commercial purposes, or adapted, remixed, transformed or built upon. (https://creativecommons.org/licenses/by-nc-nd/4.0/)
Thieme Revinter Publicações Ltda., Rua do Matoso 170, Rio de Janeiro, RJ, CEP 20270-135, Brazil

observers. There was intra- and interobserver agreement to evaluate the following surgical parameters: graft position, presence or not of radiographic complications.

Conclusion The technique described for measuring the parallelism of screws in Latarjet surgery presented a very good and excellent intra-observer agreement, respectively. Screw parallelism with glenoid is recommended; however, it is not a mandatory and unique condition to avoid radiographic complications.

Resumo

Objetivo Avaliar se o paralelismo dos parafusos com a glenoide na cirurgia de Latarjet interfere no posicionamento do enxerto e verificar a reprodutibilidade de um método de mensuração da posição dos parafusos.

Métodos Estudo retrospectivo, multicêntrico, de pacientes com instabilidade anterior do ombro submetidos à cirurgia de Latarjet modificada e no mínimo 1 ano de seguimento pós-operatório. Dois médicos radiologistas analisaram as imagens tomográficas pós-operatórias, adquiridas em um banco de dados, para avaliação do posicionamento dos parafusos e das complicações radiográficas.

Resultados Foram avaliados 34 pacientes, com idades entre 21 e 60 anos, sendo que um deles tinha acometimento bilateral dos ombros, totalizando 35 ombros avaliados. A avaliação tomográfica dos ângulos de inclinação dos parafusos não apresentou diferença entre os observadores. Houve concordância intra e interobservador para avaliação dos seguintes parâmetros cirúrgicos: posição do enxerto, presença ou não de complicações radiográficas.

Conclusão A técnica descrita para mensuração do paralelismo dos parafusos na cirurgia de Latarjet apresentou uma concordância intra e inter observador muito boa e excelente, respectivamente. O paralelismo do parafuso com a glenoide é recomendado; no entanto, não é condição obrigatória e única para se evitar as complicações radiográficas.

Palavras-chave
- articulação do ombro/cirurgia
- luxação do ombro/cirurgia
- parafusos ósseos
- tomografia computadorizada por raios X

Introduction

Recurrent shoulder dislocation results from lesions of the stabilizing joint structures, active or passive, resulting from traumatic events or not. It is more frequent in young male adults, in whom the possibility of recurrent instability reaches up to 90%.[1,2] Treatment is preferably surgical, with Latarjet and its modifications being some of the used techniques.[2] These are based on the use of bone blocks with good safety and excellent results mainly in cases with erosion of the anterior edge of the glenoid.[3–5]

In Latarjet surgery, the positioning of the graft and screws is essential for the success of the procedure.[2,6–10] The lateralized graft favors the appearance of early osteoarthritis and limits the range of motion. When mediated, it predisposes to degenerative changes and varying degrees of instability. Therefore, the understanding of each step of this procedure minimizes the risks of poor positioning of the screws used for graft fixation. Even with appropriate technique, other complications such as non-consolidation or resorption of the graft may occur.[7,8,11,12]

The evaluation of graft and screws positioning in the postoperative period by computed tomography (CT) images can help in understanding complications. However, there is a lack of consistent data from a reproducible evaluation of the position of the screws and their inter-relationships with the postsurgical results.

The aim of this study was to evaluate whether the parallelism of the screws with the glenoid in modified Latarjet surgery interferes with the positioning of the graft and, at the same time, to verify the reproducibility of a method for evaluating the position of the screws in relation to the glenoid.

Methodology

This is a retrospective, multicenter study with recruitment of patients from two centers specialized in shoulder and elbow surgery. The procedure was performed by surgeons with more than 5 years of training in shoulder and elbow surgery.

Approved by the ethics and research committee with CAAE number: 89698818.5.0000.5505.

Study Population

Patients diagnosed with recurrent anterior shoulder instability submitted to surgical treatment using the modified Latarjet technique and who underwent outpatient clinical and radiographic postop follow-up with a minimum follow-up time of 1 year were included. The indication of the Latarjet procedure was based on clinical data such as physical/sports activity, presence of bone defects of the glenoid or humeral, and, in cases of recurrence after Bankart repair, by arthroscopic technique.

 © 2022. Sociedade Brasileira de Ortopedia e Traumatologia. All rights reserved.

Patients submitted to treatment of shoulder instability by other techniques, surgeries for the treatment of other shoulder disorders, such as rotator cuff repair, with previous diagnosis of arthrosis, or who did not undergo CT 1 year postoperatively were excluded.

Surgical Technique

The patients were in beach chair position, under general anesthesia and brachial plexus block. Access was made in the deltopectoral interval with anterior skin incision of 5 to 8 centimeters (cm). Dissection, exposure, and osteotomy of the coracoid process were performed, preserving the joint tendon after the release of the pectoralis minor and the coracoacromial ligament. The subscapularis muscle was longitudinally opened between the upper and lower two thirds. The joint capsule was opened vertically near the glenoid. After preparation of the anterior rim of the glenoid, the bone graft was fixed vertically, with 2 screws of 3.5 to 4 mm in diameter. The position of the graft and screw was verified with fluoroscopy after fixation. As described in the modified Latarjet technique, no coracoacromial ligament repair was made in the joint capsule.[13,14]

Postsurgical Tomographic Evaluation

Two radiologists, one with 7 years (named observer 1) and the other with 1 year (named observer 2) of experience in musculoskeletal radiology, performed 2 evaluations, independently, with an interval of 2 weeks of tomographic images for analysis of screws positioning and radiographic complications after surgery. Horos for Mac software (Nimble Co, Annapolis, MD USA.) was used for image analysis. The tomograph used was the 64-channel Philips Brilliance (Philips Health, Best, Netherlands), and the patients were positioned in horizontal supine position.

Evaluation of Screws Parallelism and Alpha Angle

The evaluation of the positioning of each of the bone graft fixation screws was performed by measuring the angle formed between the largest longitudinal axis of the screw and the articular surface of the adjacent glenoid, called alpha angle. For this, we chose the tomographic cut in which the screw was visualized in its entire longitudinal length in the true sagittal plane of the glenoid (►**Figs. 1** and **2**). Thus, the image of the entire length of the screw located in the oblique axial plane was defined, because the graft fixation screws present anterior craniocaudal inclination due to the surgical technique that positions the bone graft in the margin of the anteroinferior glenoid (►**Fig. 3**). The top screw is screw 1, and the bottom one is screw 2.

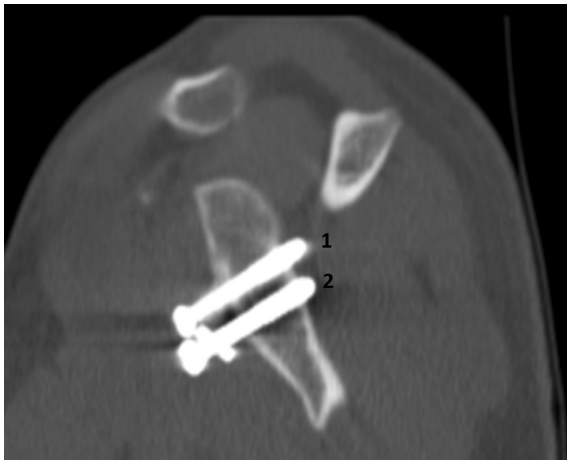

Fig. 1 Tomographic reconstruction in the true sagittal plane of the glenoid with visualization of screws 1 (upper) and 2 (inferior) graft fixation.

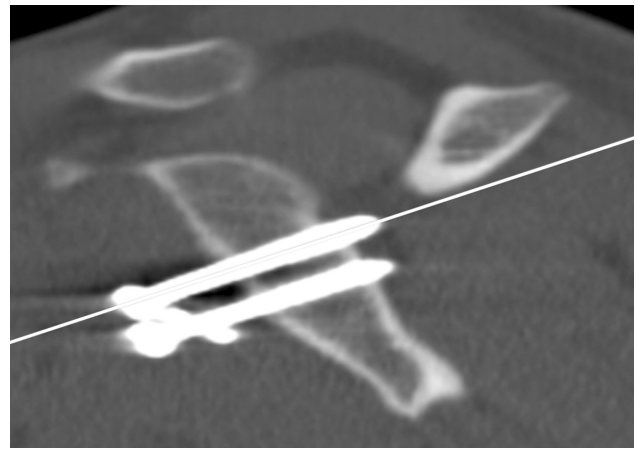

Fig. 2 Sagittal section of orientation for reconstruction of the best axial cut of screw 1 (upper) on the largest longitudinal axis.

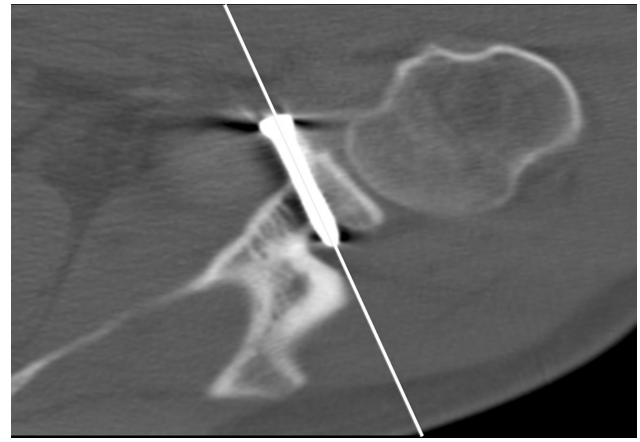

Fig. 3 Axial cut of the upper screw.

The positioning of the bone graft in relation to the articular surface of the glenoid was classified according to the distance between the anterior surface of the graft and the glenoid joint surface's plan, being classified as:

- Medial: when the distance was greater than 5.0 mm medially to the joint surface (►**Fig. 4**).
- Lateral: when the distance was greater than 1.0 mm laterally to the joint surface (►**Fig. 5**).
- Neutral: when the distance was between 5.0 mm medial to 1.0 mm lateral in relation to the joint surface (►**Fig. 6**).

 © 2022. Sociedade Brasileira de Ortopedia e Traumatologia. All rights reserved.

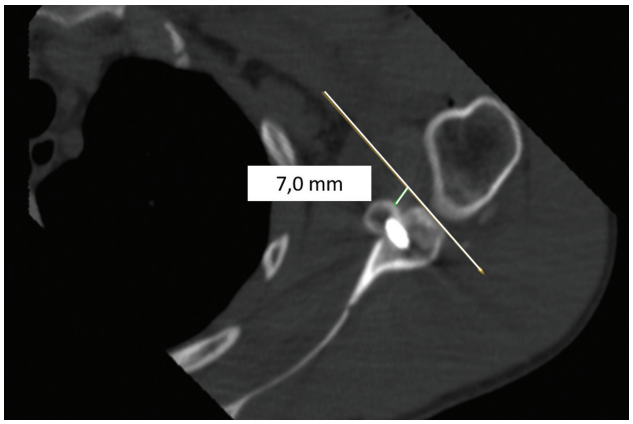

Fig. 4 Medial position screw (7 mm medial to joint surface).

From the axial cut of the CT, visualizing the upper screw, two reference lines were drawn: the largest longitudinal axis of the screw and another of the joint surface of the glenoid, forming the alpha angle, measured in degrees (►**Fig. 7**).

Radiographic Complications

The analysis of postsurgical complications on CT images used the following definitions:

- Pseudoarthrosis: cases in which there were no signs of bone graft consolidation near the glenoid. We consider as signs of consolidation on CT images the presence of bone bridges, fusion of bone corticals close between fragments and bone callus formation (►**Fig. 8**) in any tomographic section with a minimum of 6 months
- Osteolysis: cases in which hypoattenuating (radiolucent) foci were evidenced in the cortical and bone marrow of the graft; or when the graft showed a reduction in its dimensions, signs of resorption, when the graft was not visualized, leaving only the screw head near the joint surface (►**Fig. 9**).

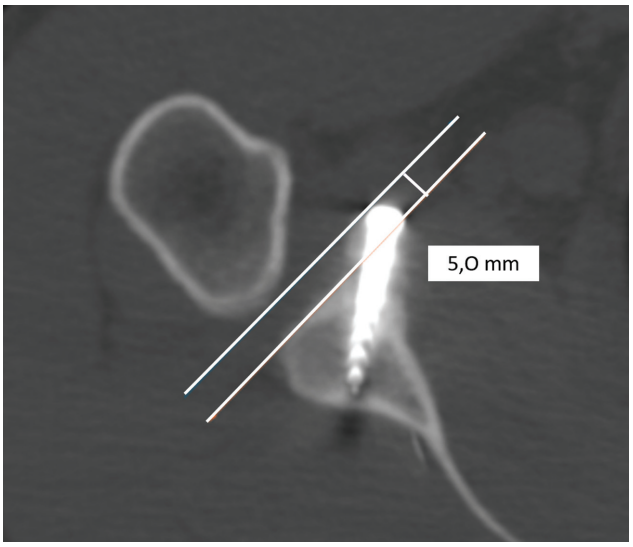

Fig. 5 Lateral position screw (5 mm lateral to joint surface).

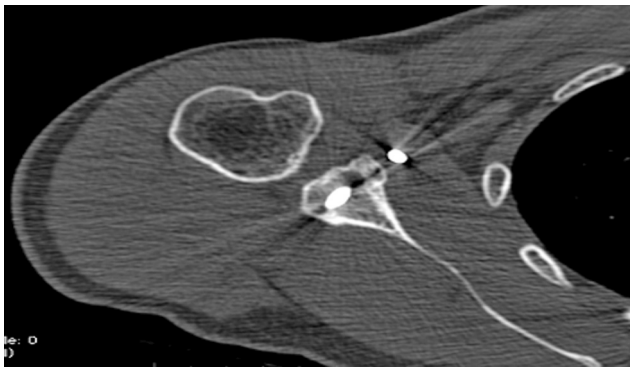

Fig. 6 Neutral position screw (at joint surface level).

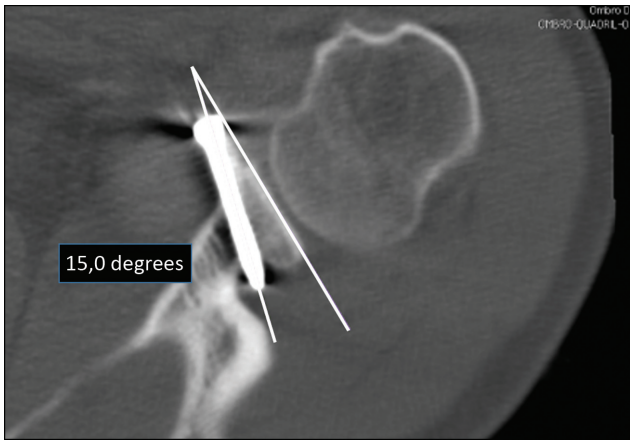

Fig. 7 Alpha angle formation measured in degrees.

Statistical analysis

Statistical inference analysis used the IBM SPSS Statistics for Windows, Version 20.0 (IBM Corp. Armonk, NY, USA), Minitab 16 (Minitab Inc, State College, PA, USA), and Microsoft

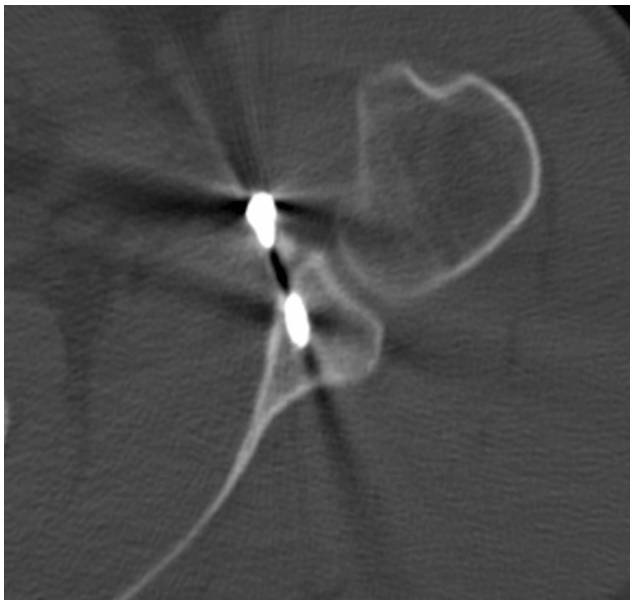

Fig. 8 Computed tomography cut showing pseudoarthrosis.

 © 2022. Sociedade Brasileira de Ortopedia e Traumatologia. All rights reserved.

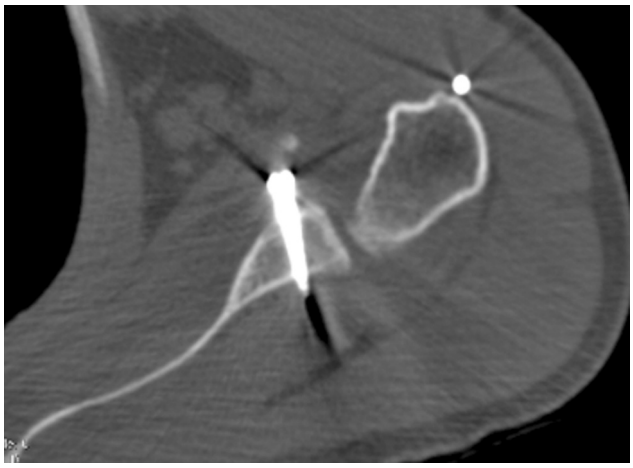

Fig. 9 Computed tomography cut showing osteolysis.

Excel Office 2010 (Microsoft Corp. Redmond, WA, USA) software. A significance level of 0.05 (5%) was defined, with a 95% confidence interval. The quantitative variables of main outcome were tested for normality using the Kolmogorov-Smirnov test; the alpha angle was evaluated using the paired Student t-test. Kappa coefficient was used to evaluate the intra and interobserver agreement of the alpha angle values, bone graft positioning and presence/absence of postsurgical radiographic complications. Landis and Kock[15] proposed the following correlation between kappa coefficient values: $< 0.00 =$ very bad, 0.00–0.20 = bad, 0.21–0.40= reasonable, 0.41–0.60 = good, 0.61–0.80 = very good and above 0.81 = excellent.

Then, results obtained by observer 1 were submitted to statistical analysis to evaluate the following relationships between variables and their associations through the Chi-squared and analysis of variance (ANOVA) tests:

1. Alpha angle and positioning of the bone graft.
2. Alpha angle and presence/absence of postsurgical complications.
3. Positioning of the bone graft and presence/absence of postsurgical complications.
4. Cut-off value of the alpha angle for the presence of postsurgical complications.

For the analysis of these relationships involving the alpha angle, there was grouping of the values of the measurements into 2 ranges, one from 0 to 15 degrees and another equal to or greater than 16 degrees. These ranges of values were defined from the conclusion of two studies by Hovelius et al., according to which the angulation of the screw should be less than 15 degrees for adequate position of the coracoid and stable fixation.[11,16]

Results

Thirty-four patients were included, one with bilateral involvement, totaling 35 shoulders, 22 right and 13 left. Four were women and 30 men, aged between 21 and 60 years old. The general results obtained in the evaluation of bone graft positioning in relation to the glenoid and complications are illustrated in ►**Table 1**.

The positioning of the bone graft in relation to the glenoid joint surface was classified as:

- Medial: when the distance was greater than 5.0 mm medially to the joint surface.
- Articular: when the distance was greater than 1.0 mm laterally to the joint surface.
- Neutral: when the distance was between 5.0 mm medial to 1.0 mm lateral in relation to the joint surface.

The alpha angles obtained are described in ►**Table 2**. There was no statistically significant difference between the two observers, so the observers similarly evaluated the deviations.

Regarding the evaluation of the relationship between the position of the bone graft and the alpha angle ranges for screw 1 ($p = 0.341$), it was observed that of the 18 patients with alpha angle between 0 and 15 degrees, 6 of the grafts (33.3%) were in a medial position, 11 (61.1%) in neutral position, 1 of the grafts (5.6%) in joint position. Of the 17 patients with an alpha angle greater than 16 degrees, 5 of the grafts (29.4%) were obtained in a medial position, 10 of

Table 1 Positioning of the bone graft in relation to the glenoid and complications

Bone graft positioning			
Graft	**Observer 1**	**Observer 2**	**Interobserver agreement (Kappa)**
Medial	12	13	0.86
Neutral	20	19	
Articular	3	3	
Intraobserver agreement (Kappa)	0.92	0.88	
Complications			
Graft	**Observer 1**	**Observer 2**	**Interobserver agreement (Kappa)**
No complications	21	27	0.77
With complications	14	8	
Intraobserver agreement (Kappa)	0.9	0.88	

 © 2022. Sociedade Brasileira de Ortopedia e Traumatologia. All rights reserved.

Table 2 Alpha angles*

Observer 1	0–15	> 16	Average (+-SD)	Min; Max	N	*P*-value
Screw 1	18	17	16.7(±9.6)	0; 44	35	0.069
Screw 2	18	17	19.4 (±12.1)	2; 46	35	0.107
Observer 2	**0–15**	**> 16**	**Average**	**Min; Max**	**N**	***P*-value**
Screw 1	19	16	18.2 (±11.4)	2; 55	35	0.069
Screw 2	15	20	20.9 (±14)	1; 61	35	0.107

*Angle between the largest longitudinal axis of the screw and the adjacent glenoidal joint surface

Table 3 Ratio of alpha angle values mean with the position of the graft in the upper and lower screws

Position		Average	Median	Standard deviation	Min	Max	N	*P*-value
Screw 1	Articular	26.3	28	8.6	17	34	3	0.112
	Medial	11.8	11	2.5	10	16	5	
	Neutral	16.5	14.5	9.9	0	44	28	
Screw 2	Articular	35.3	39	7.2	27	40	3	0.052
	Medial	17.8	14	14.2	3	41	5	
	Neutral	17.9	18	11.1	2	46	27	

the grafts (58.8%) in a neutral position, and 2 (11.8%) in joint position. For screw 2 ($p = 0.242$), of the 18 patients with an alpha angle between 0 and 15 degrees, the positions of the grafts were: 7 of the grafts (38.8%) in the medial position; 11 (61.2%) in neutral position, and none of the grafts in joint position. Of the 17 patients with values greater than 16 degrees, 4 of the grafts (23.5%) were in a medial position, 10 (58.8%) in neutral position, and 3 of the grafts (17.7%) in joint position. ►**Table 3** illustrates the relationship between graft position and screw angle but using the mean value of the measurements.

In both evaluations, there was no statistical significance between the angle and the positioning of the graft. However, in screw 2, it tended to be significant when the angle was evaluated by mean angle values, highlighting the three cases of lateral grafts with higher mean value of alpha angle. The relationship between angle values and the presence of postsurgical complications is illustrated in ►**Table 4**.

There was no statistical significance between the angle and the presence of complications. However, there is a tendency to ratio the angle of screws 1 and 2 to the presence or not of complications, noting that the lower the alpha angle, the lower the number of complications. ►**Table 5** illustrates the evaluation between the presence of complications and screw angle.

In both screws, we observed that the mean value of the angles measured is higher in cases in which complications were evidenced, with statistical significance. The relationship between complications and graft positioning is illustrated in ►**Table 6**.

There was statistical significance in the relationship between graft positioning and the presence of complications, with $p < 0.03$. Using the receiver operating characteristic (ROC) curve to obtain some cutoff value of the screw angle related to the complication, there was only statistical significance for screw 2, and the value obtained was of 11 degrees, with a sensitivity of 93.8% and specificity of 47.4% to predict a patient with postsurgical complications.

Discussion

When describing his surgical technique, Latarjet recommended that the bone graft fixation screw should be parallel to the joint surface to improve bone containment, avoiding

Table 4 Relationship of alpha angle values with the presence or absence of complications in the upper and lower screws

Complication		No		Yes		Total		*P*-value
		N	%	N	%	N	%	
Screw 1	0–15	11	61.2	7	38.8	18	51.4	0.084
	> 16	9	52.9	8	47.1	17	48.6	
Screw 2	From 0–15	11	61.2	7	38.8	18	51.4	0.079
	> 16	10	58.8	7	41.2	17	48.6	

 © 2022. Sociedade Brasileira de Ortopedia e Traumatologia. All rights reserved.

Table 5 Ratio of alpha angle values mean with the presence or absence of complications in the upper and lower screws

Complication		Average	Median	Standard deviation	Min	Max	N	*P*-value
Screw 1	No	13.6	12	7.9	0	27	19	0.043
	Yes	20.1	17	10.4	8	44	17	
Screw 2	No	14.2	13	9.1	2	34	19	0.004
	Yes	25.6	19	12.5	8	46	16	

Table 6 Relationship of presence or absence of complications with graft position

Complication		No		Yes		Total		*P*-value
		N	%	N	%	N	%	
Position	Articular	0	0.0	3	21.5	3	8.5	0.030
	Medial	7	33.3	5	35.7	12	34.4	
	Neutral	14	66.7	6	42.8	20	57.1	

complications and treatment failures.[17,18] Despite these recommendations in relation to the surgical technique, the literature is scarce regarding precise recommendations for screw parallelism or if there is any degree of acceptable angulation to obtain favorable results in the surgical treatment of recurrent shoulder dislocation.

The proposal of a method for evaluating the position of the graft and the alpha angle by means of tomography was initially validated by Kraus et al.[10] In 2016, these authors conducted a study with 27 patients who evaluated, over 2 years, the reproducibility to classify the position of the graft after the Latarjet procedure, as lateral, neutral, or medial, by CT. This study showed positive results regarding the reproducibility of the method, showing that the CT evaluation accurately described the positioning of the graft.[10]

In our study, the intra and interobserver agreement for the analysis of graft positioning and for the measurement of the inclination of the fixation screw with the glenoid joint surface was statistically positive. The measurement of the alpha angle by the two observers showed no statistical difference, corroborating the reproducibility of the method in this evaluation. Some degree of difficulty may occur in obtaining the best tomographic cut by tilting the scapula, as Barth et al.[19] concluded in their study in 2017.

The surgical procedure of bone block is the treatment of choice in cases of recurrent dislocation of the shoulder in which there is bone loss.[4,10,20,21] The procedure aims to restore the stability of the shoulder joint, and its success depends on several technical factors.[2,6,9,17] Among the main ones, the position of the coracoid graft ideally below the glenoid equator and parallel to the glenoid joint surface, avoiding the minimum medial deviation of the graft and the inclination of the fixation screws in relation to the joint line, stand out.[18,22]

In addition to the classical Latarjet technique or its modifications, there is the possibility of performing arthroscopic surgery.[7,16,17,23] Both forms present good results in functional and postoperative pain scores.[24] In a systematic review, Horner directly compared the open Latarjet technique with the arthroscopic approach and concluded that three out of five studies did not find significant differences in relation to graft positioning[20,25–27]; and two out of three studies found no statistical difference in the angle of the screws.[25,27,28] Still, there are studies that demonstrate that graft positioning in arthroscopic surgery can be challenging, as well as the proper angle of the screws.[29,30]

Our results demonstrate a relationship between the alpha angle and the presence of radiographic complications. In both screws, we observed that the mean value of the angles measured is higher in cases in which complications were evidenced, with statistical significance. These results are in line with previous studies that recommend a maximum inclination of 15 degrees of the fixation screws in relation to the glenoid joint line.[9,11,16,22]

Limitations

Osteoarthritis was not included in the analysis of complications due to the time for the onset of this alteration. Another limitation of the study was that, because it was a strictly radiological study, there was no collection of clinical and epidemiological data, and occurrence of postoperative recurrence. Furthermore, this study did not analyze the dimensions of the bone defect secondary to instability, since this study used CT scans performed postoperatively, which may be a bias to evaluate the bone resorption of the grafts.

Conclusion

The technique described to measure the parallelism of the screws in the Latarjet surgery presented a very good and excellent intra and interobserver agreement, respectively. We found that screw parallelism with glenoid is recommended; however, it is not a mandatory and unique condition to avoid radiological complications.

 © 2022. Sociedade Brasileira de Ortopedia e Traumatologia. All rights reserved.

There is a tendency of the relationship between the position of the graft and the inclination of the lower screw when measured by the mean of the values obtained from the alpha angle. Lateral grafts presented higher mean value compared to neutral and mediated grafts. We observed that the mean value of the inclination angle of screws 1 and 2 is higher in cases that presented radiological complications. There is also a significant relationship between graft position and the presence of radiological complications.

Financial Support
The authors state that they have not received financial support from public, commercial, or non-profit sources.

Conflict of Interests
The authors have no conflict of interests to declare.

Authors' Contributions
Each author contributed individually and significantly to the development of this article. E. F. K. I. K.: conception, design and development of methodology, analysis, and interpretation of radiological data, writing and approval of the final manuscript. G. P. G.: conception, design and development of methodology, analysis and interpretation of data, surgery of cases performed at Universidade Federal de São Paulo (UNIFESP), writing and approval of the final manuscript. M. T. C.: development of the methodology, orthopedic surgery of cases performed at Instituto Nacional de Traumatologia e Ortopedia (INTO), review and approval of the final manuscript. A. F. Y.: conception, design, and development of methodology, analysis and interpretation of radiological data, approval of the final manuscript. G. R. M. T.: conception, design and development of the methodology, orthopedic surgery of cases performed at INTO, review and approval of the final manuscript. B. E.: conception, design and development of methodology, analysis and interpretation of data, surgery of cases performed at UNIFESP, approval of the final manuscript. P. S. B.: conception, design and development of methodology, analysis and interpretation of data, surgery of cases performed at UNIFESP, writing and approval of the final manuscript.

References

1 Ruci V, Duni A, Cake A, Ruci D, Ruci J. Bristow-Latarjet Technique: Still a Very Successful Surgery for Anterior Glenohumeral Instability - A Forty Year One Clinic Experience. Open Access Maced J Med Sci 2015;3(02):310–314
2 Matthes G, Horvath V, Seifert J, et al. Oldie but goldie: Bristow-Latarjet procedure for anterior shoulder instability. J Orthop Surg (Hong Kong) 2007;15(01):4–8
3 Godinho GG, Monteiro PCV. Surgical treatment of anterior shoulder instability using the Didier-Patte technique. Rev Bras Ortop 1993;28(09):640–644
4 Ikemoto RY, Murachovisky J, Nascimento LGP, et al. Results from latarjet surgery for treating traumatic anterior shoulder instability associated with bone erosion in the glenoid cavity, after minimum follow-up of one year. Rev Bras Ortop 2015;46(05):553–560
5 Ferreira AA, Malavolta EA, Gracitelli MEC, et al. Treatment of recurrent anterior shoulder dislocation with Bristol-Latarjet procedure. Acta Ortop Bras 2021;29(01):39–44
6 Kany J, Flamand O, Grimberg J, et al. Arthroscopic Latarjet procedure: is optimal positioning of the bone block and screws possible? A prospective computed tomography scan analysis. J Shoulder Elbow Surg 2016;25(01):69–77
7 Hovelius LK, Sandström BC, Rösmark DL, Saebö M, Sundgren KH, Malmqvist BG. Long-term results with the Bankart and Bristow-Latarjet procedures: recurrent shoulder instability and arthropathy. J Shoulder Elbow Surg 2001;10(05): 445–452
8 Cassagnaud X, Maynou C, Mestdagh H. Résultats cliniques et tomodensitométriques d'une série continue de 106 butées de Latarjet-Patte au recul moyen de 7,5 ans. . [Clinical and computed tomography results of 106 Latarjet-Patte procedures at mean 7.5 year follow-up]Rev Chir Orthop Repar Appar Mot 2003;89(08): 683–692
9 Gracitelli MEC, Ferreira Neto AA, Benegas E, Malavolta EA, Sunada EE, Assunção JH. Procedimento de latarjet artroscópico: avaliação da segurança em cadáveres. Acta Ortop Bras 2013;21(03): 139–143
10 Kraus TM, Graveleau N, Bohu Y, Pansard E, Klouche S, Hardy P. Coracoid graft positioning in the Latarjet procedure. Knee Surg Sports Traumatol Arthrosc 2016;24(02):496–501
11 Hovelius L, Sandström B, Sundgren K, Saebö M One hundred eighteen Bristow-Latarjet repairs for recurrent anterior dislocation of the shoulder prospectively followed for fifteen years: study I–clinical results. J Shoulder Elbow Surg 2004;13(05): 509–516
12 Randelli P, Fossati C, Stoppani C, Evola FR, De Girolamo L. Open Latarjet versus arthroscopic Latarjet: clinical results and cost analysis. Knee Surg Sports Traumatol Arthrosc 2016;24(02): 526–532
13 Belangero PS, Lara PHS, Figueiredo EA, et al. Bristow versus Latarjet in high-demand athletes with anterior shoulder instability: a prospective randomized comparison. JSES Int 2021;5(02): 165–170
14 Lima EBS, Oses GL, Godoy GP, et al. Evaluation of Latarjet procedure in female athletes: a 3-year follow-up prospective cohort study. JSES Int 2022;6(03):343–348
15 Landis JR, Koch GG. The measurement of observer agreement for categorical data. Biometrics 1977;33(01):159–174
16 Hovelius L, Sandström B, Saebö M One hundred eighteen Bristow-Latarjet repairs for recurrent anterior dislocation of the shoulder prospectively followed for fifteen years: study II-the evolution of dislocation arthropathy. J Shoulder Elbow Surg 2006;15(03): 279–289
17 Lafosse L, Lejeune E, Bouchard A, Kakuda C, Gobezie R, Kochhar T. The arthroscopic Latarjet procedure for the treatment of anterior shoulder instability. Arthroscopy 2007;23(11):1242.e1–1242.e5
18 Latarjet M. [Technic of coracoid preglenoid arthroereisis in the treatment of recurrent dislocation of the shoulder]. Lyon Chir 1958;54(04):604–607
19 Barth J, Neyton L, Métais P, et al. Is the two-dimensional computed tomography scan analysis reliable for coracoid graft positioning in Latarjet procedures? J Shoulder Elbow Surg 2017;26(08):e237–e242
20 Horner NS, Moroz PA, Bhullar R, et al. Open versus arthroscopic Latarjet procedures for the treatment of shoulder instability: a systematic review of comparative studies. BMC Musculoskelet Disord 2018;19(01):255
21 Kordasiewicz B, Kicinski M, Małachowski K, Wieczorek J, Chaberek S, Pomianowski S. Comparative study of open and arthroscopic coracoid transfer for shoulder anterior instability (Latarjet)-computed tomography evaluation at a

 © 2022. Sociedade Brasileira de Ortopedia e Traumatologia. All rights reserved.

short term follow-up. Part II. Int Orthop 2018;42(05): 1119–1128
22 da Silva LA, da Costa Lima AG, Kautsky RM, Santos PD, Sella GV, Checchia SL. Avaliação dos resultados e das complicações em pacientes com instabilidade anterior de ombro tratados pela técnica de Latarjet. Rev Bras Ortop 2015;50(06):652–659
23 Castropil W, Schor B, Bitar A, Medina G, Ribas LH, Mendes C. Latarjet artroscópico: Descrição de técnica cirúrgica e resultados preliminares. Estudo de 30 primeiros casos. Rev Bras Ortop 2020; 55(02):208–214
24 Marion B, Klouche S, Deranlot J, Bauer T, Nourissat G, Hardy P. A Prospective Comparative Study of Arthroscopic Versus Mini-Open Latarjet Procedure With a Minimum 2-Year Follow-up. Arthroscopy 2017;33(02):269–277
25 Cohen M, Fonseca R, Gribel B, Galvão MV, Monteiro M, Motta Filho G. Incidência e fatores de risco das complicações da cirurgia de Latarjet. Rev Bras Ortop 2021;56(03):307–312
26 Mizuno N, Denard PJ, Raiss P, Melis B, Walch G. Long-term results of the Latarjet procedure for anterior instability of the shoulder. J Shoulder Elbow Surg 2014;23(11):1691–1699
27 Zhu Y, Jiang C, Song G. Arthroscopic Versus Open Latarjet in the Treatment of Recurrent Anterior Shoulder Dislocation With Marked Glenoid Bone Loss: A Prospective Comparative Study. Am J Sports Med 2017;45(07):1645–1653
28 Cunningham G, Benchouk S, Kherad O, Lädermann A. Comparison of arthroscopic and open Latarjet with a learning curve analysis. Knee Surg Sports Traumatol Arthrosc 2016;24(02):540–545
29 Russo A, Grasso A, Arrighi A, Pistorio A, Molfetta L. Accuracy of coracoid bone graft placement: open versus arthroscopic Latarjet. Joints 2017;5(02):85–88
30 Cautiero F, Russo R, Di Pietto F, Sabino G. Computerized tomographic assessment and clinical evaluation in shoulder instability treated with the Latarjet-Patte procedure using one screw and washer. Muscles Ligaments Tendons J 2017;7(01):26–33

 © 2022. Sociedade Brasileira de Ortopedia e Traumatologia. All rights reserved.