Rev Bras Ortop. 2013;48(3):272-277

ELSEVIER

RBO REVISTA BRASILEIRA DE ORTOPEDIA

www.rbo.org.br/

Original Article

Assessment of the results from arthroscopic surgical treatment of adhesive capsulitis

Marcio Cohen,[1,*] *Marcus Vinicius Amaral,*[1] *Bruno Lobo Brandão,*[1] *Marcelo Reis Pereira,*[2] *Martim Monteiro,*[3] *Geraldo da Rocha Motta Filho*[4]

[1]*Physician at the Shoulder and Elbow Surgical Center of Instituto Nacional de Traumatologia e Ortopedia (INTO), Rio de Janeiro, RJ, Brazil.*
[2]*Trainee at Shoulder and Elbow Surgical Center of INTO, Rio de Janeiro, RJ, Brazil.*
[3]*Head of the Shoulder and Elbow Surgical Center of INTO, Rio de Janeiro, RJ, Brazil.*
[4]*General Director of INTO, Rio de Janeiro, RJ, Brazil.*
Study carried out at Shoulder and Elbow Surgical Center of Instituto Nacional de Traumatologia e Ortopedia (INTO), Rio de Janeiro, RJ, Brazil.

ARTICLE INFO

Article history:
Received on April 20, 2012
Accepted on August 3, 2012

Keywords:
Bursitis/therapy
Shoulder pain
Arthroscopy
Treatment outcome

ABSTRACT

Objective: Describe the outcomes of patients with adhesive capsulitis treated with arthroscopic surgical procedure. *Methods:* Between January and September of 2009, 9 patients (10 cases) underwent arthroscopic surgical release. There were 4 male (one bilateral) and 5 female patients. Their mean age was 51 years (27-63). The time from onset of symptoms to the surgical procedure averaged 23.4 months (6-38). Preoperative assessment was based on the UCLA and Constant score. ROM was evaluated with one week and six months of surgery. *Results:* According to UCLA shoulder score ($p < 0.01$) it increased from 9.8 preoperatively (6-14) to 31.6 postoperatively (26-35) and the Constant ($p < 0.01$) from 20 (13-27) to 79.2 (66-91). ROM improved significantly, with mean passive elevation changing from 89° (80-100°) preoperatively to 150° postoperatively with one week and 153° with six months, mean passive external rotation changing from 12.5° (0-30°) preoperatively to 46° (one week) and 56° (six months) postoperatively, and passive internal rotation from L5 (T12-gluteus) to T11 (one week) and T9 (six months). There was not statistical significance of the duration of the disease and the postoperative result. *Conclusion:* This study shows that the surgical treatment of adhesive capsulitis with arthroscopic capsular release and manipulation appears to be a safe procedure that results in pain relief and functional gain.

© 2013 Sociedade Brasileira de Ortopedia e Traumatologia. Published by Elsevier Editora Ltda. Este é um artigo Open Access sob a licença de CC BY-NC-ND

Corresponding author: Avenida General San Martin 300/702. Rio de Janeiro, RJ, Brasil. CEP: 22441-010.
E-mail: mcohen5@hotmail.com

ISSN © 2013 Sociedade Brasileira de Ortopedia e Traumatologia Published by Elsevier Editora Ltda. Este é um artigo Open Access sob a licença de CC BY-NC-ND
doi: 10.1016/j.rboe.2012.08.003

Introduction

Adhesive capsulitis (AC) is a common disease that affects 3 to 5% of the general population, is more prevalent in females than in males (2:1), has an age of onset from 40 to 60 years of age, and causes pain and limitation in shoulder range of motion.[1,2] Several conditions can produce similar symptoms to adhesive capsulitis; the term "frozen shoulder", described by Codman[3], is a generalized term used to describe shoulder stiffness associated with pain. However, adhesive capsulitis should be considered a unique condition that is characterized by chronic inflammation of the joint capsule with consequent thickening, fibrosis and adhesion, which results in pain as well as active and passive shoulder stiffness. This term was first described by Neviaser[4] because of histopathological findings in the joint capsule.

The literature has established some systemic conditions, such as cardiovascular disease, thyroid dysfunction and diabetes mellitus, as risk factors for developing this disease. Diabetes mellitus is associated with severe cases with a poor prognosis.[1,2] However, most patients do not have an apparent underlying cause for the development of capsulitis, and their cases are therefore described as being idiopathic in origin.

The natural history of this disease is subject to debate, while there is generally a spontaneous resolution with an improved clinical presentation, many patients remain with some limitation or residual pain, although most of them are satisfied.[5]

Initially, the treatment of choice is nonsurgical. The preferred treatment is physical therapy associated with home exercises. Serial suprascapular nerve blocks and manipulation under sedation are additional options. The surgical option is reserved for cases that are not resolved by these treatments. Either an open or arthroscopic surgical approach can be utilized.[6]

The aim of this study was to describe the outcome of adhesive capsulitis patients that were refractory to conservative treatment and were submitted to arthroscopic surgical treatment.

Material and methods

This prospective study followed 10 cases of adhesive capsulitis of the shoulder who underwent videoarthroscopic surgery at the Shoulder and Elbow Surgical Center of the Instituto Nacional de Traumatologia e Ortopedia between January and September 2009 (Table 1). All patients had constant pain with a prolonged evolution (mean 23.4 months) that was accompanied by shoulder movement limitation and impairment in activities of daily living. On physical examination, there were passive and active limitations in the shoulder range of motion at all planes. Shoulder radiography showed no anatomical alterations that could justify the symptoms. In addition, ultrasonography was performed for all cases and complete rotator cuff tendon injuries were excluded. In all patients, conservative treatment with physical therapy was initially performed for a period of at least six months without success.

Five patients were females and four were males (one case with bilateral involvement), with a mean age of 51 years (27-63).The left side was affected in seven patients, and the predominant side was affected in 40% of cases.

According to the classification of Zuckerman et al.[7], four cases were classified as primary adhesive capsulitis and six as secondary. Of the cases with secondary disease, three had history of diabetes mellitus, one of which used insulin, one patient had undergone arthroscopic repair of rotator cuff two months before symptom onset and the patient with bilateral disease used GardenalR for the treatment of epilepsy.

Prior to operation, the time in which pain and range of motion limitation were experienced ranged from six to 36 months. The mean shoulder range of motion, measured by goniometer at the initial physical examination, was an anterior flexion of the 89º, a lateral rotation of 13º and a medial rotation at the level of the fifth lumbar vertebra. In the postoperative period, after hospital discharge, all patients were instructed to perform anterior elevation and passive lateral rotation exercises according to their tolerance; seven days after the surgical procedure, they started rehabilitation with a physical therapist at the outpatient clinic.

The University of California Los Angeles (UCLA) shoulder scoring system was used together with the Constant score to assess the outcomes at the end of the treatment.

The postoperative range of motion (ROM) gain was evaluated after one week and six months.

The statistical analysis was performed using the Sigma Stat software, release 3.2. To evaluate the increase in the range of motion and the scoring criteria, the normality

Table 1 - Patients with Adhesive Capsulitis.

	Age (years)	Δt (m)	Side	Comorbidity	Physical therapy*
1	59	36	L	DM	25
2	53	27	L	No	> 100
3	63	38	L	DM	> 50
4	55	25	L	Epilepsy	> 50
5	55	10	R	Epilepsy	> 50
6	45	26	L	No	> 100
7	27	18	L	No	> 100
8	52	6	L	Depression	> 50
9	47	25	R	DM	> 50
10	54	23	R	No	> 50

Δt: time in months between symptom onset and surgery; R: Right, L: left. Numbers four and five represent the same patient who had bilateral involvement. * Number of sessions.

and equality of the distribution was tested, a Student's t test or one-way ANOVA was performed and a Spearman's correlation with 95% confidence interval ($p < 0.05$) was calculated.

Surgical Technique

All of the videoarthroscopic procedures were performed by the same surgeon. For all cases, a combination of general anesthesia with brachial plexus blockade was utilized. The surgeries were performed with the patient in the beach chair position. ROM was measured on the anesthetized patients immediately before starting the procedure. The optical device was introduced through the posterior portal to perform an intra-articular assessment of the intrinsic shoulder lesions and to establish the anterior portal using the outside-in technique, where the radiofrequency tip was introduced to open the rotator interval and release the medium glenohumeral and coracohumeral ligaments.

All tissue in this area was excised until the infero-lateral bone surface of the coracoid could be visualized. Then, using basket forceps through the anterior portal, an anterior capsulotomy was performed until the border of the anterior-inferior glenoid rim and visualization of the subscapularis muscle fibers was attained (Fig. 1A). At this point, visualization through the anterior portal was attained, and a posterior capsulotomy was performed with basket forceps through the posterior portal (Fig. 1B) up to the border of the posterior-inferior glenoid rim. The capsule was removed in both the anterior and posterior portion using a shaver.

After this step, the arthroscopy was interrupted and, through manipulation with anterior total passive flexion, the surgeon achieved tactile sensation of the lower capsulotomy, which was later confirmed when the surgeon returned to intra-articular visualization (Figs. 1C and 1D). This method was chosen due to the decreased risk of an axillary nerve lesion. If the symptoms were related to the long head of the biceps tendon (LHBT) and its structural alterations, tenotomy was performed with or without tenodesis. The procedure was completed with subacromial debridement. All patients used a simple arm sling for analgesia for the first days post-operation.

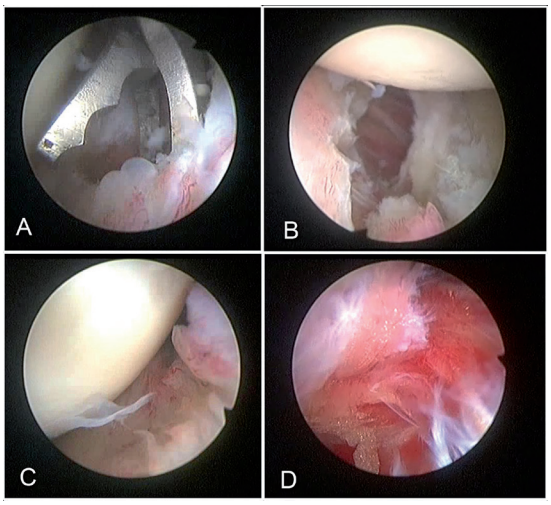

Fig. 1 - Arthroscopic images: (A) anterior capsulotomy using basket forceps, (B) posterior capsulotomy, (C) obliteration of the axillary recess and (D) axillary recess after manipulation.

Results

There was an increase in the UCLA score from 9.8 preoperatively (6-14) to 31.6 postoperatively (26-35) ($p < 0.01$) (Fig. 2) and an increase in the Constant score from 20 (13-27) to 79.2 (66-91) postoperatively ($p < 0.01$) (Fig. 3). In the preoperative period, the mean passive joint mobility values were as follows: 89º of anterior flexion (80º to 100º), 12.5º of lateral rotation (0º-30º) and L5 of medial rotation (T12-gluteal); in the postoperative period, the mean passive joint mobility values increased significantly to 150º/46º/T11 and 153º/56º/T9 after one week and six months, respectively (Figs. 4 and 5).

Regarding the variations in the range of motion between the first week and the sixth month postoperative, four cases had increased ROM, four had no alteration and only two had a reduction in anterior flexion. Regarding lateral rotation, six had increased ROM, three maintained the increase achieved in the first week and one showed regression. All cases showed internal rotation improvement (Table 2). However, the increase in the mean range of motion between the follow-up at one week and at sixth months was not statistically significant.

Two patients showed a partial joint tear of less than 30% of the supraspinatus tendon, and debridement was performed in these cases. Acromioplasty was necessary in two cases with coracoacromial ligament release due to the presence of symptoms and arthroscopic signs of subacromial impingement. In patients submitted to previous surgeries, resection of the distal clavicle and tenotomy of the long head of the biceps was performed in addition to capsulotomy (Table 3).

After six months of follow-up, seven patients considered their results as excellent, two as good and one as reasonable; none regarded the results as bad (Fig. 6).

All patients achieved pain reduction, and only two remained with mild and intermittent pain. In one case, inferior capsulotomy was not performed by passive. One patient developed symptoms of painful shoulder subluxation, which improved after six months of follow-up with muscle-strengthening exercises.

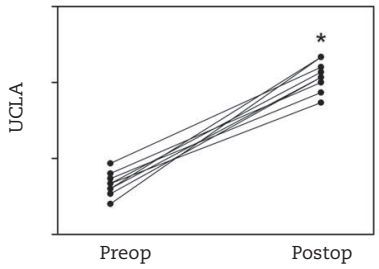

Fig. 2 - Pre- and postoperative UCLA score in each one of the 10 cases; *indicates a significant difference from preop ($p < 0.01$).

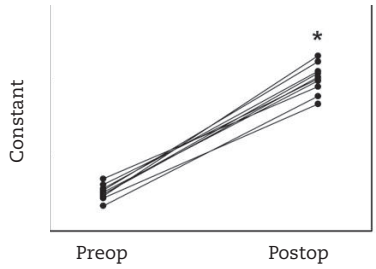

Fig. 3 - Pre- and postoperative Constant score in each of the 10 cases; *indicates a significant difference from preop (p < 0.01).

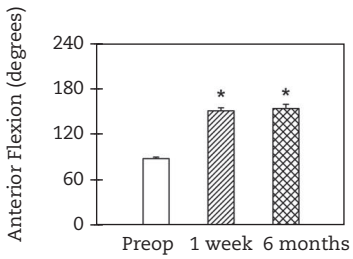

Fig. 4 - Bars represent the mean + standard error of the anterior flexion preoperatively, after one week and after six months postoperatively; *indicates a significant difference from preop (p < 0.05).

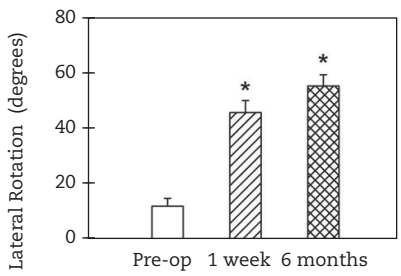

Fig. 5 - Bars represent the mean + standard error of the lateral rotation preoperatively, after one week and after six months postoperatively; *indicates a significant difference from preop (p < 0.05).

Fig. 6 - Range of movement (ROM) after one week postop; preop ROM = 90°/10°/L5.

Table 2 – Pre- and postoperative passive range of movement.

	Pre-op			1 week			6 months		
	AF	LR	MR	AF	LR	MR	AF	LR	MR
1	100	30	L5	150	50	T12	170	70	T8
2	100	10	T12	145	35	L2	160	65	T7
3	90	10	Gluteus	130	20	L3	110	30	L1
4	90	-5	Gluteus	150	60	T12	170	70	T7
5	80	20	Gluteus	130	30	T12	150	45	T12
6	80	20	Gluteus	165	65	L1	140	50	T9
7	80	10	Gluteus	160	45	T11	160	70	T8
8	90	10	Gluteus	150	50	T12	150	50	T8
9	90	10	L5	165	60	T10	165	60	T9
10	90	10	L5	160	50	T11	160	50	T9

AF: anterior flexion; LR: lateral rotation; MR: medial rotation.

Table 3 - Arthroscopic surgery for adhesive capsulitis.

	Rotator cuff injury	Acromioplasty	Tenotomy Biceps
1	No	No	No
2	No	No	No
3	< 30%*	Yes	No
4	No	No	No
5	No	No	No
6	No	Yes	No
7	No	No	Yes
8	< 30%*	Yes	No
9	No	No	No
10	No	No	No

* Partial articular injury < 30% of supraspinal tendon. Ant.: anterior; Post: posterior.

Discussion

Adhesive capsulitis (AC) is a disease that manifests as shoulder pain and stiffness, usually of a long duration; AC may have a high socioeconomic impact as many patients are unable to perform their professional activities for long periods of time.

Described by Duplay[8] in the XIX century, AC remains a common and frustrating problem in orthopedic practice. Although studies are still being conducted, the mechanism

behind the development of AC has not been completely elucidated.[9,10] Nonsurgical methods are the initial treatment of choice and include physical therapy combined with home exercises and drug therapy. In consideration of the known phases of the disease, the treatment should be gradual and progressive, as there is a natural evolution toward spontaneous resolution in most cases. Spontaneous resolution of AC may take over a year, and some degree of limitation or stiffness often remains.[5,11] In cases that are refractory to physical therapy, a suprascapular nerve block is a treatment option; Checchia et al.[12] showed good treatment outcomes with this technique.

Once surgical treatment is indicated, it can be performed by either open or arthroscopic techniques. Currently, arthroscopic surgery is the procedure of choice, as it is less aggressive and has less potential to promote the formation of new scar adhesions. Moreover, this technique also allows extensive capsulotomy without damage to the rotator cuff, in addition to allowing the treatment of shoulder-related lesions.[13-15]

From the anatomopathological point of view, the most remarkable feature of this disease is the scar deposition process in the capsule that primarily affects the rotator interval,[16] including the superior glenohumeral and coracohumeral ligaments.[17] In all of our cases, it was observed that after release of the rotator interval, considerable gain was obtained in lateral rotation. However, we believe that a global capsular release (anterior, inferior and posterior) is necessary to restore the shoulder range of motion in all planes. Berghs et al.[18] had 21 cases with excellent or good outcomes, with an increase in the Constant score from 25.3 to 75.5 after arthroscopic surgery, out of 25 patients with primary adhesive capsulitis.

The inferior capsulotomy was also performed by passive elevation after anterior and posterior capsular release. In this article, the statistical analysis to evaluate the gain in ROM was made at only one time-point, with a mean follow-up of 14.8 months. Our analysis was obtained after one week and six months postoperatively to assess whether there was significant increase or reduction at follow-up.

In our study, the greatest surgical treatment benefit was obtained in the first week, when the range of motion increased significantly. No statistically significant difference was found between the ROM at one week and the ROM at six months post-surgery. While the lack of a control group in our study does not allow for statistical comparisons, the postoperative follow-up with physical therapy appeared to be important for the maintenance of the ROM achieved with arthroscopic surgery. Two cases showed a decrease in passive flexion between the one-week and six-month evaluations; nevertheless, passive flexion remained higher than the preoperative status.

In one case, inferior capsulotomy was not achieved using the manipulation technique with passive elevation. In this case, we chose not to perform inferior capsulotomy with a scalpel due to the risk of a neurologic lesion. We believe that the surgery was successful in this patient due to the large and rapid infiltration of the saline solution into the soft tissues after the opening of the rotator interval and the anterior and posterior capsular opening. Although this patient showed improvement in both range of motion and the scoring criteria of the Constant and UCLA scores, his results were worse than those of other patients.

Conclusion

Surgical treatment for adhesive capsulitis by arthroscopy was effective, with a significant range of motion increase in all planes, pain relief and low rate of complications.

Conflict of interests

The authors declare no conflict of interests related to this manuscript.

REFERENCES

1. Manske RC, Prohaska D. Diagnosis and management of adhesive capsulitis. Curr Rev Musculoskelet Med. 2008;1(3-4):180-9.
2. Placzek DJ, Roubal JP, Freeman DC, Kulig K, Nasser S, Pagett BT. Long term effectiveness of translational manipulation for adhesive capsulitis. Clin Orthop Relat Res. 1998;(356):181-91.
3. Codman EA. The shoulder: rupture of the supraspinatus tendon and other lesions in or about the subacromial bursa. Boston: Thomas Todd Company; 1934.
4. Neviaser JS. Adhesive capsulitis of the shoulder. J Bone Joint Surg Am. 1945;27:211-22.
5. Schaffer B, Tibone JE, Kerlan RK. Frozen shoulder: a long term follow-up. J Bone Joint Surg Am. 1992;74(5):738-56.
6. Godinho GG, Sampaio TC. Capsulite adesiva: tratamento conservador. In: Pardini AG, Souza G, Godinho GG. Clin Ortop (Rio de Janeiro). 2000;1(1):197-202.
7. Zuckerman JD, Cuomo F, Rokito S. Definition and classification of frozen shoulder: a consensus approach. J Shoulder Elbow Surg. 1994;3(1):S72.
8. Duplay S. De la peri-arthrite scapulo-humerale et des raideurs de l'epaule qui en sont la consequence. Arch Gen Med. 1872;20:513-4.
9. Grey RG. The natural history of "idiopathic" frozen shoulder. J Bone Joint Surg Am. 1978;60(4):564.
10. Reeves B. The natural history of the frozen shoulder syndrome. Scand J Rheumatol. 1975;4(4):193-6.
11. Zuckerman DJ, Cuomo F. Frozen shoulder. In: Matsen FA, Fu FH, Hawkins RT, editors. The shoulder: a balance of mobility and stability. Rosemont: AAOS; 1993. p. 253-6.
12. Checchia LS, Fregoneze M, Miyazaki AN, Santos PD, Da Silva LA, Ossada A et al. Tratamento da capsulite adesiva com bloqueios seriados do nervo supraescapular. Rev Bras Ortop. 2006;41(7):245-52.
13. Ogilvie-Harris DJ, Biggs DJ, Fitsialos DP, MacKay M. The resistant frozen shoulder: manipulation versus arthroscopic release. Clin Orthop Relat Res. 1995;(319):238-48.
14. Lynch SA. Surgical and nonsurgical treatment of adhesive capsulitis. Curr Opin Orthop. 2002;13:271-4.
15. Yamaguchi K, Navinder S, Bauer SB. Postoperative pain control following arthroscopic release of adhesive capsulitis: a short-term retrospective review study of the use of an intra-articular pain catheter. Arthroscopy. 2002;18(4):359-65.

16. Ozaki J, Nakagawa Y, Sakurai G, Tamai S. Recalcitrant chronic adhesive capsulitis of the shoulder. Role of contracture of the coracohumeral ligament and rotator interval in pathogenesis and treatment. J Bone Joint Surg Am. 1989;71(10):1511-5.
17. Neer CS 2nd, Satterlee CC, Dasley RM, Flatow EL. The anatomy and potencial effects of contracture of the coracohumeral ligament. Clin Orthop 1992;(280):182-5.
18. Berghs BM, Sole-Molins X, Bunker TD. Arthroscopic release of adhesive capsulitis. J Shoulder Elbow Surg. 2004;13(2):180-5.