Original Article

Unilateral spacer distraction of the subaxial cervical facet joint for the treatment of fixed coronal malalignment of the craniovertebral junction

ABSTRACT

Introduction: The standard treatment for a fixed coronal malalignment of the craniovertebral junction is an anterior and/or posterior column osteotomy (PCO) plus instrumentation. However, the procedure is very challenging, carrying an inherently high risk of complications even in experienced hands. This case series demonstrates the usefulness of an alternative treatment that adds a unilateral spacer distraction (USD) to the subaxial cervical facet joint to promote coronal realignment and fusion.

Materials and Methods: A single-center retrospective study of the patients with fixed coronal malalignment of the craniovertebral junction caused by different etiologies treated with USD in the concavity side with PCO in the convexity side of the subaxial cervical spine. Demographic characteristics and radiological parameters were collected with special emphasis on clinical and radiological measurements of coronal alignment of the cervical spine.

Results: From 2012 to 2019, four patients were treated with USD of the subaxial cervical spine complementing an asymmetrical PCO at the same level. The causes of coronal imbalance were congenital, tuberculosis, posttraumatic, and ankylosing spondylitis. The level of USD was C2–C3 in three patients and C3–C4 in one patient. A substantial coronal realignment was achieved in all four. One patient had an iatrogenic vertebral artery injury during the dissection and facet distraction and developed Wallenberg's syndrome with partial recovery.

Conclusions: USD of the concave side with unilateral PCO of the convexity side in the subaxial cervical spine is a promising alternative treatment for fixed coronal malalignment of the craniovertebral junction from different causes.

Keywords: Coronal alignment, craniovertebral junction, facet distraction, spacer, subaxial cervical spine

INTRODUCTION

Atlantoaxial facet joint distraction with the impaction of a titanium cage achieving reduction was first described as a novel treatment for atlantoaxial dislocation with basilar invagination by Goel[1] in 2007, following his 2005 report of the introduction of the same technique in cases of rheumatoid disease and lateral mass collapse. This technique allows complete indirect decompression of the spinal cord through reduction by a posterior-only approach. It is gaining growing acceptance in the spine community for selected cases and is demonstrating good outcomes.

Application of the same line of treatment in the setting of subaxial cervical foraminal stenosis has been described, using a bilateral spacer placed in the facet joint achieving an indirect decompression of the nerve roots without significant loss of cervical lordosis[2] and using a unilateral spacer in the atlantoaxial facet joint in conjunction with posterior

Access this article online	
Website: www.jcvjs.com	**Quick Response Code**
DOI: 10.4103/jcvjs.jcvjs_9_22	

Luis E. Carelli[1], Alderico Girão[1], Ígor Cechin[1], Juan P. Cabrera[1,2]

[1]Center of Spine Diseases, Department of Orthopedics and Traumatology, National Institute of Traumatology and Orthopedics, Rio de Janeiro, Brazil, [2]Department of Neurosurgery, Faculty of Medicine, University of Concepción, Concepción, Chile

Address for correspondence: Dr. Juan P. Cabrera, San Martín 1436, Concepción, Chile.
E-mail: jucabrera@udec.cl

Submitted: 13-Jan-22 **Accepted:** 08-May-22
Published: 13-Jun-22

This is an open access journal, and articles are distributed under the terms of the Creative Commons Attribution-NonCommercial-ShareAlike 4.0 License, which allows others to remix, tweak, and build upon the work non-commercially, as long as appropriate credit is given and the new creations are licensed under the identical terms.

For reprints contact: WKHLRPMedknow_reprints@wolterskluwer.com

How to cite this article: Carelli LE, Girão A, Cechin Í, Cabrera JP. Unilateral spacer distraction of the subaxial cervical facet joint for the treatment of fixed coronal malalignment of the craniovertebral junction. J Craniovert Jun Spine 2022;13:121-6.

column osteotomy (PCO) for coronal malalignment of the craniovertebral junction.[3] For the restoration of coronal balance for fixed diseases affecting the craniovertebral junction, the standard treatment remains PCO with anterior release when necessary plus instrumentation.[4]

A single-level PCO of the convexity side in addition to a unilateral spacer distraction (USD) in the concavity side of the subaxial cervical spine for the treatment of fixed coronal deformity and fixed ankylosis at the craniovertebral junction to achieve realignment and promote fusion[5] was first reported for the treatment of type 3 craniovertebral junction osteoarthrosis.[3] This report describes the surgical technique of USD in the subaxial cervical spine and the clinical outcomes of a small series of cases covering the first 7 years of our experience.

MATERIALS AND METHODS

Study design

This single-center retrospective study was conducted in accordance with ethical standards and was approved by ethics committee (IRB number: 21225019.0.0000.5273).

Data collection

Patients were those who underwent posterior-only subaxial cervical instrumentation from 2012 to 2019 due to coronal imbalance of the cervical spine caused by a fixed deformity of the craniovertebral junction. Demographic variables, etiology, level of treatment, neurological status, and postoperative complications were obtained from the medical records. Preoperative and postoperative frontal photographs were retrieved, as were X-rays and computer technology (CT) scans, when available, for radiological measurements.

Surgical technique

The patient is placed at 30° in a floating head positioning method with transcranial traction, and a conventional posterior approach to the cervical or cervicothoracic spine through a midline incision is performed with instrumentation of the involved levels according to the standard technique. In the upper subaxial cervical spine, a single-level PCO type 2 of the convexity side is performed.[4] The concavity side of the same level was osteotomized, the facet joint exposed and progressively dissected until the venous plexus surrounding the vertebral artery, the cartilaginous tissue removed with curettes of the facet surfaces, and a spacer filled with autologous bone graft was placed, avoiding overdistraction.

Clinical and radiological assessments of coronal alignment

To assess preoperative coronal alignment and then evaluate the postoperative improvement, several clinical and radiological parameters were measured.

For clinical assessment, preoperative and postoperative anterior–posterior photographs were used to measure two angles:

- Inter-pupilar angle: it is the angle made by a line between both pupils and a horizontal line
- Fronto-nasion-mentonian angle:[6] then angle is made by a line in the midline of the face and a vertical line.

For radiological assessment, the best coronal X-ray or CT scan image was used to measure three angles:

- Bimastoid angle: the angle made by a line connecting the tips of both mastoid processes and the horizontal line
- Digastric angle (DGA): the angle between both digastric sulci and the horizontal line
- Segmental angle (SA): the angle between the superior and inferior plates of the cranial and caudal vertebras involved in the USD, respectively.

RESULTS

There were four cases with fixed coronal malalignment in the craniovertebral junction [Figure 1] in whom the USD complementing an asymmetrical PCO was the treatment of choice. Three males and one female, ranging in age from

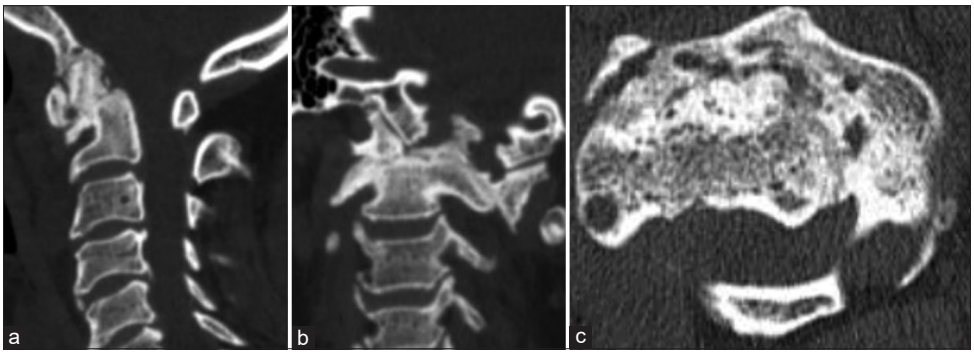

Figure 1: Preoperative CT scan in (a) sagittal (b) coronal and (c) axial view demonstrating a craniovertebral posttraumatic deformity with fixed malalignment. CT: Computer technology

10 to 67 years, all had normal neurological examinations. Table 1 summarizes clinical characteristics, type of graft used (autologous vs. allograft), and complications.

The USD was performed in the subaxial cervical spine at the C2–C3 level in three patients and at the C3–C4 level in one patient, using a Harms spacer filled with autologous bone graft in three patients and with structural allograft in one patient [Figures 2-5]. One patient (#4) had surgical complications stemming from iatrogenic vertebral artery injury: Wallenberg's syndrome from which there was partial recovery following rehabilitative therapy. Patient 3 had postoperative pneumonia and required a temporary gastrostomy for nutritional optimization until deglutition movements recovered.

The preoperative and postoperative clinical and radiological measurements used to describe each patient's coronal alignment are presented in Table 2. Patient 3 had the greatest improvement in coronal balance [Figure 6], but it was not possible to measure the DGA due to his severe "ear-on-shoulder" deformity,[7] which obscures the necessary anatomical landmarks. Using the three radiological measurements – the bimastoid, digastric, and SAs – from patient 1, one can appreciate the improvement in coronal balance [Figure 7].

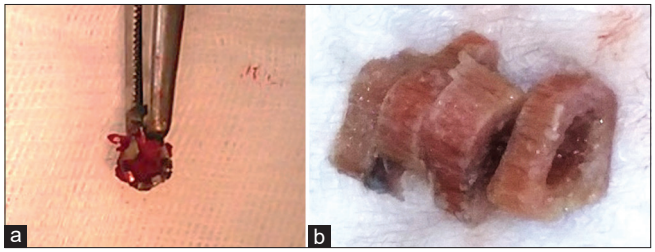

Figure 2: Spacer employed in these case series of USD with (a) Harms spacer filled with autologous bone graft and (b) structural allograft of the fibula. USD: Unilateral spacer distraction

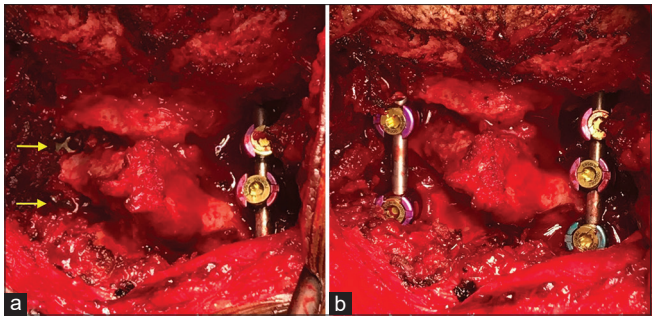

Figure 4: Intraoperative image of (a) USD placed in C1–C2 and C2–C3 (arrows) on the left side and (b) final construct with screws and rods. USD: Unilateral spacer distraction

DISCUSSION

Multiple diseases of the craniovertebral junction lead to cervical malalignment that negatively affects the quality of life.[8] One of the goals of the cervical deformity correction

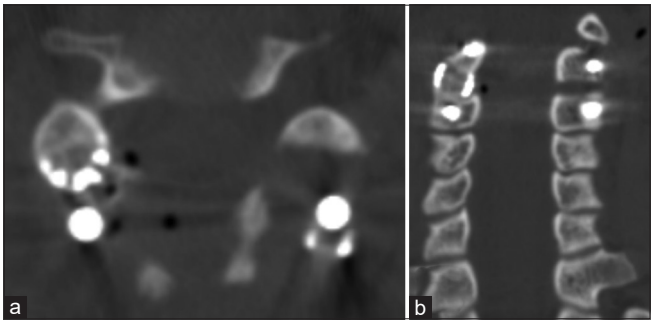

Figure 3: Postoperative CT scan showing a right-sided C2–C3 USD in (a) axial and (b) coronal view promoting realignment and facetal joint fusion. CT: Computer technology

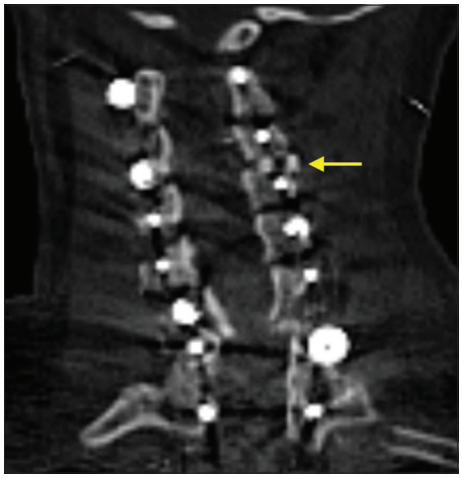

Figure 5: Postoperative coronal CT scan showing a left-sided C3–C4 USD placed in the facet joint using a structural allograft (arrow). CT: Computer technology, USD: Unilateral spacer distraction

Table 1: Demographic and clinical characteristics of the case series

Patient	Age	Gender	Diagnosis	Neurological status	Level of USD	Side of USD*	Type of spacer	Additional osteotomy	Postoperative complication
1	10	Male	Congenital	Normal	C2–C3	Right	Harms	PCO-CS	-
2	51	Female	Tuberculosis	Normal	C2–C3	Right	Harms	PCO-CS	-
3	42	Male	Ankylosing spondylitis	Normal	C3–C4	Left	Allograft	PCO-CS + PCO C4-5-6-7 PSO T2	Medical complications
4	67	Male	Posttraumatic	Normal	C2–C3	Left	Harms	PCO-CS + USD C1-2	VA injury

*Concavity side. VA – Vertebral artery; USD – Unilateral spacer distraction; PCO – Posterior column osteotomy; PCO-CS – PCO of the convexity at level of USD; PSO – Pedicle subtraction osteotomy

Figure 6: Frontal view of (a) preoperative and (b) postoperative photograph with clinical measurements of cervical coronal alignment

Table 2: Preoperative and postoperative radiological measurements of coronal alignment

Patient	Time	FNMA (°)	IPA (°)	BMA (°)	DGA (°)	SA (°)
1	Preoperative	5.0	11.1	9.9	10.2	0.6
	Postoperative	3.8	10.0	2.2	5.8	7.5
2	Preoperative	14.8	13.4	19.6	19.9	8.8
	Postoperative	5.6	6.3	6.6	12.3	10.7
3	Preoperative	90.1	61.6	51.2	-	2.0
	Postoperative	16.7	16.7	20.5	-	5.1
4	Preoperative	5.6	8.0	15.6	12.3	0.8
	Postoperative	4.0	4.2	9.9	11.3	4.0

FNMA – Fronto-nasio-mentonian angle; IPA – Inter-pupilar angle; BMA – Bi-mastoidal angle; DGA - Digastric angle; SA – Segmental angle

is the recovery of the horizontal gaze,[7] and it is majorly analyzed in the sagittal plane in the craniovertebral and cervical localizations. The conventional treatment for these diseases when the patient's neck is rigid and coronally imbalanced includes osteotomies allowing reduction, realignment, and indirect and/or direct decompression. However, even for experienced spine surgeons, these surgical procedures are extremely challenging. This is especially true in congenital disorders; the abnormal anatomy frequently increases the intraoperative time, blood loss, complications, and the length of hospitalization.[9]

Goel and Shah describe the subaxial facetal distraction for the treatment of single and multilevel spondylotic myelopathy and radiculopathy.[10] Texeira da Silva *et al*.[3] developed a novel classification system for craniovertebral junction osteoarthrosis, describing five types of clinical scenarios. Type 3 is craniovertebral junction osteoarthritis with coronal deformity with fixed ankylosis, for which they recommend subaxial facetal distraction of the concavity side in addition to a Grade 2 PCO of the convexity side as described by Christopher Ames.[4] We describe the USD surgical technique

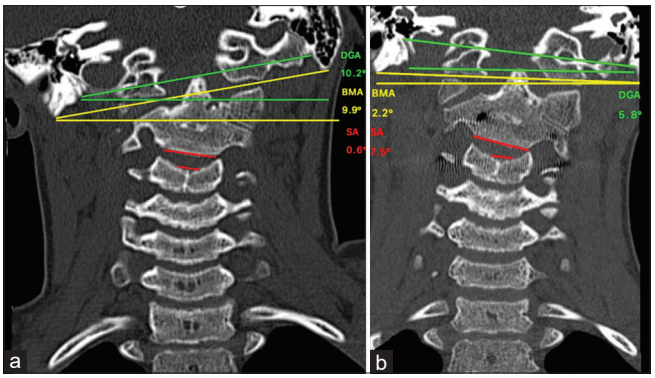

Figure 7: Coronal CT scan comparing (a) preoperative with (b) postoperative radiological measurements of coronal alignment. CT: Computer technology

and illustrate its efficacy in a small case series involving different etiologies by comparing pre-and postoperative clinical and radiological parameters.

Rigid coronal imbalance of the thoracolumbar spine has been resolved by performing an asymmetrical PCO allowing realignment,[11] and this surgical methodology has been successfully extended to the cervical spine.[12] However, even with an excellent postoperative radiological result, the possibility of failure of the instrumentation and pseudarthrosis exist with a potential loss of correction, often necessitating reoperation. Therefore, in the context of diseases with stiffness and coronal imbalance of the craniovertebral junction, a facet joint spacer in addition to the PCO in an otherwise healthy cervical spine level below the ankylosis, could avoid complications, increase the spinal support, and accelerate the rate of fusion.[5]

The cervical facet joint spacer has been tested biomechanically in cadaveric studies, demonstrating good results in maintaining the stiffness properties during flexion-extension, lateral bending, and axial rotation while the foramen area is increased.[13] In addition, a recent cadaveric study has compared the range of motion of circumferential constructs using facet cages, and they were not significantly different from the gold standard anterior graft with a plate.[14] A comprehensive analysis of each case in which USD is contemplated must be undertaken so the surgery can be carefully planned with implants tailored and graft material appropriate for the dimensions and orientation of the facet joints in the subaxial cervical spine.[15]

A common concern is how the facetal spacer in the subaxial cervical spine will affect cervical lordosis. With a proper sagittal alignment assessment, due to distraction of the facet joint, an anterior compression of the intervertebral disc is expected. However, even after bilaterally using multilevel spacers at as many as six treated levels, Tan *et al*. did not find

a significant impact on loss of cervical lordosis.[2] This was consistent with a prior report by McCormack *et al*. of cases of single-level radiculopathy treated with the percutaneous DTRAX Facet System, which found no change in the overall cervical lordosis and a 1.6° loss of segmental lordosis at the treated level.[16]

Regarding complications, in conventional cervical spine surgery, the risk of vertebral artery injury with potentially fatal consequences exists, but the rate is low.[17] In deformity correction, the risk of arterial injury during the surgical treatment by the anterior, posterior, or combined approaches is increased.[18-21] This is compounded by the challenges posed by the tortuous course the vertebral artery may take due to abnormalities or variants to the normal anatomy associated with diseases and disorders of the craniovertebral junction.[22] Therefore, a preoperative angiogram is essential to have a meticulous understanding of the vascular anatomy of each patient. Indeed, some authors use intraoperative navigation for vertebral artery localization.[23] USD carries an inherent risk of iatrogenic vertebral artery injury occurring during the bone resection to the venous plexus surrounding the vertebral artery or arterial dissection by an overdistraction. A gentle and progressive distraction maneuver as well as a thorough appreciation of the facetal angles and dimensions[15] for dissection and USD insertion, are essential.

This study has limitations that need to be recognized. First, it is a small case series at a single reference institute; the fixed coronal imbalance caused by the craniovertebral junction pathology is not frequently seen. Second, this is not a comparative study with a control group using the gold standard technique that includes atlantoaxial anterior release and posterior C1–C2 instrumentation or C1–C2 posterior-only approach. That would require a multicenter study involving a large number of institutions, something this report might stimulate. Third, the heterogeneity of the treated diseases implies different osteological capabilities with regard to bone quality and amount of bone healing determining the coronal imbalance. Fourth, the spacers used were different, with distinct biological properties specific to each case, chosen to promote fusion. Furthermore, the bone mineral density of the spacer was not assessed to minimize spacer subsidence in the facet joint, with the consequent loss of correction. Our analysis was a chart review. Future prospective studies can learn from and build on our case series.

CONCLUSIONS

USD of the concavity side with PCO of the convexity side in the subaxial cervical spine is an alternative treatment for fixed coronal malalignment of the craniovertebral junction from different causes. This methodology allows the achievement of coronal and/or sagittal correction by a posterior-only approach, which can decrease the associated morbidity of an osteotomy in a challenging location. The disability that can result from vertebral artery injury must be considered when weighing the benefits and risks. Preoperative or intraoperative vascular imaging should inform the meticulous surgical technique needed to avoid this complication. Given the rarity of this particular pathology, the organization of multicenter investigations of the use of USD with PCO is needed.

Financial support and sponsorship

Nil.

Conflicts of interest

There are no conflicts of interest.

REFERENCES

1. Goel A. Atlantoaxial joint jamming as a treatment for atlantoaxial dislocation: A preliminary report. Technical note. J Neurosurg Spine 2007;7:90-4.
2. Tan LA, Straus DC, Traynelis VC. Cervical interfacet spacers and maintenance of cervical lordosis. J Neurosurg Spine 2015;22:466-9.
3. Texeira da Silva LE, Khan AA, Campos de Barros AG, Krywinski FM, Cabral de Araujo Fagundes FA, de Souza E Silva FG. A novel classification and algorithmic-based management of craniovertebral junction osteoarthrosis. J Craniovertebr Junction Spine 2020;11:321-30.
4. Ames CP, Smith JS, Scheer JK, Shaffrey CI, Lafage V, Deviren V, *et al.* A standardized nomenclature for cervical spine soft-tissue release and osteotomy for deformity correction: Clinical article. J Neurosurg Spine 2013;19:269-78.
5. Cofano F, Sciarrone GJ, Pecoraro MF, Marengo N, Ajello M, Penner F, *et al.* Cervical interfacet spacers to promote indirect decompression and enhance fusion in degenerative spine: A review. World Neurosurg 2019;126:447-52.
6. Goel A, Shah A. Atlantoaxial facet locking: Treatment by facet manipulation and fixation. Experience in 14 cases: Technical note. J Neurosurg Spine 2011;14:3-9.
7. Tan LA, Riew KD. Anterior cervical osteotomy: Operative technique. Eur Spine J 2018;27:39-47.
8. Vedantam A, Hansen D, Briceño V, Brayton A, Jea A. Patient-reported outcomes of occipitocervical and atlantoaxial fusions in children. J Neurosurg Pediatr 2017;19:85-90.
9. Xu R, Xia Y, Passias PG, Protopsaltis T, Sciubba DM. Occipitocervical osteotomies and interfacet grafts for reduction of occipitocervical kyphosis and basilar invagination. World Neurosurg 2019;127:391-6.
10. Goel A, Shah A. Facetal distraction as treatment for single- and multilevel cervical spondylotic radiculopathy and myelopathy: A preliminary report – Technical note. J Neurosurg Spine 2011;14:689-96.
11. Chan AK, Lau D, Osorio JA, Yue JK, Berven SH, Burch S, *et al.* Asymmetric pedicle subtraction osteotomy for adult spinal deformity with coronal imbalance: Complications, radiographic and surgical outcomes. Oper Neurosurg (Hagerstown) 2020;18:209-16.
12. Theologis AA, Bellevue KD, Qamirani E, Ames CP, Deviren V. Asymmetric C7 pedicle subtraction osteotomy for correction of rigid cervical coronal imbalance secondary to post-traumatic heterotopic ossification: A case report, description of a novel surgical technique,

and literature review. Eur Spine J 2017;26:141-5.
13. Leasure JM, Buckley J. Biomechanical evaluation of an interfacet joint decompression and stabilization system. J Biomech Eng 2014;136:0710101-0710108. doi:10.1115/1.4026363.
14. Pereira BA, Heller JE, Lehrman JN, Sawa AG, Kelly BP. Biomechanics of circumferential cervical fixation using posterior facet cages: A cadaveric study. Neurospine 2021;18:188-96.
15. Shah A. Morphometric analysis of the cervical facets and the feasibility, safety, and effectiveness of Goel inter-facet spacer distraction technique. J Craniovertebr Junction Spine 2014;5:9-14.
16. McCormack BM, Bundoc RC, Ver MR, Ignacio JM, Berven SH, Eyster EF. Percutaneous posterior cervical fusion with the DTRAX Facet System for single-level radiculopathy: Results in 60 patients. J Neurosurg Spine 2013;18:245-54.
17. Schroeder GD, Hsu WK. Vertebral artery injuries in cervical spine surgery. Surg Neurol Int 2013;4:S362-7.
18. Segar AH, Riccio A, Smith M, Protopsaltis TS. Total uncinectomy of the cervical spine with an osteotome: Technical note and intraoperative video. J Neurosurg Spine 2019;31:831-4.
19. Echt M, Mikhail C, Girdler SJ, Cho SK. Anterior reconstruction techniques for cervical spine deformity. Neurospine 2020;17:534-42.
20. Shah KC, Gadia A, Nagad P, Bhojraj S, Nene A. Buckling collapse of midcervical spine secondary to neurofibromatosis. World Neurosurg 2018;114:228-9.
21. Han K, Lu C, Li J, Xiong GZ, Wang B, Lv GH, *et al.* Surgical treatment of cervical kyphosis. Eur Spine J 2011;20:523-36.
22. Tan LA, Kasliwal MK, Gerard CS, Traynelis VC, Fontes RB. Surgical considerations in posterior C1-2 instrumentation in the presence of vertebral artery anomalies: Case illustration and review of literature. Br J Neurosurg 2019;33:422-4.
23. Kiessling JW, Ramnot A, Odell T, Khan Y, Mahato D. Use of O-arm with intraoperative arteriography for localization and stealth navigation of the vertebral arteries during posterior cervical spine surgery. Int J Spine Surg 2021;14:S10-5.